

Case Report

Conservative treatment of periprosthetic femur fractures around metaphyseal short stems – A feasible option?

K. Toth^a, H. Gality^a, K. Gion^b, K. Sisak^{a,*}

^a Department of Orthopaedics, University of Szeged, Hungary

^b Department of Radiology, University of Szeged, Hungary

ARTICLE INFO

Article history:

Accepted 21 May 2017

Available online 30 May 2017

Keywords:

Periprosthetic femur fracture

Uncemented short stems

Total hip replacement

ABSTRACT

Periprosthetic femoral fractures are rare but significant events following total hip replacement. Metaphyseal short stems have recently been popularized as a bone preserving alternative to conventional uncemented total hip replacement. We present two periprosthetic femur fractures which occurred around two different metaphyseal uncemented stem designs. Successful conservative treatment was possible in both cases achieving bony union and excellent clinical results.

© 2017 Published by Elsevier Ltd. This is an open access article under the CC BY-NC-ND license (<http://creativecommons.org/licenses/by-nc-nd/4.0/>).

Introduction

Most periprosthetic femoral fractures are intraoperative events. These injuries mostly occur during the insertion of the femoral stem or aggressive broaching. Studies have reported various incidence of this unfortunate complication, with uncemented stems having a much higher fracture rate [1,2]. For some uncemented femoral components, conservative treatment is an option for stable Vancouver [3] A and B1 type fractures, depending on the type of stem used and the specifics of the fracture.

Short femoral stems have gained popularity over the last decade, and are increasingly used in the young and active population for the treatment of end stage degenerative conditions of the hip [4]. Studies have investigated their load transfer, migration patterns and biomechanical properties [5,6]. Medium term clinical and radiological results have been encouraging [7]. Periprosthetic fractures around these stems do occur, and usually require revision, due to the nature of the biological fixation of these stems. An attempt to treat these fractures conservatively might hinder revision surgery later, by creating malunion, subsidence and/or loosening.

We present a case where an early postoperative Vancouver B2 type fracture occurred due to adequate trauma around a Proxima® (DePuy, Leeds, UK) short stem. The fracture was treated conservatively despite the fact that the fracture line affected both lesser and greater trochanters. We also present a case where an intraoperative fracture occurred around a Metha® (B. Braun Aesculap, Tuttlingen, Germany) stem, affecting the lateral wall. This fracture was also treated conservatively.

Case 1

A 48 year-old man underwent primary total hip replacement for primary osteoarthritis of the hip. The operation and the immediate postoperative period was uneventful (Fig. 1a), and the patient was discharged after completing physiotherapy on day 4,

* Corresponding author at: Department of Orthopaedics, University of Szeged, 6. Semmelweis Street, Szeged H-6725, Hungary.
E-mail address: sisak.krisztian@med.u-szeged.hu (K. Sisak).

partial weight-bearing on crutches. 3 weeks postoperatively the patient fell and presented to the orthopaedic outpatient department with pain and difficulty ambulating. A radiograph revealed a periprosthetic fracture affecting the calcar and longitudinally splitting the greater trochanter (Fig. 1b). There was evidence on the radiograph of some subsidence of the femoral component, but the tip of the stem looked stable/wedged in and the stem had not shifted into significant varus, therefore was deemed stable. After discussing the options with the patient, conservative treatment with 6 weeks of touch-toe weight-bearing was initiated. The fracture has healed uneventfully (Fig. 1c), and 5 years postoperatively the patient is asymptomatic and has well functioning hip joint with a HHS (Harris Hip Score) of 85 at the last follow-up (preoperative score was 35).

Case 2

A 46 year-old woman underwent a primary total hip replacement for end stage osteoarthritis of the hip secondary to developmental dysplasia of the hip (Fig. 2a). The operation was uneventful. The chosen implant was an uncemented cup and a Metha® stem. The patient was mobilized the next day as per the routine protocol. Our department recommends walking aids and touch-toe weight-bearing for uncemented total hip replacements. A routine postoperative radiograph was taken on day 2, which showed a fracture of the lateral wall of the proximal metaphysis of the femur. The greater and lesser trochanters appeared intact on plain radiographs. The tip of the stem looked well fixed, surrounded by intact diaphyseal cortices. Screening under image intensifier control was performed in the operating theatre to assess stability. The stem looked stable. The patient was treated conservatively and 6 months postoperatively, good consolidation of the fracture can be seen (Fig. 3a and b).

Discussion

Perioperative femoral fractures after uncemented total hip replacement present unique challenges to both the treating surgeon and the patient affected. The patients involved are often young and are involved in high demand activities. Using short stems for this patient population is a very tempting proposition as these implants load the proximal femur more physiologically, thus potentially avoiding thigh pain, and proximal stress-shielding. These stems preserve proximal femoral bone stock and can be inserted in a minimally invasive fashion. Intraoperative femoral fractures have been reported with various metaphyseal stems. The incidence of these events is relatively low, and range from 0.3% to 2.5% [2] and decreases with the operating surgeon's experience.

The fractures that occur around short stems have a different pattern, than those affecting conventional uncemented stems. They are more proximal, represent either a perforation or split during the insertion of the broach or stem, or present because of rotational forces causing postoperative short spiral femoral fractures around the stem. They frequently affect one or both trochanters, creating a challenging situation where conventional osteosynthesis techniques might not be possible. Using wires or cables in the proximal few centimeters of the femur is difficult, and trochanteric plates might require further exposure and soft tissue stripping. Understandable scepticism exists whether any of these fractures can be treated conservatively as short stems have no diaphyseal anchoring and are fixed mechanically and later biologically in the metaphysis of the femur. Interpreting these fractures with the Vancouver classification is difficult as this classification was designed for conventional stems. Some B2 fractures can be considered as B1s as despite some initial movement, as the stems can be wedged in, and there extensive HA (Hydroxy-Apatite) coating might still allow growth and long term stability.

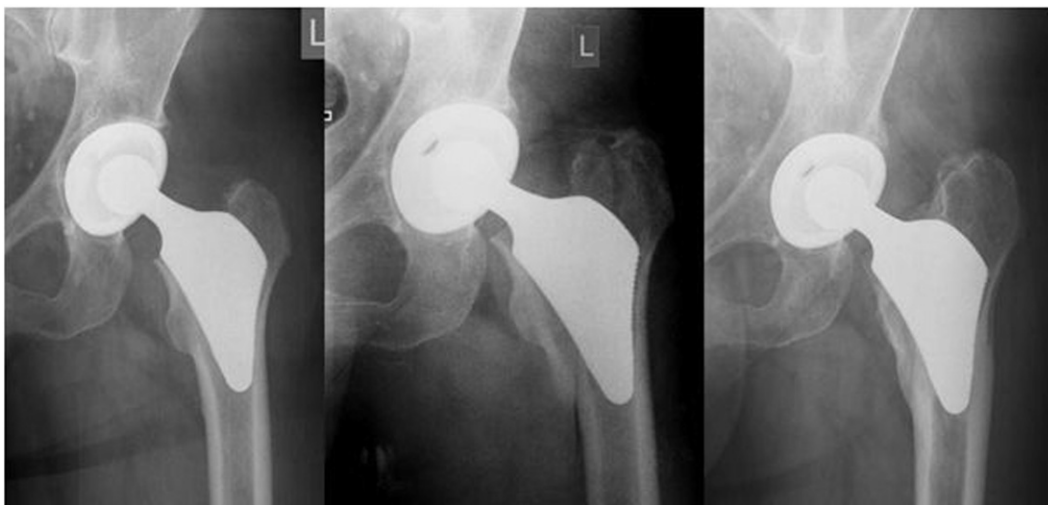


Fig. 1. a: Immediate postoperative radiograph of left hip following uncemented THR using the Proxima short stem in a 48 year old male patient. b: 3 weeks post THR patient had a fall and suffered a what was deemed to be a Vancouver B1 femoral fracture. The fracture was treated conservatively. c: 5.5 years post THR. The hip is asymptomatic with excellent function. The fracture has healed and remodeled.

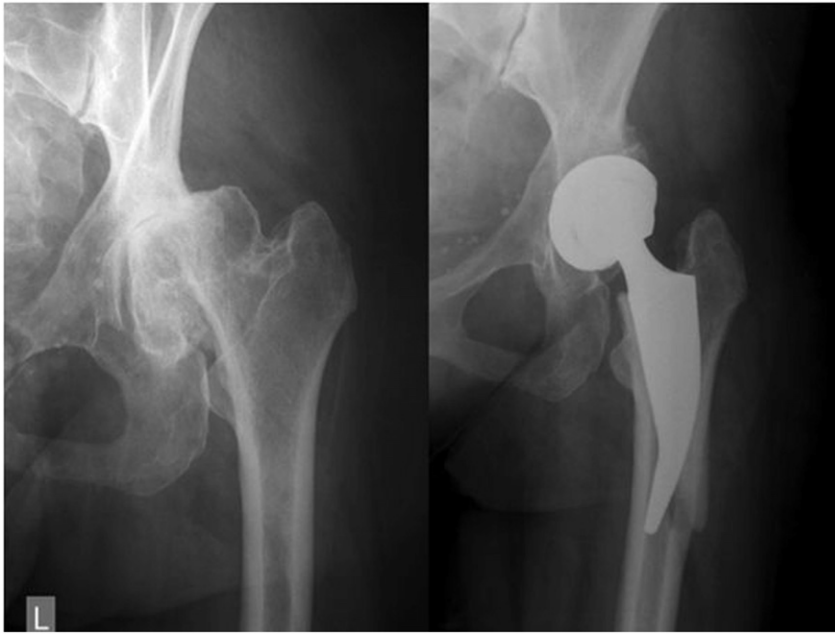


Fig. 2. a: Preoperative radiograph showing left hip end stage osteoarthritis secondary to DDH of a 46 year old woman. b: Postoperative radiograph taken on day 2, showing a lateral flange fracture, but intact calcar, trochanters and distal diaphyseal bone.

We presented two cases with two stem designs where a proximal femoral periprosthetic fracture was treated successfully using conservative measures, without further surgery. We managed to achieve an excellent outcome in these particular cases.

Most publications, which describe results following total hip replacement using short stems mention the odd case of a conservatively treated periprosthetic femoral fracture. Details or radiographs are rarely provided. Non-operative treatment is possible, but only after a detailed analysis of the fracture pattern, and implant position. A CT scan might provide useful if conservative treatment is considered. Patient compliance is of paramount importance.

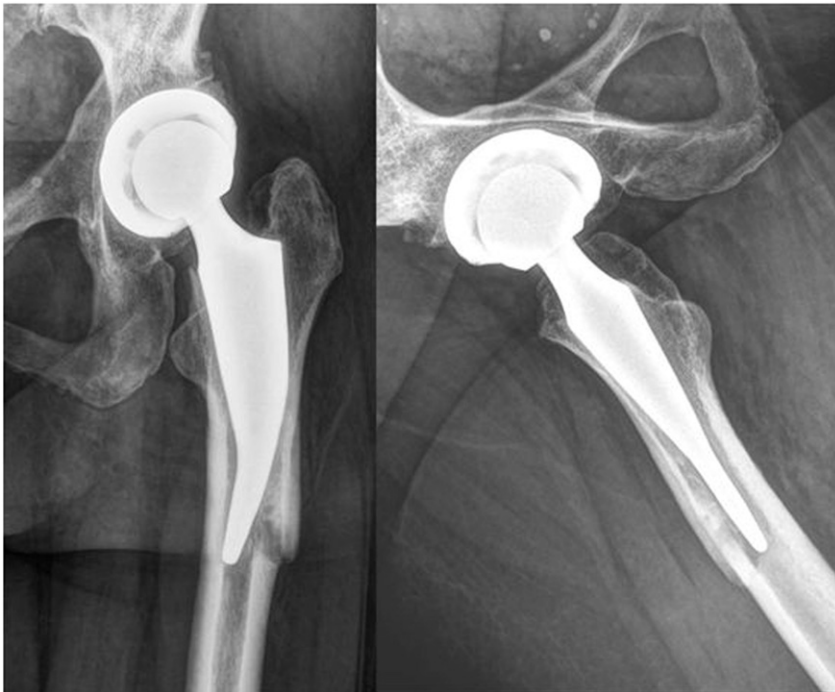

Fig. 3. a: Radiograph taken 6 months postoperatively, showing a consolidated fracture on the AP view without subsidence if compared with postoperative image (Fig. 2b). b: Lateral view 6 months postoperatively showing a well positioned stem.

Conclusion

Periprosthetic femoral fractures around short metaphyseal stems may occur intraoperatively or postoperatively. Successful conservative treatment of these injuries is feasible, but the decision-making regarding treatment should be tailored to the unique characteristics of each fracture and stem. The stability of the tip of the stem is a key factor in the treatment algorithm.

Conflicts of interest

The authors declare that they have no conflict of interest.

References

- [1] D.J. Berry, Periprosthetic fractures associated with osteolysis: a problem on the rise, *J. Arthroplast.* 18 (2003) 107–111.
- [2] C.D. Watts, M.P. Abdel, D.G. Lewallen, et al., Increased risk of periprosthetic femur fractures associated with a unique cementless stem design, *Clin. Orthop. Relat. Res.* 473 (6) (2015 Jun) 2045–2053.
- [3] C.P. Duncan, B.A. Masri, Fractures of the femur after hip replacement, *Instr. Course Lect.* 44 (1995) 293–304 (Review).
- [4] S. Banerjee, R. Pivec, K. Issa, et al., Outcomes of shortstems in total hip arthroplasty, *Orthopedics* 36 (9) (2013 Sep) 700–707.
- [5] R. Bieger, A. Ignatius, R. Decking, et al., Primary stability and strain distribution of cementless hip stems as a function of implant design, *Clin. Biomech. (Bristol, Avon)* 27 (2) (2012) 158–164.
- [6] C.A. Engh, J.D. Bobyn, A.H. Glassman, Porous-coated hip replacement. The factors governing bone ingrowth, stress shielding, and clinical results, *J. Bone Joint Surg.* 69-B (1987) 45–55.
- [7] S. Ghera, L. Pavan, The DePuy Proxima hip: a short stem for total hip arthroplasty. Early experience and technical considerations, *Hip Int.* 19 (2009) 215–220.