

Isolated sinusitis sphenoidalis caused by *Trichoderma longibrachiatum* in an immunocompetent patient with headache

Etelka Molnár-Gábor,¹ Ilona Dóczi,² Lóránt Hatvani,³ Csaba Vágvölgyi³ and László Kredics³

Correspondence

László Kredics
kredics@bio.u-szeged.hu

¹Department of Otorhinolaryngology, Dr. Marron Clinics, Szeged, Hungary

²Department of Clinical Microbiology, Albert Szent-Györgyi Clinical Centre, University of Szeged, Szeged, Hungary

³Department of Microbiology, Faculty of Science and Informatics, University of Szeged, Szeged, Hungary

We present a case of isolated sinusitis sphenoidalis caused by *Trichoderma longibrachiatum*, an emerging causal agent of fungal infections with an often fatal outcome. A *Trichoderma* strain was isolated from secretion obtained from the sinus sphenoidalis of a rhinosinusitis patient and identified by sequence analysis of two loci as *Trichoderma longibrachiatum* from the Longibrachiatum Clade of the genus *Trichoderma*. *T. longibrachiatum* can trigger a fatal pathomechanism in immunodeficient patients, but only rarely causes disease in healthy people. The case presented is unique because the patient was not immunocompromised.

Received 20 February 2013

Accepted 7 May 2013

Certain groups of filamentous fungi have increasing clinical importance as emerging opportunistic pathogens in humans. Species belonging to the genus *Trichoderma* (Ascomycota, Hypocreales) are also on the growing list of potential fungal pathogens (Kredics *et al.*, 2011). Clinical cases with the involvement of *Trichoderma* strains known from the literature include skin and lung infections, peritonitis in peritoneal dialysed patients as well as disseminated infections in the liver, brain, heart and stomach of immunocompromised patients (Kredics *et al.*, 2011). Here, we present a case of rhinosinusitis caused by *Trichoderma longibrachiatum* in an immunocompetent patient with a headache, which was successfully treated by antifungal and surgical therapy.

Case report

A 29-year-old female patient presented with a frontal and occipital headache for more than 15 years. Two years before admittance to our outpatient clinic, she experienced a worsening nasal blockage that was resistant to conventional medical treatments (antibiotics, antihistamine and decongestant nasal drops). She lost her sense of smell and complained of retrobulbar pressure. She was constantly under otorhinolaryngological care because of pansinusitis and allergic rhinitis. Elevated erythrocyte sedimentation rate and eosinophilia were recorded in her laboratory

results, skin prick testing was positive for fungal antigens (*Alternaria*, *Penicillium*, *Cladosporium*), hazelnut and dust mite. The conventional medical treatments were ineffective. Although the patient underwent functional endoscopic sinus surgery (FESS) twice during the year before her presentation, her complaints intensified. The computer tomographic (CT) scan of her head revealed a subtotal inhomogeneous shadow in the sphenoid sinus (Fig. 1a). The magnetic resonance image (MRI) obtained, because of an area suspicious of dehiscence on the cranial wall of the sinus sphenoidalis, showed regular internal and external liquor spaces. The brain substance did not show a pathological picture. Endoscopic investigation revealed swollen, greyish-white nasal mucosa, and a synechia was found between the middle turbinate on the right side and the lateral nasal wall, from behind which a mucinous, yellow punctated secretion was drained. A fungal infection was suspected due to the inhomogeneous shadow in the sphenoid sinus and the swollen, greyish-white nasal mucosa. Since the extended infection process destroyed the upper wall of the sinus sphenoidalis, the extraction of the fungal mass was planned in two steps in order to protect the neighbouring structures. First, the majority of the extraordinarily thick, of partial sawdust consistency, hard fungal mass was extracted through the completely enlarged sphenoidal ostium, leaving behind the core of the mass. Plenty of eosinophil granulocytes were revealed during histological examination of the mass. The clinical specimen was from the mass and inoculated onto chocolate, blood and eosin methylene blue agar plates for

Abbreviations: CT, computer tomographic; MIC, minimal inhibitory concentration; ITS, internal transcribed spacer.

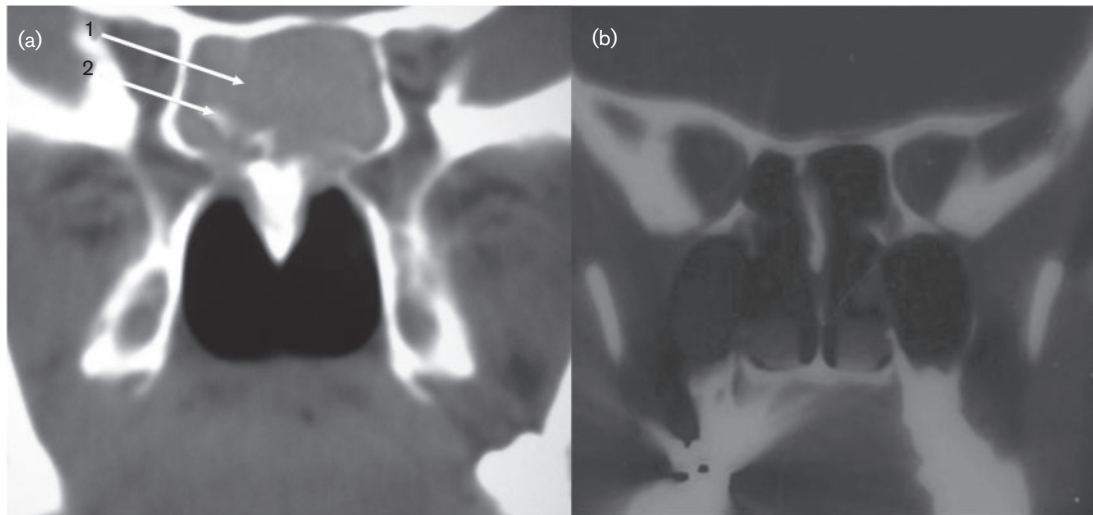


Fig. 1. Computer tomography scan of the sinuses (a) before the first operation: arrow shows subtotal inhomogeneous shadow (arrow 1) with the destruction of the septum in the sinus sphenoidalis (arrow 2); and (b) 2 years after the second operation.

culturing bacteria, and onto Sabouraud chloramphenicol agar plates to recover fungi. Plates were incubated at 37 °C for 1 day. After the incubation period, *Escherichia coli* was cultured from the sample. The isolate was sensitive to all antibiotics recommended against this species. Sabouraud medium was incubated further at room temperature. After a 72 h incubation period counted from the first inoculation, a filamentous fungus was recovered on the medium. The isolate was subcultured and deposited at the Department of Clinical Microbiology, Faculty of Medicine, the University of Szeged as strain 46967/2006.

After surgery, the patient's 10-year-long headache disappeared immediately. Postoperatively, the sphenoid entrance and the sphenoidal recessus were free and without polyps on both sides. Looking into the sphenoid sinus, a mucosa degenerated by polyps could be seen with thick, sticky, yellow-black fungal fragments on a hard, black base on the upper wall. Due to this mycotic residue, the sphenoid sinus was suctioned regularly under endoscopic vision in order to ensure good ventilation. As additional therapy, topical steroid nasal lavage, topical amphotericin B therapy and suction were introduced.

Surgery was carried out a second time after 4 months, during which the well-ventilated, black and hard fungal crust (which by this time was already cracked) was carefully removed by the suctioning equipment. On the basis of the control CT scan (Fig. 1b) and endoscopic picture 2 years after the operation, the patient can be considered now as healthy, without any complaints.

The identification procedure of the fungal isolate was started with macro- and micro-morphological examinations. Colonies were flat, rapidly growing and yellowish-green in

colour with green tufts of sporulation on Sabouraud agar. Diffusible yellow pigment was seen around the colonies in the medium. Strain 46967/2006 was able to grow not only at 25 °C, but also at 37 °C on both minimal medium (10 g l⁻¹ glucose, 5 g l⁻¹ (NH₄)₂SO₄, 5 g l⁻¹ KH₂PO₄ and 1 g l⁻¹ MgSO₄ in distilled water) and yeast extract-glucose medium (1 g l⁻¹ yeast extract, 1 g l⁻¹ glucose in distilled water). This thermotolerant property is a prerequisite of causing infections in the human body. Microscopic structures of the isolate were examined by the adhesive tape technique (St-Germain & Summerbell, 1996). Hyphae were smooth and septate, conidiophores were long and branched with flask-shaped phialides. Chlamydospores were present. Based on these observations the isolate was identified as a *Trichoderma* species.

Under the synonym identifier SzMC IM3, strain 46967/2006 was identified as *T. longibrachiatum* based on the sequence analysis of the internal transcribed spacer (ITS) region (ITS1 – 5.8 S rRNA gene – ITS2) of the rRNA gene cluster and fragments of the translation elongation factor 1 α (*tef1*), endochitinase (*chi-18-5*) and calmodulin (*cal1*) genes (Druzhinina *et al.*, 2008).

The Etest method (AB BIODISK) for moulds was applied for the determination of minimal inhibitory concentration (MIC) values of amphotericin B, fluconazole, itraconazole, voriconazole and caspofungin according to the manufacturer's instructions. The Etest drug concentrations ranged from 0.016 to 256 $\mu\text{g ml}^{-1}$ for fluconazole, and from 0.002 to 32 $\mu\text{g ml}^{-1}$ for itraconazole, voriconazole, amphotericin B and caspofungin. The isolate proved to be fully resistant to fluconazole (MIC >256 $\mu\text{g ml}^{-1}$) and itraconazole (MIC >32 $\mu\text{g ml}^{-1}$). MIC values of amphotericin B, voriconazole and caspofungin were 0.5, 0.5 and 0.25 $\mu\text{g ml}^{-1}$, respectively.

Discussion

The first summary about the clinical involvement of the genus *Trichoderma* was published by Kredics *et al.* (2003), which was recently followed by a more extensive and updated literature review (Kredics *et al.*, 2011). Opportunistic infections of humans caused by *Trichoderma* species include rare cases of acute invasive sinusitis and rhinosinusitis, hypersensitivity pneumonitis, peritonitis in continuous ambulatory peritoneal dialysis patients, brain abscess, liver infection, necrotizing stomatitis, skin infection and pulmonary infections of patients with haematological malignancies, disseminated infections of transplant recipients, cerebrospinal fluid infection, endocarditis and otitis externa (Kredics *et al.*, 2011).

A series of clinical *Trichoderma* isolates were identified based on their morphological characters only, which may result in misidentifications due to the lack of expertise. Therefore the application of molecular techniques, especially DNA barcoding based on sequences of the ITS region (Druzhinina *et al.*, 2005) and a fragment of the *tef1* gene (Druzhinina *et al.*, 2008) is suggested to confirm the species-level diagnosis of clinical *Trichoderma* isolates. The application of these methods revealed that the most frequent, almost exclusive causal agent of opportunistic infections within the genus *Trichoderma* is *T. longibrachiatum* (Kuhls *et al.*, 1999; Druzhinina *et al.*, 2008), a member of the Longibrachiatum Clade that was recently revised by Samuels *et al.* (2012), who also provided detailed morphological descriptions of the clade members including *T. longibrachiatum*. Druzhinina *et al.* (2008) examined 36 environmental and 15 clinical isolates belonging to *T. longibrachiatum/Hypocrea orientalis* applying multilocus phylogenetic analysis with the involvement of the ITS region and fragments of the *tef1*, calmodulin (*cal1*) and endochitinase (*chi-18-5*) genes. This study revealed that *H. orientalis* is also a potential opportunistic human pathogen, and that theoretically all strains of *T. longibrachiatum* and *H. orientalis* might be able to cause infections in humans. The Joint Genome Institute of the US Department of Energy has completed the genome sequencing of the *T. longibrachiatum* type strain ATCC 18648 (<http://genome.jgi-psf.org/Trilo1/Trilo1.home.html>), which will certainly help to reveal the mechanisms of its pathogenicity.

The clinical occurrence of a further four *Trichoderma* species has also been confirmed by molecular techniques. These are *T. harzianum* (Guarro *et al.*, 1999; Kantarcioglu *et al.*, 2009), *T. citrinoviride* (Kuhls *et al.*, 1999), *T. atroviride* (Ranque *et al.*, 2008), and an unknown *Hypocreaceae* species (Druzhinina *et al.*, 2007), which shares identical ITS and *rpb2* (the gene encoding the second largest subunit of RNA polymerase II) sequences with *Hypocrea peltata*, a recently described sexually reproducing species from the genus *Hypocrea*, the teleomorph state of *Trichoderma* (Samuels & Ismaiel, 2011).

T. longibrachiatum is a commonly occurring, but less abundant component of *Trichoderma* communities isolated

from soil (Druzhinina *et al.*, 2008). However, this species appears to be more abundant in indoor environments such as water-damaged buildings (Mikkola *et al.*, 2012), and it has also been detected in sputum and in the sinus ethmoidalis of healthy humans (Kredics *et al.*, 2011). The genetic identity of environmental and clinical *T. longibrachiatum* isolates suggests the danger of nosocomial infections and highlights the need for ecological studies of spore dispersal as a source of human mycoses (Druzhinina *et al.*, 2008).

Acute invasive sinusitis caused by *T. longibrachiatum* was reported before in a patient after small bowel and liver transplantation; this was successfully treated with endoscopic sinus operations for debridement, irrigation of the maxillary sinus and oral antifungal treatment with amphotericin B followed by itraconazole (Furukawa *et al.*, 1998). A case of allergic fungal sinusitis due to *T. longibrachiatum* in a patient with a history of atopy and asthma was also documented by Tang *et al.* (2003). The patient recovered successfully following a combination of sinus lavage, oral corticosteroids, itraconazole, and allergen immunotherapy. Kuhls *et al.* (1999) briefly mentioned a further case of maxillary sinus infection. Thus, to the best of our knowledge, the presented case is the fourth known sinusitis case worldwide with the involvement of *T. longibrachiatum*.

Although *T. longibrachiatum* is known as an emerging opportunistic pathogen of mainly immunocompromised patients, the presented case indicates that occasionally this species can cause diseases in immunocompetent patients as well. This report also demonstrates the importance of wide-ranging medical and radiological examinations in cases of chronic headache and nasal congestion. In special cases of severe fungal infection, the appropriately chosen therapy and the consequent postoperative treatment can improve the chances of success.

References

- Druzhinina, I. S., Kopchinskiy, A. G., Komoń, M., Bissett, J., Szakács, G. & Kubicek, C. P. (2005). An oligonucleotide barcode for species identification in *Trichoderma* and *Hypocrea*. *Fungal Genet Biol* **42**, 813–828.
- Druzhinina, I. S., LaFe, K., Willinger, B., Komoń-Zelazowska, M., Ammirati, J., Kubicek, C. P. & Rogers, J. D. (2007). An unknown *Hypocreaceae* species isolated from human lung tissue of a patient with non-fatal pulmonary fibrosis. *Clin Microbiol Newsl* **29**, 180–184.
- Druzhinina, I. S., Komoń-Zelazowska, M., Kredics, L., Hatvani, L., Antal, Z., Belayneh, T. & Kubicek, C. P. (2008). Alternative reproductive strategies of *Hypocrea orientalis* and genetically close but clonal *Trichoderma longibrachiatum*, both capable of causing invasive mycoses of humans. *Microbiology* **154**, 3447–3459.
- Furukawa, H., Kusne, S., Sutton, D. A., Manez, R., Carrau, R., Nichols, L., Abu-Elmagd, K., Skedros, D., Todo, S. & Rinaldi, M. G. (1998). Acute invasive sinusitis due to *Trichoderma longibrachiatum* in a liver and small bowel transplant recipient. *Clin Infect Dis* **26**, 487–489.
- Guarro, J., Antolín-Ayala, M. I., Gené, J., Gutiérrez-Calzada, J., Nieves-Diez, C. & Ortoneda, M. (1999). Fatal case of *Trichoderma*

harzianum infection in a renal transplant recipient. *J Clin Microbiol* **37**, 3751–3755.

Kantarcioğlu, A. S., Celkan, T., Yücel, A., Mikami, Y., Kurugoglu, S., Mitani, H. & Altas, K. (2009). Fatal *Trichoderma harzianum* infection in a leukemic pediatric patient. *Med Mycol* **47**, 207–215.

Kredics, L., Antal, Z., Dóczy, I., Manczinger, L., Kevei, F. & Nagy, E. (2003). Clinical importance of the genus *Trichoderma*. *Acta Microbiol Immunol Hung* **50**, 105–117.

Kredics, L., Hatvani, L., Manczinger, L., Vágvölgyi, C. & Antal, Z. (2011). *Trichoderma*. In *Molecular Detection of Human Fungal Pathogens*, pp. 509–526. Edited by D. Liu. London, UK: Taylor & Francis Group.

Kuhls, K., Lieckfeldt, E., Börner, T. & Guého, E. (1999). Molecular reidentification of human pathogenic *Trichoderma* isolates as *Trichoderma longibrachiatum* and *Trichoderma citrinoviride*. *Med Mycol* **37**, 25–33.

Mikkola, R., Andersson, M. A., Kredics, L., Grigoriev, P. A., Sundell, N. & Salkinoja-Salonen, M. S. (2012). 20-Residue and 11-residue

peptaibols from the fungus *Trichoderma longibrachiatum* are synergistic in forming Na⁺/K⁺-permeable channels and adverse action towards mammalian cells. *FEBS J* **279**, 4172–4190.

Ranque, S., Garcia-Hermoso, D., Michel-Nguyen, A. & Dumon, H. (2008). Isolation of *Trichoderma atroviride* from a liver transplant. *J Med Mycol* **18**, 234–236.

Samuels, G. J. & Ismaiel, A. (2011). *Hypocrea peltata*: a mycological Dr Jekyll and Mr Hyde? *Mycologia* **103**, 616–630.

Samuels, G. J., Ismaiel, A., Mulaw, T. B., Szakacs, G., Druzhinina, I. S., Kubicek, C. P. & Jaklitsch, W. M. (2012). The *Longibrachiatum* Clade of *Trichoderma*: a revision with new species. *Fungal Divers* **55**, 77–108.

St-Germain, G. & Summerbell, R. (1996). *Identifying Filamentous Fungi*, p. 263. Belmont, CA: Star Publishing Company.

Tang, P., Mohan, S., Sigler, L., Witterick, I., Summerbell, R., Campbell, I. & Mazzulli, T. (2003). Allergic fungal sinusitis associated with *Trichoderma longibrachiatum*. *J Clin Microbiol* **41**, 5333–5336.