

“CONEHEADS” IN THE GEPID PERIOD

Artificial cranial deformation in a community by the Tisza River

ÁGOTA MADAI^{1,4} – TAMÁS SZENICZEY² – ZSÓFIA RÁCZ³ – ANTÓNIA MARCSIK⁴ – ÁGNES B. TÓTH⁵
– GÁBOR WILHELM⁶ – TAMÁS HAJDU²

Hungarian Archaeology Vol. 11 (2022), Issue 3, pp. 16–25. <https://doi.org/10.36338/ha.2022.3.4>

The deliberate physical transformation of the human body is a very ancient custom that humans have been practicing since prehistoric times. Most methods concerned the soft tissues of the body, the piercing, expanding, and stretching of which have been widespread in terms of both time and space. Significantly fewer procedures targeted the bony skeletal parts. One of these is the artificial modification of the skull, of which, also, examples are known from almost every historical period and continent.

The custom of artificial cranial deformation became quite widespread in the Carpathian Basin in the Hun and Gepid Periods. This study presents the anthropological characteristics of people with artificially deformed skulls in the Gepid Period cemetery at Tiszaug-Országúti bevágás, unearthed in two seasons (2018–19). It aims to contribute to our current knowledge of the custom of artificial cranial modification in the Carpathian Basin in the Gepid Period.

Keywords: historical anthropology, body modification, artificial cranial deformation, Gepid Period in the Carpathian Basin

PHYSICAL MODIFICATION OF THE HUMAN BODY

There are countless ways to modify a human body, some of which were already known and practised in prehistoric times (CZIGÁNY 2001; JÓZSA 2011). However, only a few procedures targeted the human skeleton, whereas most involved the piercing, expanding, and stretching of soft tissues (CZIGÁNY 2001). The perhaps most known example of bone deformation is the so-called “lotus feet”, the ancient custom of foot binding in China (JEFFREYS 2005). The artificial deformation of the skull is another procedure to alter the skeletal proportions. The act is deliberate, and the result irreversible because, while the fontanelles of a child’s skull are soft, allowing an alteration of its shape, by adulthood, they become ossified (BERECZKI & MARCSIK 2006; HAKENBECK 2018). As the procedure affects the bony parts of the body that may persist and thus, are present in the archaeological record, it is possible to study the custom in historical communities based on the related anthropological record.

Available data show that humans have practiced artificial cranial deformation in diverse historical periods on every continent (ORTNER 2003). We know of deformed skulls from every corner of the world, including several European countries (e.g., Austria, Switzerland, Germany, Italy, France, etc.). The custom probably emerged in Europe first in the Neolithic (CUSSENOT ET AL. 1992). In historical times, it was the most widespread in the territory of today’s Hungary (BERECZKI & MARCSIK 2005), first appearing with (according to the available data) Sarmatian and Alan peoples in the *Barbaricum* during the Roman Imperial Period (HAJDU & BERNERT 2007; ISTVÁNOVITS & KULCSÁR 2018), and being constantly present throughout the Migration Period. The custom seems to have vanished entirely with the arrival of the Hungarians in the Conquest Period (BERECZKI & MARCSIK 2005). It was the most popular in the Hun Period but also present throughout the Gepid and in the Early Avar Periods (RÁCZ 2019).

¹ Hungarian Natural History Museum, Department of Anthropology, e-mail: madai.agota@nhmus.hu

² Eötvös Loránd University, Department of Biological Anthropology, Institute of Biology

³ Eötvös Loránd University, Institute of Archaeological Sciences

⁴ Szeged University, Department of Biological Anthropology, Institute of Biology

⁵ Szeged University, Department of Archaeology

⁶ Katona József Museum, Kecskemét

CURRENT STATE OF RESEARCH

“The answer to the macrocephal problem⁷ is in Hungary”, wrote Lajos Bartucz in 1936 (BARTUCZ 1936). The research into the custom of artificial cranial deformation in Hungary started in the 19th century. In the early decades of research, preceding the systematic archaeological excavations in the 20th century, only stray finds were discovered and, thus, available for anthropologists. The anthropological series we can work with today – from sites including, amongst others, Hajdúnánás, Berettyóújfalú, Tiszaug, and Tiszapüspöki – are all yielded by modern excavations. The systematic processing and evaluation of the anthropological record of these sites have been carried out, and the results are under publication (KOVÁCS 2022; VIDA ET AL. 2019).

STUDY MATERIAL AND METHODS FOR DETERMINING SEX AND ESTIMATING AGE AT DEATH

Altogether 25 of the 147 observable skulls from the Tiszaug cemetery (comprising a total of 194 individuals) feature definite marks of artificial deformation (Table 1). In six cases, however, it cannot be decided whether the deformation is the result of deliberate action (Fig. 1). Therefore, these individuals are not discussed in the study.

With children under 14, age at death estimation is based on the number (SCHOUR & MASSLER 1941) and degree of development (UBELAKER 1978) of the deciduous and permanent teeth and the length of the appendicular bones (STLOUKAL & HANÁKOVÁ 1978). In the case of children and adolescents, the estimations were correlated with one based on the state of

ossification of the epiphyseal and apophyseal growth plates⁸ of the long and tubular bones (SCHINZ ET AL. 1952), the sternal end of the clavicle (FEREMBACH ET AL. 1979), and the *synchondrosis sphenoccipitalis* closure.⁹ In the case of *adults* and *matures* (40–59 years old at death), the estimations were based on the morphological features observed on the pubic *symphysis* (a type of cartilaginous joint; TODD 1920; BROOKS & SUCHEY 1990), the morphological characteristics of the ribs’ sacral end (ISCAN ET AL. 1984), the first rib’s costal face, and the tubercle facet’s age-related morphological changes (DIGANGI ET AL. 2009), the degree of ossification of the palatine bone sutures (MANN ET AL. 1991), and the stage of suture ossification on the external cranial surface (MEINDL & LOVEJOY 1985). The latter was also applied to *seniors* (over 60 years old at death). The following biological age groups were determined according to a classification by Martin and Saller (MARTIN & SALLER 1957): *neonatus* (0–1 year), *infans I* (2–6 years), *infans II* (7–14 years), *juvenis* (15–19 years), *adultus* (20–39 years), *maturus* (40–59 years) and *senium* (over 60 years).

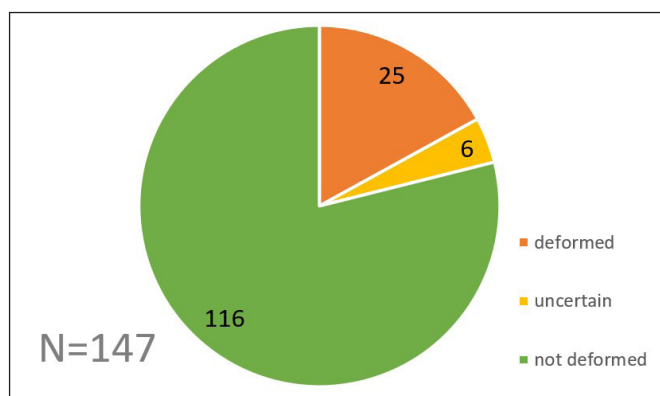


Fig. 1. Proportion of individuals with an artificially deformed cranial vault in the Gepid Period cemetery at Tiszaug-Országúti bevágás (N=number of individuals)

RESULTS

All age groups but newborns (*neonatus*) and juveniles (*juvenis*) are represented in the series comprising individuals with artificially deformed crania. Most belong to the *adultus* age group, but the number of *maturus* people is also considerable. This proportion, i.e., the prominence of young adults and matures in

⁷ In the beginning, individuals with deformed skulls were referred to as “macrocephal,” meaning “long-headed;” the expression was also used by some scholars later.

⁸ *Epiphysis*: the end of the long bones. During childhood, it is distinct from the bone’s central part, the *diaphysis*, and the two fuse together gradually by adulthood. The rate and extent of ossification vary by bone; therefore, it is a reliable age marker for children and juveniles. *Apophysis*: the end part or normal outgrowth of a bone with the same characteristics as the *epiphysis*.

⁹ The *sphenoccipital synchondrosis* is a cartilaginous joint between the sphenoid and the occipital bones, which becomes ossified at a certain age.

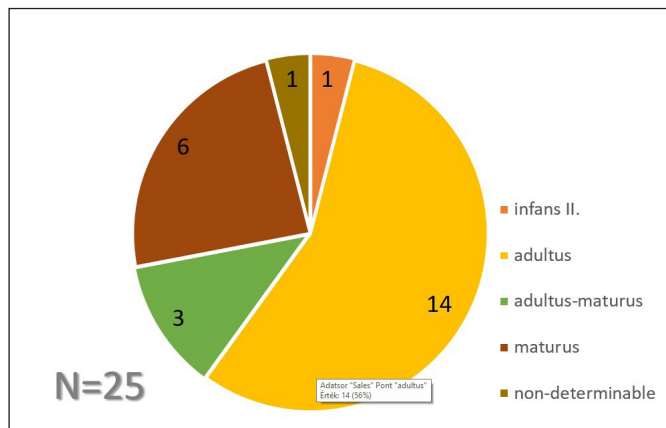


Fig. 2. Age distribution of individuals with an artificially deformed cranial vault in the Gepid Period cemetery at Tiszaug-Országúti bevágás (N=number of individuals)

the series, accompanied by a relative lack of children, might mark the gradual fading of a custom of previous generations or a family tradition (Fig. 2).

Morphological sex determination was based on 21 secondary sex markers (ÉRY ET AL. 1963); it was possible to determine biological sex in 23 cases (Fig. 3). Although the series comprises 7 males and 16 females, showing a seemingly marked prevalence of women among the individuals with artificially deformed skulls, it must be kept in mind that the case number is relatively low and, thus, does not provide a reliable base for drawing general conclusions (BERNERT 2012). Neither especially feminine (*hyperfeminine*) nor extra masculine (*hypermasculine*) individuals were observed in the series.

Despite the related anthropological record being relatively fragmented and incomplete, the applied modification methods could be reconstructed in most cases. Most skulls (16) were deformed using the double-bandage method, where the first bandage was wrapped around the forehead and the nape of the neck, while the other was fastened in the line behind the bregma point,¹⁰ probably the angle of the mandible, and the nape of the neck (Figs. 4–5). In most cases, the deformation is most expressed at the forehead and nape of the neck, indicating that some tool was also applied in the process to increase its efficiency (LIPTÁK & MARCSIK 1977). While the two-bandage method was the most widespread, other types of deformation also appear in the related record, including examples of one-bandage, *tabular* or oblique, and circular defor-

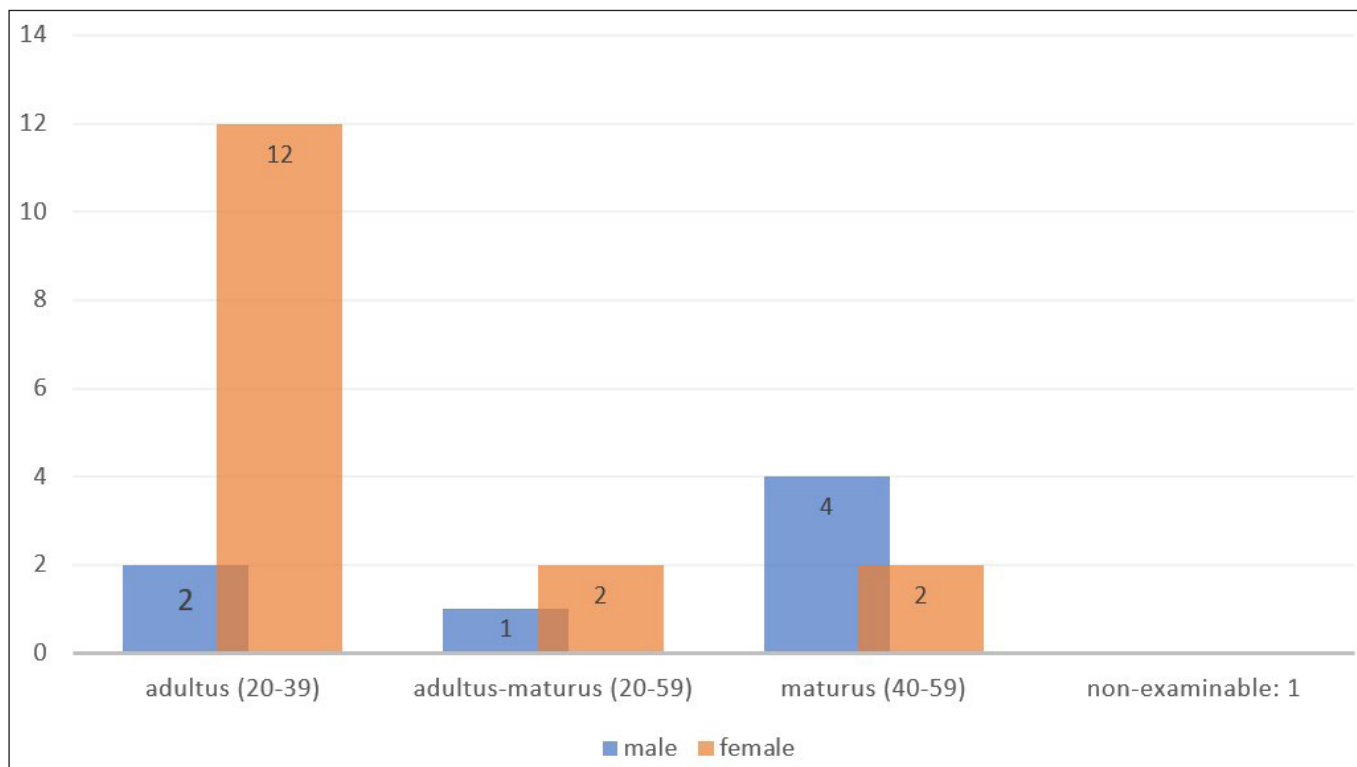


Fig. 3. Biological sex distribution of individuals with an artificially deformed cranial vault in the Gepid Period cemetery at Tiszaug-Országúti bevágás (N=number of individuals)

¹⁰ The *bregma* is the anatomical point on the skull at which the coronal suture is intersected perpendicularly by the sagittal suture.

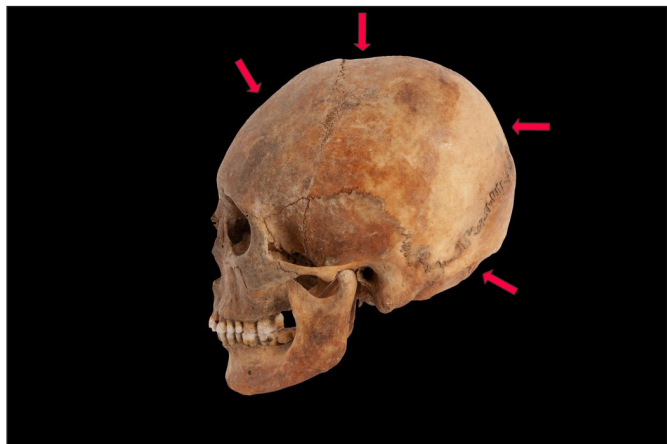

Fig. 4. Mild case of two-bandage deformation (SN 546, 25-35 years old at death, woman; photo by Szabolcs Dankó)

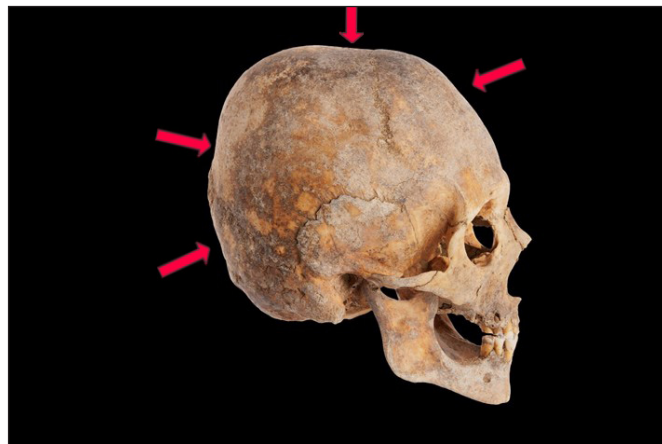

Fig. 5. Marked case of two-bandage deformation (SN 259, 40-50 years old at death, man; photo by Szabolcs Dankó)

mations. Different categories of cranial transformation have been determined based on the applied method and the morphological traits of the deformed skull (GOSSE 1855; BROCA 1873; DINGWALL 1921). The Gepid Period community of Tiszaug features diverse variations of more than one basic type; an exact morphological classification of the related record, like that of the deformed skulls recovered from Mőzs-Icsei dűlő, however, is yet to be carried out (KNIPPER ET AL. 2020).

We could apply the deformation scale (describing the degree of transformation) by Oetteking, Ginzburg, and Žirov¹¹ (GINZBURG & ŽIROV 1949) in only a few cases; consequently, we had to apply another preset scale to describe the degree of deformation with the rest of the series. This scale comprised the following categories: very mild, mild, average, marked, and extreme. The series shows significant variability in this respect with no underlying trends (Figs. 4–5), indicating that the Tiszaug community practiced various methods to diverse extents to transform the cranial vault, but revealing nothing about the custom’s social or cultural background. It must be noted that the final shape of the deformed skull largely depends on the natural cranial shape of the individual.

Only a few artificial deformation-related lesions (JÓZSA & PAP 1992; PAP & JÓZSA 2006) were observed in the series: incomplete closure of the metopic sutures (*sutura metopica*; Fig. 6), a protuberance in the upper

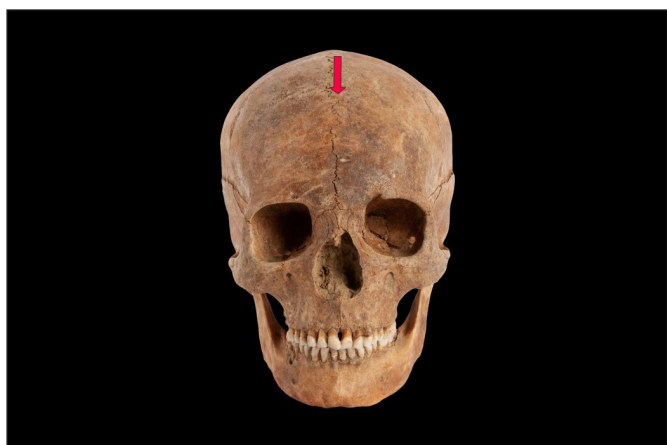

Fig. 6. *Sutura metopica*, incomplete closure of the metopic suture (SN 546, 25-35 years old at death, woman; photo by Szabolcs Dankó)



Fig. 7. *Tuber praebregmaticum* (SN 184, 35-40 years old at death, photo by Szabolcs Dankó)

¹¹ Several systems have been developed to describe the degree of deformation of the cranial vault. The scale by Ginzburg and Žirov offers an improved solution compared to earlier systems, as it considers both the most and least changing points of measurement. This way, it can reveal how much a skull had been deformed (elongated) in relation to the least-changing glabella-inion line, thus providing a relative value on how much it has become altered compared to its original extent.

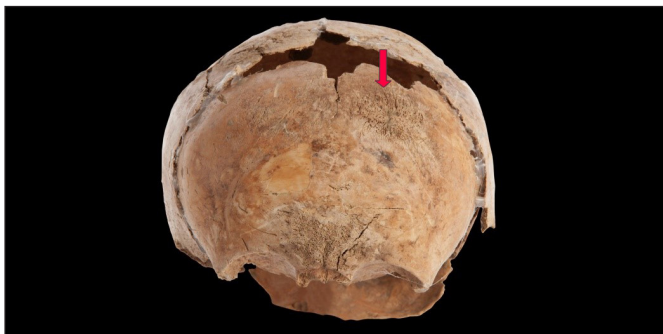

Fig. 8. Porotic lesions due to porotic hyperostosis (SN 348, 1-2 years old at death, photo by Szabolcs Dankó)

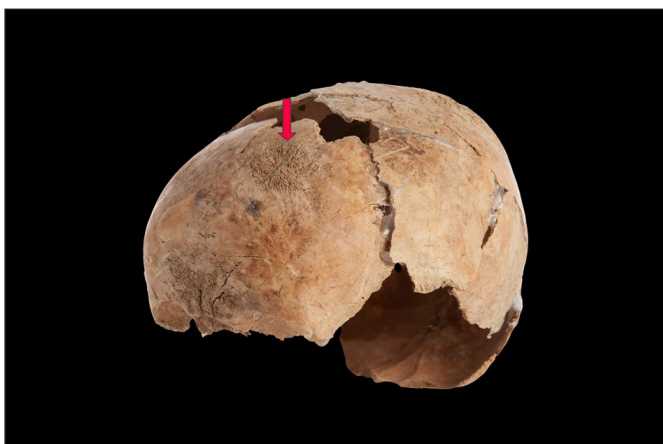

Fig. 9. Porotic lesions due to porotic hyperostosis (SN 348, 1-2 years old at death, photo by Szabolcs Dankó)

zone of the forehead before the crown suture (*tuber praebregmaticum*; Fig. 7), and the deformation of the mandible's head joint. Compared to non-modified individuals in the same community, the arterial grooves on the inner cranial surfaces were deeper and more expressed in the case of those with modified skulls, perhaps as a result of increased cranial pressure due to deformation (O'LOUGHLIN 1996).

Some pathological lesions make determining whether a skull has undergone artificial deformation difficult and uncertain (ORTNER 2003). Such lesions

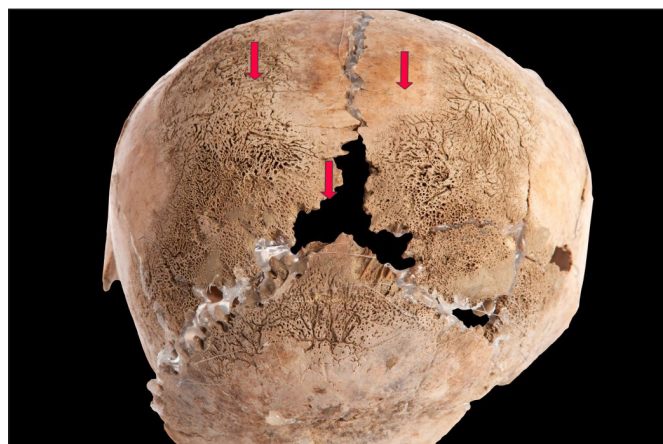


Fig. 10. Porotic lesions due to porotic hyperostosis (SN 348, 1-2 years old at death, photo by Szabolcs Dankó)

appear on the skull of a 1-2-year-old child from grave no. 348, whose cranial vault features extended and serious porotic hyperostosis (PH)¹² (Figs. 8–10). This condition is a symptom affecting the bones, caused by a genetic or acquired disorder of the hematopoietic system (e.g., iron deficiency anaemia; LÁSZLÓ 2018). PH is one of the most frequent lesions observed in the anthropological record of past peoples, interpreted as a key indicator of the quality of their life and accessible food resources (PAPATHANASIAU ET AL. 2009). The deformation featured by the small child's skull could have developed without any attempt to artificially modify its shape, simply because of the disease, especially as lesions are also present in the potentially bandaged zones. It must be highlighted, though, that currently, there is no proof of any connection between artificial cranial deformation and PH.

SOCIAL ARCHAEOLOGICAL ASPECTS

Artificial cranial deformation was present in several independent socio-cultural settings in Europe throughout the Migration Period (RÁCZ 2019), as marked by the related burials displaying diverse funerary rites and degrees of wealth. Therefore, several studies have focused on the custom's social archaeological context and social implications (BLOM 1999; TORRES-ROUFF & YABLONSKY 2005; TUBBS ET AL. 2005; HAKENBECK

¹² Porotic hyperostosis affects the cranial vault primarily, but the symptoms may also appear on other skeletal parts (e.g., sternum, ribs, and long bones). Due to a disorder of the hematopoietic system, the compact bone tissue becomes thin or, in the most severe cases, dissolves completely, leaving the spongy bone layer uncovered. Small porotic holes appear on the bone surface in the initial stage, but the spongy bone layer is still covered (porotic stage). The compact bone tissue partially dissolves in the advanced (cribrotic) stage, leaving the spongy bone layer uncovered in spots. Finally, in the most severe cases, the spongy bone layer develops pathological outgrowths with bone spicules (spurs) that sometimes emerge 1–2 mm over the original bone surface (trabecular stage; JÓZSA ET AL. 2013). Based on their symptoms, the child from Tiszaug was in an advanced stage of the disease when died.

2018). An evaluation of the related findings from all over Europe revealed no direct connection between funerary rite, social position, and cranial deformation (SZÉCSÉNYI-NAGY 2008). Relatively few prodigally rich burials with the interred having an artificially deformed skull are known from the Carpathian Basin; the “Princess of Regöly” is an exception (MÉSZÁROS 1970). In Tiszaug, the burials of the individuals with artificially deformed skulls fit the rest of the cemetery and the general customs in the period in every respect, including funerary rites and grave goods, as well as the position, size, and orientation of the grave pits. These graves distribute evenly within the cemetery instead of forming distinct clusters. That neither of these burials, based on archaeological information, belongs to the late phase of the cemetery indicates that the custom faded in the community in the early 6th century AD at the latest. The presence of (small) children among the individuals with artificially deformed skulls is important in this respect, proving that the custom was practiced in the local community for some time, even after they had settled. However, the scarcity of more precisely datable burials (within the Gepid Period) prevents us from specifying the time when artificial cranial deformation was still practiced (save for a bone comb, most related graves were poor in grave goods). Few of the burials representing the local elite belonged to an individual with an artificially deformed skull and none of the richest ones. With most burials, the scarcity of grave findings is most certainly not the result of plundering. Conclusively, a deformed skull was not a marker of high social status in the area during the Migration Period (SZÉCSÉNYI-NAGY 2008).

CONCLUDING REMARKS

With 25 artificially deformed skulls, the Tiszaug cemetery’s anthropological record substantially contributes to the according series from the Carpathian Basin in the Gepid Period. Its real significance, however, is that currently, this is the only Gepid Period cemetery from the territory of Hungary with both the archaeological and anthropological records evaluated and published (for an example from Transylvania, see DOBOS & OPRENAU 2012). Based on the characteristics presented above, the individuals with artificially deformed skulls in the cemetery at Tiszaug fit the current anthropological picture of the Gepid Period population of the Carpathian Basin.

ACKNOWLEDGEMENTS

We are grateful to Szabolcs Dankó for the photographs in this article. The research was subsidized by the “Nemzet Fiatal Tehetségeiért Ösztöndíj” [Grant for the Young Talents of The Nation] programme (grant ID NTP-NFTÖ.B.0017) and grant no. NN 128035 by the National Research, Development and Innovation Office.

SNR	Torzítás mértéke/fajtája <i>Degree and type of deformation</i>	Kor <i>Age at death</i>	Nem <i>Sex</i>
126	enyhe (kettős bandázs)/ <i>mild, double bandage</i>	adultus (30–40)	nő/ <i>female</i>
184	erős (kettős bandázs)/ <i>marked, double bandage</i>	adultus (35–40)	nő/ <i>female</i>
201	kettős bandázs/ <i>double bandage</i>	adultus (30–39)	nő/ <i>female</i>
235	erős (kettős bandázs)/ <i>marked, double bandage</i>	adultus (25–35)	nő/ <i>female</i>
242	közepes/ <i>average</i>	maturus (45–55)	nő/ <i>female</i>
259	erős (kettős bandázs)/ <i>marked, double bandage</i>	maturus (40–50)	férfi/ <i>male</i>
264	erős (tabuláris)/ <i>marked, tabular</i>	adultus (25–35)	nő/ <i>female</i>
270	enyhe (egy bandázsos?)/ <i>mild, ?one bandage</i>	adultus (20–25)	nő/ <i>female</i>
288	közepes (kettős bandázs)/ <i>average, double bandage</i>	adultus (20–25)	nő/ <i>female</i>
299	kettős bandázs/ <i>double bandage</i>	maturus (40–50)	nő/ <i>female</i>

311	közepes (kettős bandázs)/average, double bandage	maturus (45–60)	férfi/male
324	erős (kettős bandázs)/marked, double bandage	adultus (30–40)	férfi/male
327	bandázs nyoma nem kivehető/no bandage mark	maturus (45–50)	férfi/male
331	kettős bandázs/ double bandage	adultus–maturus (35–50)	nő/female
334	enyhe (kettős bandázs)/mild, double bandage	infans II. (10,5–11,5)	nő/female
339	közepes (kettős bandázs)/average, double bandage	maturus (40–55)	férfi/male
343	extrém enyhe/ very mild	adultus (30–40)	férfi/male
347	enyhe (kettős bandázs?)/ mild, ?double bandage	adultus–maturus (35–50)	férfi/male
525	közepes (kettős bandázs)/average, double bandage	adultus?	nő/female
536	enyhe (kettős bandázs)/mild, double bandage	adultus (21–25)	nő/female
538	enyhe (kettős bandázs)/mild, double bandage	adultus (25–35)	nő/female
542	közepes (cirkuláris, tabuláris jellegű)/ average, circular or tabular	?	?
546	enyhe (kettős bandázs)/mild, double bandage	adultus (25–35)	nő/female
550	közepes (kettős bandázs)/average, double bandage	adultus (23–35)	nő/female
553	enyhe/közepes (cirkuláris)/ mild-average, circular	adultus–maturus (25–45)	nő/female

REFERENCES

- Bartucz L. (1936). A kiszombori temető gepida koponyái. *A Szegedi Városi Múzeum Kiadványai*. Szeged: Somogyi Könyvtár és Városi Múzeum, 178–203.
- Berezki Zs., Marcsik A. (2005). Újabb torzított koponyaleletek az Alföldről. In: Korsós, Z. (szerk.): *IV. Kárpát–medencei Biológiai Szimpózium. Előadások összefoglalói*. Budapest, 29–34.
- Berezki Zs. & Marcsik A. (2006). Artificial cranial deformation in Hungary. In: Mednikova, M. B. (ed.): *Artificial deformation of human head in Eurasian past. OPUS: Interdisciplinary Investigation in Archaeology*. Moscow: Institute of Archaeology RAS, 96–114.
- Bernert Zs. (2012). Adatok a morfológiai nem meghatározásához és a nemi arány értékeléséhez Kárpát-medencei történeti szériák alapján. *Anthropologiai Közlemények* 53, 69–78.
- Blom, D. (1999). *Tiwanaku regional interaction and social identity: a bioarchaeological approach* (PhD dissertation). Anthropology, University of Chicago, Chicago.
- Broca, P. (1873). Recherches sur la direction du trou occipital et sur les angles occipitaux et basilaires. *Révue d'Anthropologie*. Paris. T. II. Livr. 2.
- Brooks, S. –Suchey, J. M. 1990: Skeletal age determination based on the os pubis: a comparison of the Acsadi-Nemeskeri and Suchey-Brooks methods. In: *Human Evolution*, 5: 227–238.
- Cussenot, O., Silva, M. P. & Martin–Bouyer, Y. (1992). Modifications of the skull base in artificial deformations of the circumference of the head. *Surgical Radiologic Anatomy* 14, 43–50. <https://doi.org/10.1007/BF01628042>

Ágota Madai et al. • “Coneheads” in the Gepid Period

- Czigány J. (2001). A győri Xántus János Múzeum mesterségesen torzított koponyái. *Arrabona* 39, 249–264.
- Digangi, E. A., Bethard, J. D., Kimmerle, E. H. & Konigsberg, L. W. (2009). A new method for estimating age-at-death from the first rib. *American Journal of Physical Anthropology* 138, 164–176. <https://doi.org/10.1002/ajpa.20916>
- Dingwall, E. J. (1921). *Artificial cranial deformation*. London: John Bale, Sons & Danielsson, Ltd. <https://doi.org/10.1525/aa.1932.34.2.02a00190>
- Dobos, A. & Oprenau, C. H. (2012). Migration period and early medieval cemeteries at Fântânele (Bistrița–Năsăud County). In: Sorin, C. & Adrian, U. (eds.): *Patrimonium Archaeologicum Transylvanicum* 5, Cluj–Napoca: Mega Publishing House.
- Éry, K., Kralovánszky, A., Nemeskéri, J. (1963). Történeti népességek rekonstrukciójának reprezentációja. *Anthropologiai Közlemények* 7, 41–90.
- Ferembach, D., Schwidetzky, I. & Stloukal, M. (1979). Empfehlungen für die Alters- und Geschlechtsdiagnose am Skelett. *Homo* 30, 1–32.
- Ginzburg, V. V. & Žirov, E. V. (1949). Antropologičeskiematerialy iz Kelkolskogo katakombnogo mogiln'ika v doline r. Talas, Kirgizkoj SSR. *Sbornik MAE* 10, 211–265.
- Gosse, L. A. (1855). *Essai sur les déformations artificielles du crâne*. Paris: J.–B. Baillière.
- Hajdu T. & Bernert Zs. (2007). Embertani adatok a Tisza–vidék szarmata és gepida korához. *Tisicum–A Jász-Nagykun-Szolnok Megyei Múzeumok Évkönyve* 16, 327–343.
- Hakenbeck, S. (2018). Infant head shaping in Eurasia in the first millennium AD. In: Crawford, S., Hadley, D. M. & Shepherd, G. (eds.): *The Oxford Handbook of the Archaeology of Childhood*. Oxford: Oxford University Press, 483–504. <https://doi.org/10.1093/oxfordhb/9780199670697.013.26>
- Iscan, M. Y., Loth, S. R. & Wright, R. K. (1984). Age estimation from the rib by phase analysis: White Males. *Journal of Forensic Sciences* 29, 1094–1104. <https://doi.org/10.1520/JFS11776J>
- Istvánovits E. & Kulcsár V. (2018). *Egy elfelejtett nép, a szarmaták*. Nyíregyháza–Szeged: Jóna András Múzeum. <https://doi.org/10.55201/AXNY7538>
- Jeffreys, S. (2005). *Beauty and misogyny: Harmful practices in the west (Women and Psychology)*. New York: Routledge.
- Józsa L. (2011). Az emberi test mesterséges módosítása (deformálása). I. A koponyatorzítás. *Orvosi Hetilap* 152 (30): 1209–1213.
- Józsa L. & Pap I. (1992). Pathological alteration on artificially distorted skull. *Annales historico–naturales Musei nationalis hungarici* 84, 189–194.
- Józsa L., Pap I. & Farkas L. Gy. (2013). Napjainkra elfeledett csontelváltozás. Porosis hyperostotica. *Magyar Traumatológia*, 2013.56.2, 139–145.

Ágota Madai et al. • “Coneheads” in the Gepid Period

Knipper, C., Koncz I., Ódor J. G., Mende B. G., Rác Zs., Kraus, S., Gyseghem, R., Friedrich, R. & Vida, T. (2020). Coalescing traditions—Coalescing people: Community formation in Pannonia after the decline of the Roman Empire. *PLoS ONE* 15 (4): e0231760. <https://journals.plos.org/plosone/article?id=10.1371/journal.pone.0231760>, assessed 2022. 04. 06.

Kovács P. (szerk.) (2022). *Átkelők a túlvilágra. Két gepida temető a Közép–Tisza mentén*. Szolnoki Régészeti Tanulmányok 3, Szolnok.

László, O. (2018). *Gyermekkorú maradványok összehasonlító vizsgálata történeti népeiségekben*. Doktori értekezés, kézirat, Szeged.

Lipták P. & Marcsik A. (1977). Kora népvándorláskori embertani leletek Kelet–Magyarországon. Újabb adatok a mesterséges koponyatorzítás kérdéséhez. *Debreceni Déri Múzeum Évkönyve* 57, 35–48.

Mann, R. W., Jantz, R. L., Bass, W. M. & Willey, P. S. (1991). Maxillary suture obliteration: a visual method for estimating skeletal age. *Journal of Forensic Sciences* 36, 781–791.

Martin, R. & Saller, K. (1957). *Lehrbuch der Anthropologie I–II*. Stuttgart: Fischer Verlag.

Meindl, R. S. & Lovejoy, C. O. (1985). Ectocranial suture closure: A revised method for the determination of skeletal age at death based on the lateral–anterior sutures. *American Journal of Physical Anthropology* 67, 51–63.

Mészáros Gy. (1970). A regölyi korai népvándorláskori fejedelmi sír. *Archaeológiai Értesítő* 97, 66–92.

O’Loughlin, V. D. (1996). Comparative endocranial vascular changes due to craniosynostosis and artificial cranial deformation. *American Journal of Physical Anthropology* 101, 369–385.

Ortner, D. J. (2003). *Identification of pathological conditions in human skeletal remains* (2nd ed.). Washington: Academic Press.

Pap I. & Józsa L. (2006). A koponyatorzítás és annak következményei. In: Ujlaki-Pongrácz Zs. (szerk.): „*Hadak útján*”: *Népeiségek és iparok a népvándorlás korában*. Budapest: Pars Kft., 85–93.

Papathanasiou, A., Walker, P., Steckel, R., Larsen, C., Blondiaux, J., Grupe, G., Jankauskas, R., Maat, G., McGlynn, G., Roberts, C., Teschler–Nicola, M., Witter-Backofen, U., Agnew, A., Assis, S., Bereczki Zs., Bertrand, B., Betsinger, T., Boulter, S., Bourbou, C. & Williams, L. (2009). *The history of anemia and related nutritional deficiencies in Europe: Evidence from cribra orbitalia and porotic hyperostosis*. AAPA Symposium, Reconstructing health and disease in Europe: The early middle ages through the industrial period. https://www.academia.edu/20080419/The_history_of_anemia_and_related_nutritional_deficiencies_in_Europe_evidence_from_cribra_orbitalia_and_porotic_hyperostosis, assessed 2022. 04. 06.

Rác Zs. (2019). *A gepida királyság peremén. 5–6. századi temetők Hajdúnánás határából*. Habilitációs dolgozat, kézirat. Eötvös Loránd Tudományegyetem, Budapest.

Schinz, H., Baensch, W., Friedl, E. & Uehlinger, E. (1952). Ossifikationstabelle. In: Schinz, H. (ed.): *Lehrbuch der Röntgen–Diagnostik*. Stuttgart: Thieme, G. <https://doi.org/10.2106/00004623–195234010–00040>

- Schour, I. & Massler, M. (1941). Studies in tooth development: The growth pattern of human teeth. *The Journal of American Dental Association* 28, 1153–1160. <https://doi.org/10.14219/jada.archive.1940.0340>
- Stloukal, M. & Hanáková, H. (1978). Die Länge der Langsknochen altslawischer Bevölkerungen unter besonderer Berücksichtigung von Washstumsfragen. *Homo* 29, 53–69.
- Szécsényi-Nagy, A. (2008). *A koponyatorzítás szokása a Kárpát–medencében az V–VI. században, régészeti és antropológiai adatok alapján* (Szakdolgozat, kézirat). Eötvös Loránd Tudományegyetem, Budapest.
- Todd, T. W. (1920). Age changes in the pubis bone: I. The Male White Pubis. *American Journal of Physical Anthropology* 3, 285–334. <https://doi.org/10.1002/ajpa.1330030301>
- Torres-Rouff, C. & Yablonsky, L. T. (2005). Cranial vault modification as a cultural artifact: a comparison of the Eurasian steppes and the Andes. *Homo* 56, 1–16. <https://doi.org/10.1016/j.jchb.2004.09.001>
- Tubbs, R. S., Salter, E. G. & Oakes, W. J. (2005). Artificial deformation of the human skull: A review. *Clinical Anatomy* 19, 372–377. <https://doi.org/10.1002/ca.20177>
- Ubelaker, D. H. (1978). *Human skeletal remains: Excavation, analysis, interpretation*. Chicago: Taraxacum.
- Vida T., Quast, D., Rácz Zs. & Koncz I. (szerk.) (2019). *Collapse–Reorganization–Continuity. Gepids after the fall of the Hun Empire*. Proceedings of the International Conference at Eötvös Loránd University, Budapest, 14–15th December 2015, Budapest: Archaeolingua.