



Review Article

Impacted Maxillary Canines - Etiology, Diagnosis, Radiologic and Orthodontic Clinical

Nezar Watted^{1,2,3,*}, Muhamad Abu-Hussein², Péter Borbély⁴, Obeida Awadi³, Samir Masarwa³, Ali Watted⁵

¹University Hospital of Würzburg Clinics and Policlinics for Dental, Oral and Maxillofacial Diseases of the Bavarian Julius-Maximilian-University, Würzburg, Germany

²Department of Orthodontics, Faculty of Dentistry, Arab America University, Jenin P.O. Box 240, Palestine

³Department of Pediatric Dentistry and Orthodontics, University of Debrecen, Hungary

⁴Center for Dentistry Research and Aesthetics, Jatt 4491800, Israel

⁵Zentrum Zahn-, Mund- und Kieferkrankheiten, Klinik für Mund- Kiefer- und Gesichtschirurgie der Universität Hannover, Germany

ARTICLE INFO

Article history:

Received 15.05.2023

Accepted 29.05.2023

Published 30.06.2023

* Corresponding author.

Nezar Watted

*nezar.wattted@gmx.net

<https://doi.org/10.38138/JMDR/v9i1.23.nezar>

ABSTRACT

Canine maxillary teeth are aesthetically most dominant teeth which can present a smile as either holy or evi. They define the mouth's corner, are involved in the aesthetic smile, maintain occlusal stability, and design the shape of the dental arch. As the position of the impacted canines is amidst vital anatomical structures like the nasal cavity and sinuses in the maxilla and mental nerve in the mandible, a thorough radiographic evaluation to determine the position of the impacted canines is of utmost importance prior to any treatment planning. By using a radiographic image, a clinician can clearly identify its location. The present paper aimed to determine the prevalence, etiology, and clinical diagnosis of impacted maxillary canines in orthodontic patients.

Keywords: Canine impaction; Etiology; Inspection; Palpation; Radiographs; CT; CBCT; Transtomography

1 INTRODUCTION

Impacted teeth are those with a delayed eruption time or that are not expected to erupt completely based on clinical and radiographic assessment. Permanent maxillary canines are the second most frequently impacted teeth; the prevalence of their impaction is 1-2% in the general population⁽¹⁾. This is most likely due to an extended development period and the long, tortuous path of eruption before the canine emerges into full occlusion. Methods of diagnosis that may allow for early detection and prevention should include a family history, visual and tactile clinical examinations by the age of 9-10 years and a thorough radiographic assessment. Because there is a high probability that palatally impacted maxillary canines may occur with other dental anomalies, the clinician should be alert to this possibility⁽²⁾. When the condition is identified early, extraction of the maxillary deciduous canines may, in some cases, allow the impacted canines

to correct their paths of eruption and erupt into the mouth in relatively good alignment⁽³⁾. This interceptive treatment may further reduce complications associated with palatally impacted canines including root resorption of the lateral incisors and the need for more complex surgical and orthodontic intervention⁽⁴⁾.

2 DISTURBANCE OF THE NORMAL DEVELOPMENT

As the starting point to understanding abnormal development that creates canine ectopy, it is crucial to first understand how normal development occurs and how, in this scenario, the canine maneuvers its way in relation to the roots of the adjacent teeth.⁽¹⁾ As it does so, it influences the alignment of the adjacent teeth while, at the same time, its own eruption and alignment are influenced by them, until it erupts into the mouth and into its final position⁽²⁾.

3 THE NORMAL ERUPTION MECHANISM

The mechanism of normal eruption and normal alignment of the maxillary anterior teeth was first described by Broadbent, over 70 years ago^(1,2). He outlined how the eruption of the two central incisors produces an initial temporary arrangement, which is quite different from the final alignment that will be seen just 4 or 5 years later⁽⁴⁾. He called this temporary arrangement the Ugly Duckling stage (Figure 1). He described the orientation of the two newly erupted maxillary central incisors and the initial wide intercoronal space between them - the midline diastema - and how this spontaneously closes up quite naturally, in the fullness of time, with the eruption of the canine teeth⁽¹⁾. At the outset, he considered that the diastema was caused by the early developmental location of the unerupted lateral incisors, high up on the distal side of the roots of the central incisors. With one lateral incisor on each side in the narrow apical area, the roots of the central incisors are pushed together, to cause a distal flaring of their crowns.⁽³⁾ A hypothetic apically directed extension of their long axes converges somewhere above their developing apices⁽⁵⁾.

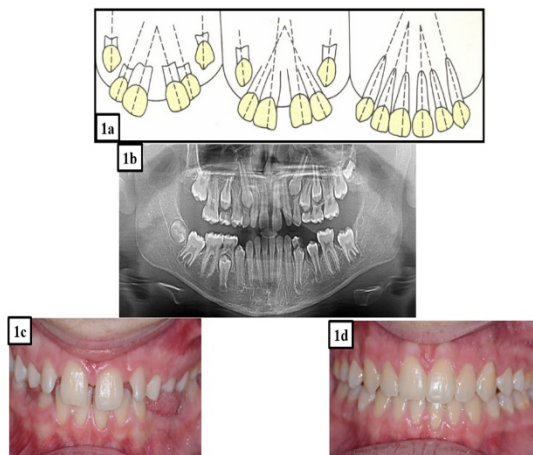


Fig. 1: a-d: Ugly Duckling Stage a: Schematic representation of the emergence and closure of the Diastema during canine development and its eruption, **b-d:** mesial Tipping of the canine at the beginning of development, the up righting of the canine in the course of development and eruption resulted a closure of the diasteme

In the ensuing months of normal development, the lateral incisors migrate downwards on the distal aspect of the central incisors, surrendering their constricting effect on the apices of the central incisors. As they move down past the CEJ, they eventually erupt, distally flared, into interproximal contact with the crowns of the central incisors^(1,5). The outcome of this is that their relationship to the incisors becomes reversed. The central incisor crowns are influenced to tip mesially, reducing the wide diastema and partially up righting the long axes of these teeth⁽⁶⁾.

At the age of 8 years, normally developing unerupted canines may be seen on a periapical radiograph to be mesially angulated, high on the distal side of the apical third of the roots of the lateral incisors, in much the same relationship that existed between the lateral and central incisors, a year or so earlier. The canines constrict the four developing incisor apices into a small space and their crown-to-root long axes converge to a virtual point high above their apices⁽¹⁻³⁾

During the ensuing 2-3 years, the downward eruptive movements of the canines are guided along the distal aspect of the roots of the lateral incisors and, as they move down, they release their “stranglehold” on the incisor apices and generate a progressive mesial up righting of all four incisor crowns as they go. This results in a closing off of what remains of the midline diastema and an integral chain of interproximal contacts between the crowns of the anterior 6 teeth⁽⁵⁾.

This account of the natural dynamics of eruption and alignment of the maxillary anterior teeth, described by Broadbent so long ago⁽¹⁾, has become a well-recognized and established cornerstone of our orthodontic literature and has withstood the test of time⁽¹⁻⁵⁾. It is widely quoted in the literature and is accepted as axiomatic to the narrative of normal growth and development. This is the Guidance Theory of Eruption of the maxillary anterior teeth⁽⁶⁾.

From this description it is clear that there is much that can go wrong in this complex scheme of events that may have an effect on the eruption path of the canine. Indeed, Broadbent speculated that because of the long path of eruption taken by the maxillary canine, from close to the floor of the orbit to its final destination – a distance of 22mms – it had a greater chance of going off-course. It clearly requires a relatively small discrepancy in direction or degree of influence of one of the factors involved to malfunction and to undermine this fragile scheme. It was his view that this was the reason that the canine occasionally became palatally displaced⁽¹⁻⁴⁾.

Faced with such a compelling association, the obvious, facile, and simplistic conclusion is to infer that palatally impaction of the canine is also genetically determined and linked to anomalous or missing lateral incisors – a view that is held by the authors of most of these studies⁽³⁻⁶⁾.

The present paper aimed to determine the prevalence, etiology, and clinical diagnosis of impacted maxillary canines in orthodontic patients.

4 PREVALENCE AND ETIOLOGY

Eighty-five per cent of impacted maxillary permanent cuspids are palatal impactions, and 15% are labial impactions. Inadequate arch space and a vertical developmental position are often associated with buccal canine impactions (Figure 2)⁽⁷⁾. If buccally impacted cuspids erupt they do so vertically, buccally and higher in the alveolus. Due to denser palatal bone and thicker palatal mucosa, as well as a more horizontal position, palatally displaced cuspids rarely

erupt without requiring complex orthodontic treatment (Figure 3)⁽⁸⁾. Palatally erupting or impacted maxillary canines occur twice as often in females than males, have a high family association and are 5 times more common in Caucasians than Asians. It is not unusual for maxillary canine impaction to occur bilaterally, although unilateral ectopic eruptions are more frequent^(7–10).

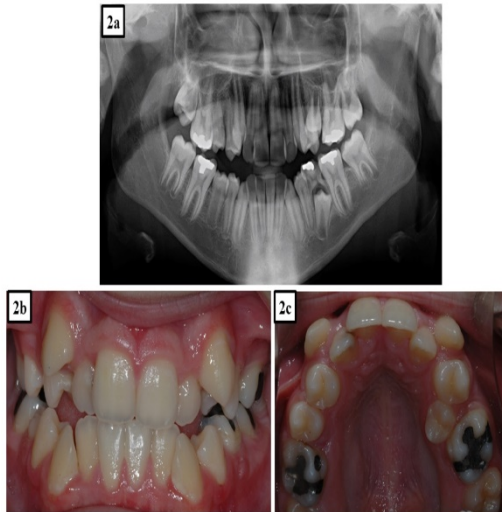


Fig. 2: a-c: Buccally impacted cuspids erupt vertically, buccally and higher in the alveolus

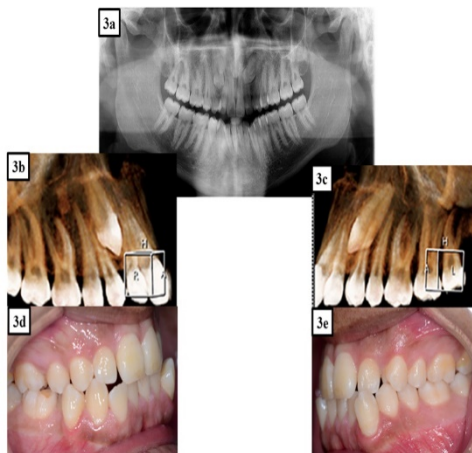


Fig. 3: a-e: Palatally displaced and retained canines. Surgical exposure and orthodontic treatment are necessary for the up righting

Historically, impaction of canines has been associated with a number of factors such as consumption of soft food, supernumerary teeth, abnormal growth of the primordial band in embryonic life, variation in growth of the maxilla or mandible, syphilis, hare lip, cleft palate, endocrine disorders, trauma, premature loss of primary canines and nasal obstruction. There is however no single reported cause

of impaction of canines^(1–4).

The causes for retarded eruption of teeth may be either generalized or localized⁽¹¹⁾.

The generalized causes have been attributed to many diseases, syndromes, and systemic factors.

4.1 Localized causes

The most common causes for canine impactions, however, are usually localized and are a result of any one or a combination of the factors described below.

4.1.1. Tooth size – arch length discrepancy

Crowding was considered to be one of the major causes of impacted maxillary canine, for both buccal and palatal displacements⁽¹²⁾. Association with certain malocclusions such as an Angle Class II, division 2 relationship has been suggested⁽¹³⁾. However, it is unclear and there is a consensus in the literature that arch length deficiency is associated primarily with buccal canine displacement⁽¹⁴⁾. Further, a number of studies have shown that the likelihood of palatally displaced canines is lower when crowding is present⁽¹⁵⁾.

4.1.2. Prolonged retention or early loss of the primary canine

The delayed exfoliation of the primary canine is considered by many authorities, to be the principle etiologic factor for the impaction of the maxillary canine⁽¹⁶⁾. There have been several studies that support this theory and advocate the timely extraction of primary canines to allow spontaneous eruption of the permanent successor⁽¹⁷⁾. However, delayed resorption is probably a result of the ectopic path of eruption rather than the cause of the impaction^(18–20)

4.1.3. Abnormal position of tooth bud and long path of eruption

An etiological influence on maxillary canine displacement has, for a long time, been attributed to the various developmental phases of the tooth germ and the long eruption path⁽¹⁹⁾. permanent canine develops high in the maxilla with calcification commencing 4-12 months post-natally and crown completion at 6-7 years of age. At the age of 2½ years, the tooth germ of the permanent maxillary canine is lying above the first premolar tooth germ. From this position, the maxillary canine has a long and devious path to cover^(20,21). In the three planes of space, the canine travels almost 22mm from its position at the age of 5 years to its position at the age of 15 years⁽²²⁾. Whilst the primary dentition is being carried⁽²³⁾.

It moves down the distal aspect of the lateral incisor during erupt this will often result in closure of a physiological midline diastema, if present⁽²⁴⁾. Displacement from the normal path of eruption most commonly occurs in a palatal direction and this has been suggested to be the cause of the

impaction⁽²⁰⁾.

4.1.4. Presence of alveolar cleft

Tooth abnormalities in children with cleft lip and/ or palate occur more frequently than in the normal population. The congenital absence of the permanent lateral incisor is probably, the most commonly occurring anomaly in these patients^(1,25). However, patients with complete alveolar clefts also have permanent canines in abnormal locations during eruption and are at an increased risk of impaction when compared with the unaffected population. Both the timing of alveolar bone grafting and the presence of lateral incisors are factors that can influence the risk of canine impaction^(1-3,26-28) (Figure 4).

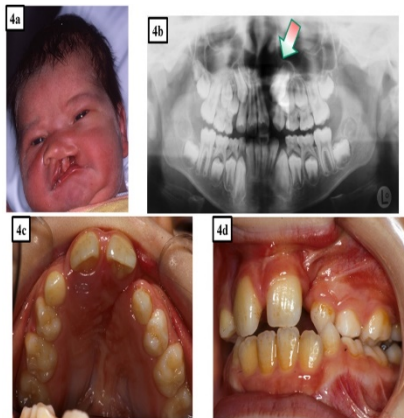


Fig. 4: a-g: Child with cleft, lip and palate left side a-d: patient with complete alveolar cleft have permanent canines in abnormal locations during eruption, impaction of the tooth 23, **e-g:** alveolar bone grafting in the alveolar cleft region. After bone augmentation, it was possible to upright the displaced and retained canine

4.1.5. Guidance theory

Miller and Bass reported that there appeared to be an unusually high prevalence of congenitally missing lateral incisors associated with palatally impacted canines. They suggested that under such circumstances, the permanent canine lacks the guidance normally afforded by the distal aspect of the root of the lateral incisor^(29,30). Miller however, assumed that the root of even an abnormally small lateral incisor, such as a peg shaped lateral incisor, is usually of adequate length to guide the canine along a normal course⁽²⁹⁾

While many researchers support the hypothesis of Miller and Bass that the part played by the lateral incisor, as a guide in the normal eruption of the permanent canine; numerous proponents of the guidance theory have also reported a significantly higher incidence of hypoplastic and peg shaped lateral incisors in patients with palatally displaced canines, when compared with the general population⁽³¹⁾. These authors considered palatal displacement of a canine

to be due to the abnormal adjacent lateral incisor being unable to provide the required guidance for normal canine eruption⁽³¹⁾ (Figure 5).

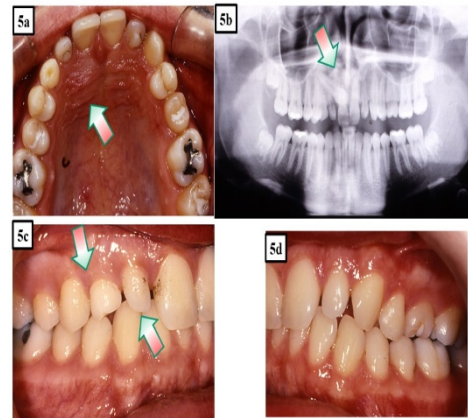


Fig. 5: a-d: Hypoplastic and peg shaped lateral incisors 12 in patients with palatally displaced and retained canines

The explanation given by Becker and his co-workers in 1981; was based on a two-phase development of palatal canine displacement. During the first phase, the canine deviates from the physiologic eruption path in the palatal direction. This is often due to retarded development of hypoplastic maxillary lateral incisors, the roots of which are insufficiently formed to take over the guiding function at the critical time in the eruption of the permanent canine. Furthermore, in cases of incomplete root development and congenital aplasia of the maxillary lateral incisor there is an excess of space in the maxillary apical base. This is the precondition for the canine to be able to leave its labial developmental position and migrate to a palatal position across the roots of the incisors and premolars. Jacoby showed that patients with palatal displacement of their canines exhibited excess space⁽³²⁾.

During the second phase, corrective movements occur with the canine moving into an upright position to fit into the dental arch. In patients with hypoplastic, or peg-shaped lateral I this self-correcting movement will be prevented by the completely developed roots of the lateral incisors, whereas it can still take place if the lateral incisors are congenitally missing⁽¹⁻⁵⁾.

Both Becker et al and Brin et al recorded peg-shaped lateral incisors approximately three times as often a congenital aplasia of those teeth in patients with palatal canine displacement^(15,33). Peck and co-workers also reported a significant increase in the frequency of peg-shaped lateral incisors but found no statistical significance in the co-workers^(34,35).

Frequency of agenesis of the maxillary lateral incisors in association with palatally displaced canines. Becker and his

co-workers even suggest that aplasia was more likely to occur on the contra-lateral side, whereas hypoplastic and peg-shaped laterals are more likely to cause palatal displacement of the adjacent canine⁽¹⁻⁴⁾.

Thus, it is evident that the permanent lateral incisors exert a powerful local influence. However, in the majority of the cases, palatally displaced canines are found adjacent to developed incisors^(34,35). The guidance theory offers no explanation for this; hence recourse to the theory of genetic origin is necessary which is supported by the increased risk of palatal canine displacement in association with aplasia or impaction of other teeth⁽¹⁻⁵⁾.

As a second possibility, the genetic etiology may be due to a disturbance in a cogenetically critical zone for example, in the fusion area between the palatal shelves and the median nasal process. However, it is difficult to explain, why the most pronounced manifestation of this disturbance, i.e., aplasia of the lateral incisor, is not significantly greater adjacent to a palatally displaced canine⁽³⁶⁾.

4.1.6. The genetic theory

The theory of “genetic origin” is based on the observation that palatal displacement of a canine rarely occurs as an isolated symptom but is generally accompanied by genetically determined tooth anomalies such as hypoplasia and/or agenesis of the maxillary lateral or the aplasia of other teeth. According to the literature, this is because the palatal displacement of a canine is due to complex genetically determined tooth anomalies which are ultimately aplasia-oriented and are in turn due to disturbances of dental development or of the dental lamina⁽³⁷⁾.

The possibility of there being an autosomal inherited dominant trait with variable expression and incomplete penetrance is under discussion⁽³⁸⁾. Family studies of patients with hypodontia have revealed mutations in the MSX1/MSX2 homeodomains. These mutations are expressed in dental tissues at the onset of tooth development and are held responsible for the developmental disturbance⁽³⁸⁾.

Besides tooth agenesis, tooth shape anomalies such as hypoplastic or peg-shaped teeth, tooth impactions and retarded tooth mineralization are regarded as co-variables genetic developmental anomaly. According to Peck and co-workers⁽³⁴⁾ it is not only the association with genetically determined anomalies but also the frequent bilateral occurrence, significant gender related differences, the cumulation of symptoms among affected families, and significant inter-population differences that suggest a genetic origin for palatal displacement of maxillary canine⁽³²⁾.

4.1.7. Ankylosis

Ankylosis can be defined as an interruption in the rhythm of eruption and reportedly remains one of the major complications associated with impacted teeth in children.

Unerupted permanent teeth may become ankylosed by inostosis of enamel (Figure 6). The process follows the irritation of the follicular or periodontal tissue, resulting from chronic infection. The close association of an infected apex of a primary tooth to an unerupted permanent tooth may give rise to the process⁽³⁹⁾. subsequently resorb, and bone, or coronal cementum may be deposited in its place. This results in rigid fixation of the tooth in the unerupted position. In other cases, extensive bony ankylosis of the primary tooth may prevent its normal exfoliation as well as eruption of the permanent successor⁽⁴⁰⁾ (Figure 7).

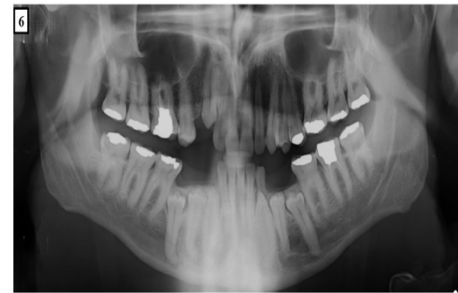


Fig. 6: Ankylosis of some teeth in both jaws was the cause of their retention

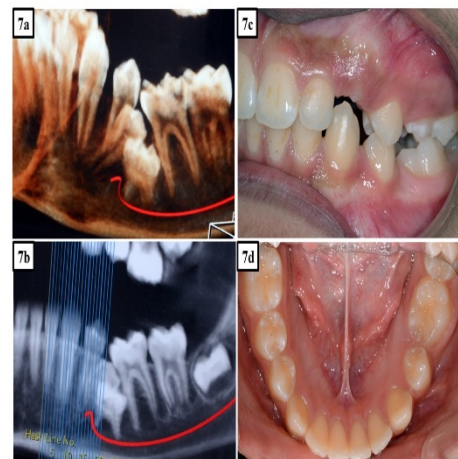


Fig. 7: a-d: Ankylosis of the primary molar 75 was the cause of the retention of the tooth 35

4.1.8. Formation-Follicular disturbance and cyst or neoplasm

Normal activity of the dental follicle is intimately involved in the direction of tooth eruption. Specific cellular changes occur in and around the follicle when a tooth erupts (Marks

and Cahill 1987). Disturbance of the follicle may produce an abnormal path of eruption of the canine⁽³⁹⁾.

Frequently primary maxillary canines are affected by caries (usually distally) and these lesions are left untreated in the majority of children with the belief that these teeth are about to shed⁽⁴¹⁾. In such cases, the tooth loses its vitality when the caries reaches pulp, and a chronic periapical area develops. The soft tissue lesion is a potent cause of deflection of the path of the developing unerupted permanent canine. In rare instances, it may develop into a radicular cyst, or it may initiate cystic changes in the follicle of the canine, both of which alter the path of eruption of the canine⁽⁴¹⁾. Likewise, a tumor in the region acts as a physical barrier and can thus disrupt the normal path of eruption of the canine (Figure 8).

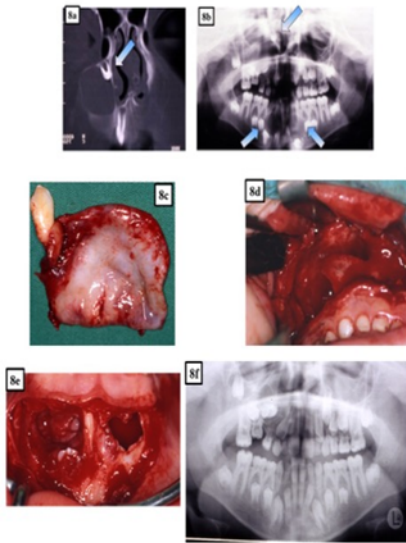


Fig. 8: a-f: a, b: Panoramic X-ray and CT show enormous cyst. Cyst development in the maxilla and mandible was the cause of displacement and future retention. c-e: Cystectomy of the maxillary Cyst; Cystotomy of the mandibular cyst. f: OPG a few months after the surgical treatment. There was a spontaneous up righting of the teeth in the lower jaw.

4.1.9. Dilaceration of the root or trauma

The term dilaceration which was first used by Tomes in 1848 is defined as a deviation, or bend in the linear relationship of a crown of a tooth to its root⁽⁴¹⁾. Tooth dilaceration can present in a variety of ways including non-eruption of the affected tooth, prolonged retention of the primary predecessor, and apical fenestration of the labial cortical plate or it can be asymptomatic⁽⁴⁰⁾. The most widely accepted cause of dilaceration is mechanical trauma to the primary predecessor tooth results in dilaceration of the developing succedaneous permanent tooth (Figure 9). Any form of trauma during the developmental stages of the permanent canine can cause dilaceration of the tooth and

subsequently prevent its eruption in the oral cavity. Also, trauma to the anterior region of the dentition; may lead to aberrations in the path of eruption of the canines which may result in their impaction, or ectopic eruption⁽¹⁵⁾.

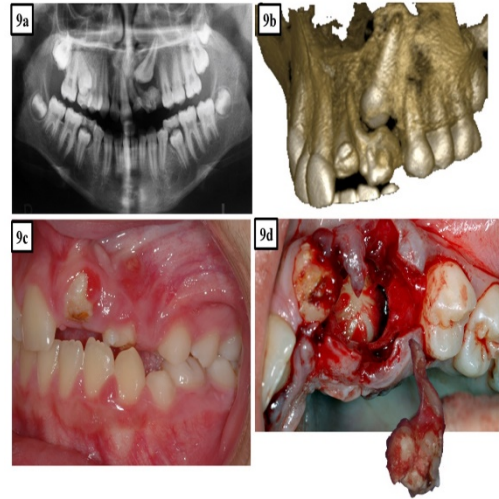


Fig. 9: a-d: Trauma to the anterior region of the dentition; lead to aberrations in the path of eruption of the canines which result in their impaction

4.1.10. Other factors which reportedly may contribute to dilaceration include

- (a) scar formation,
- (b) developmental anomalies of the primary tooth germ,
- (c) facial clefting
- (d) advanced root canal infections
- (e) ectopic development of the tooth germ and lack of space
- (f) the effect of anatomic structures such as, the cortical bone of the maxillary sinus, the mandibular canal, or the nasal fossa which may deflect the epithelial diaphragm,
- (g) the presence of a cyst, tumour, or odontogenic hamartoma such as, an odontoma and a supernumerary tooth
- (h) orotracheal intubation and laryngoscopy
- (i) mechanical interference with eruption
- (j) tooth transplantation
- (k) extraction of primary teeth and
- (l) hereditary factors
- (x) Idiopathic factors, including primary failure of eruption

4.2 Generalized causes

The most common generalized causes are described below^(26-29,42).

4.2.1. Hypopituitarism

Hypopituitarism is characterized by a deficiency in the secretion of the growth hormone which causes delayed development and eruption of the dentition. Both the primary and permanent dentitions are affected and in severe cases, the primary dentition may be retained throughout the patient's life while the permanent teeth which although developed, remain unerupted^(1,2) (Figure 10).

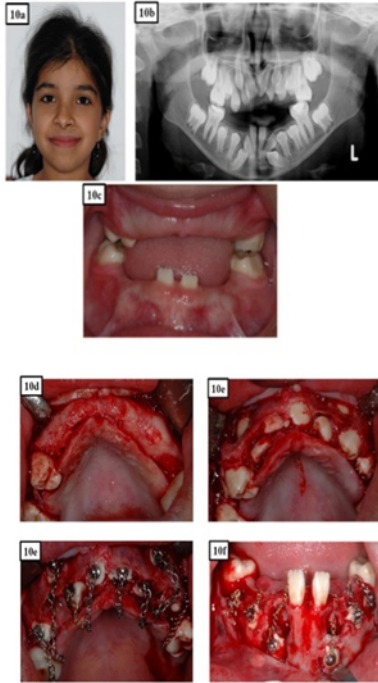


Fig. 10: a-f: 14-year-old patient with deficiency in the secretion of the growth hormone. The Extraction of the retained deciduous teeth did not lead to the eruption of the permanent teeth, multiple retention

4.2.2. Hypothyroidism

Delayed tooth eruption has also been observed in hypothyroidism. An extreme manifestation of this condition is cretinism which involves severe delays at all stages of development of the dentition⁽¹⁾.

4.2.3. Cleidocranial dysostosis

This condition is characterized by a partial or total absence of the clavicles, large fontanels and open sutures. There is a developmental delay affecting the entire dentition. Hypodontia or conversely, a number of supernumerary teeth may also occur⁽⁷⁾.

4.2.4. Down syndrome

Down syndrome is a congenital anomaly in which delayed eruption of the dentition is found and the eruption sequence deviates from the normal pattern⁽⁸⁾.

4.2.5. Achondroplasia

This is a condition characterized by deficient growth of the extremities, the cranial base and the maxilla. Delayed development of the dentition is a feature of this disease⁽⁷⁾.

4.2.6. Hypovitaminosis (A or D)

Long term hypovitaminosis may also have a retarding effect on the eruption of teeth^(1,2).

4.2.7. Amelogenesis imperfecta

Inherited enamel defects that occur in the absence of a generalized syndrome are collectively designated as amelogenesis imperfecta. This condition generally causes a delayed eruption of both the dentitions⁽⁴³⁾ (Figure 11).

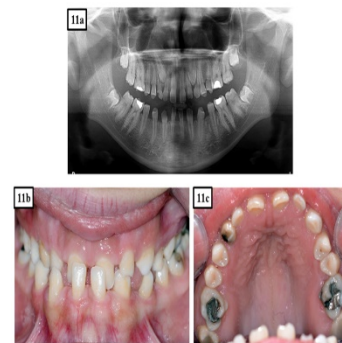


Fig. 11: a-c: Light amelogenesis imperfecta with ectodermal dysplasia; a displacement and retention of the maxillary canines

4.2.8. Osteopetrosis

Osteopetrosis shows an increased bone density and a characteristic delay in, or failure of eruption of teeth.⁽⁴⁾ The etiology of primary failure of eruption is incompletely understood. However, it has been suggested that either the blood flow or the metabolism of the periodontal ligament are altered in this condition. Also, primary failure of eruption could be related to some sort of genetic disturbance with varying penetrance and expressivity. This unknown cause of failure eruption could play a role in the impaction of canines⁽⁴⁴⁾.

5 DIAGNOSIS

Early detection of impacted maxillary canines may reduce treatment time, complexity, complications, and cost. Ideally, patients should be examined by the age of 8 or 9 years to determine whether the canine is displaced from a normal position in the alveolus and assess the potential for impaction⁽¹⁾. The clinician can investigate the presence and position of the cuspid using 3 simple methods: visual inspection, palpation, and radiography.⁽³³⁾

5.1 Visual Inspection

Clinical signs that may indicate ectopic or impacted succedaneous cuspids include lack of a canine bulge in the buccal sulcus by the age of 10 years, over retained primary cuspids, delayed eruption of their permanent successor and asymmetry in the exfoliation and eruption of the right and left canines^(1,2). Primary cuspids that are retained beyond the age of 13 years and have no significant mobility strongly indicate displacement and impaction of permanent canines. Although Power and Short⁽⁷⁾ assert that the maxillary canine is late in its eruption sequence if it has not emerged by the age of 12.3 years in females and 13.1 years in males, correlation between chronological and dental ages is poor and overall dental development must be considered when investigating delayed canine eruption⁽¹⁻³⁾.

Although distal crown tip on the maxillary lateral incisors is common in the mixed dentition stage before eruption of the maxillary canines, an exaggerated distally tipped incisor should increase suspicion of a mesially deflected and palatally impacted canine⁽⁴⁾ (Figure 12)

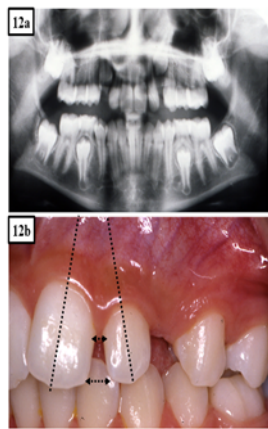


Fig. 12: a, b: Distally tipped lateral incisor should increase suspicion of amesially deflected and palatally impacted canine

In these cases, the lateral incisor crown may be tipped distally because the impacted cuspid is exerting force on the distal aspect of the lateral incisor root. Such palatal impactions can cause the lateral incisor to rotate as well. Retroclined lateral incisors can also occur when buccally directed forces cause the root to tip labially and the crown to tip palatally⁽¹⁻⁵⁾.

In severe cases, the central incisor may also be affected, and its crown may become malpositioned⁽²⁾.

5.2 Palpation

Palpation of the buccal and lingual mucosa, using the index fingers of both hands simultaneously, is recommended to assess the position of the erupting maxillary canines. Eruption time of a maxillary canine varies from 9.3 to 13.1

years. Because canines are palpable from 1 to 1.5 years before they emerge, the absence of the canine bulge after the age of 10 years is a good indication that the tooth is displaced from its normal position, and ectopic eruption or impaction of the maxillary cuspids is possible⁽¹⁻⁴⁾. Asymmetries in the alveolar process are not considered significant in children younger than 10 years, and differences in bilateral palpation could be due to vertical differences in eruption rates at young ages. However, in patients older than 10 years, an obvious palpable bilateral asymmetry could indicate that one of the permanent cuspids is impacted or erupting ectopically.^(8,9)

5.3 Radiography

Radiographs are indicated when canine bulges are not present, right and left canine development and eruption is asymmetrical, occlusal development is advanced and there are no palpable bulges indicating the presence of the cuspids in the alveolar process and the lateral incisor is delayed in eruption, malpositioned, or has a pronounced labial or palatal inclination in relation to the adjacent central incisor⁽²⁾. Accurate radiographs are critical for determining the position of impacted canines and their relation to adjacent teeth, assessing the health of the neighbouring roots, and determining the prognosis and best mode of treatment^(1,2). The conventional radiographic techniques that are used are – intraoral periapical radiograph (IOPA), occlusal radiograph, orthopantomograph (OPG) which suffice for simple cases of impaction but for difficult cases not only is correct diagnosis required but also precise location, accurate assessment of the relation of the adjacent teeth and the surrounding anatomic structures, for the above stated procedures advanced radiography is useful in planning the treatment. The advanced radiographic techniques include computed tomography (CT), cone beam computed tomography (CBCT) and transtomography. Intra oral periapical radiographs (IOPA) A single periapical film provides the clinician with a two-dimensional representation of the dentition.⁽¹⁻⁵⁾ In other words, it would relate the canine to the neighbouring teeth both mesiodistally and superoinferiorly⁽⁸⁾. To evaluate the position of the canine buccolingually, a second periapical film should be obtained by one of the following methods –

a. Tube-shift technique or Clark's rule - Two periapical films are taken of the same area, with the horizontal angulation of the cone changed when the second film is taken. If the impacted canine in question moves in the same direction as the cone, it is lingually positioned. If the canine moves in the opposite direction, it is situated closer to the source of radiation and is therefore buccally located.

b. Buccal-object rule - If the vertical angulation of the cone is changed in two successive periapical films, the buccal object will move in the direction opposite the source of radiation. On the other hand, the lingual object will move in the same direction as the source of radiation. The basic

principle of this technique deals with the foreshortening and elongation of the images of the films⁽⁴⁵⁾.

5.4 Occlusal Radiographs

Occlusal films also help determine the buccolingual position of the impacted canine in conjunction with the periapical films, provided that the image of the impacted canine is not superimposed on the other teeth⁽⁴⁵⁾.

In a study conducted by ERICSON and KUROOL they concluded that the orthopantomograph was found to be unreliable for the purposes of

1. Determining the position of a misplaced canine in the dental arch or to the adjacent lateral incisors, and

2. Showing resorption on adjacent teeth⁽⁴⁶⁾

Its value lies in giving a panoramic view of the mouth before starting orthodontic treatment. Bayesian network analysis can be applied to the OPG to evaluate the position and judge the degree of canine impaction. In Bayesian network analysis the parameters which are taken into account are alpha angle which is the angle measured between the long axis of the impacted canine and the midline, d-distance: distance between the canine cusp tip and the occlusal plane (from the first molar to the incisal edge of the central incisor), and s-sector: sector where the cusp of the impacted canine is located (sector 1, between the midline and the axis of the central incisor; sector 2, between the axes of the central incisor and the lateral incisor; or sector 3, between the axes of the lateral incisor and the first premolar)⁽⁴⁷⁾.

5.5 Orthopantomograph (OPG)

Panoramic radiography is a fundamental examination which gives an overview but does not permit precise localization of an impacted canine in three-dimensional space^(1–6). In the above shown OPG, the alpha angle is 55°, distance (D) is 21mm and the impacted canine is in sector 2. Hence it is an unfavourable impaction. Computed Tomography (CT) In order to minimize the risk of root resorption of permanent teeth due to impacted canine, an early detection of abnormal contact between the malpositioned canine and the roots of permanent incisors is essential. In this respect, conventional radiographs have proved inadequate. Both conventional radiology panoramic and intra-oral only suggest possible contact between an impacted canine and the permanent incisor when it is located in a true palatal or buccal position relative to the root of adjacent teeth. Several authors have suggested the use of CT in these cases because it is known to be superior to other radiographic methods in showing bony lesions as well as provides accurate 3D localization of canines⁽⁴⁸⁾. The relative introduction of spiral CT has significantly improved scanning by reducing the examination time and minimizing movement artefacts. Multiple transaxial images can be retrospectively reviewed

from a single spiral CT scan data set with varying degrees of overlap, thus optimizing multiplanar reformations with better longitudinal resolution⁽⁴⁹⁾. Tomography offers greater diagnostic yield, but it is difficult to perform, entails high radiation exposure, and often fails to demonstrate minimal root resorption. The major limitation of CT is radiation risk which is especially greater in children⁽⁴⁸⁾. The average range of radiation exposure for maxilla is 1,031-1,420 μSv ⁽⁵⁰⁾

5.6 Cone Beam Computed Tomography (CBCT)

The most recognized need for CBCT imaging in orthodontics is that of impacted canine evaluation. CBCT imaging is precise in determining not only the labial/lingual relationship but also a more exact angulation of the impacted canine. These 3D images are beneficial in determining the proximity of adjacent incisor and premolar roots, which can be invaluable in determining the ease of uncovering and bonding and the vector of force that should be used to move the tooth into the arch with a lesser chance of damage to adjacent tooth^(51–53) (Figures 13 and 14). It also has the potential of providing clear images of highly contrasted structures and is useful in evaluating bone. CBCT scanners are based on volumetric tomography, using a 2D extended digital array providing an area detector. This is combined with a 3D x-ray beam⁽⁴⁸⁾. The advantages that the CBCT offers over conventional tomography are: X-ray beam limitation, image accuracy, rapid scan time, dose reduction, display modes unique to maxillofacial imaging and reduced image artefact. The average radiation dose in CBCT is 36.9 – 50.3 μSv , that is significantly reduced up to 98% compared to conventional CT⁽⁵¹⁾. The analysis that is novel and unique to CBCT and helps in aid clinicians to quickly estimate the difficulty of treatment involving impacted canines, without having to do multiple measurements of angles and distances, to relay the approximate treatment plan to the patient. KPG analysis uses a KPG index which is a grid like scale was devised of the three different views (x, y and z) in order to grade the difficulty of impaction and the potential efficacy of treatment. What makes this analysis unique is the x axis which helps in scoring the canine in the x axis. Depending on its anatomical location, the cusp tip and the root tip are each given a number on a 0–5 scale on the three separate images taken before treatment. The sum of both cusp tip and root tip scores in the three views would decide the anticipated difficulty of treatment, classified as easy, moderate, difficult, and nearly impossible. Scores in the range 0–9 fall into the category of easy; 10–14 are moderate; 15–19 are difficult; and 20 and above are extremely difficult^(1–10,51).

5.7 Transtomography

Computed tomography and cone beam computed tomography come with a drawback that free-standing conventional tomographic equipment is not readily available outside

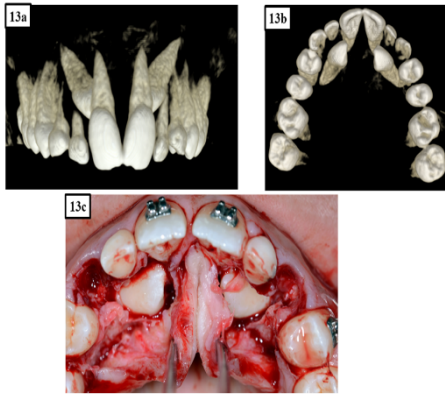


Fig. 13: a, c: CBCT shows the exact position of the displaced and impacted canines

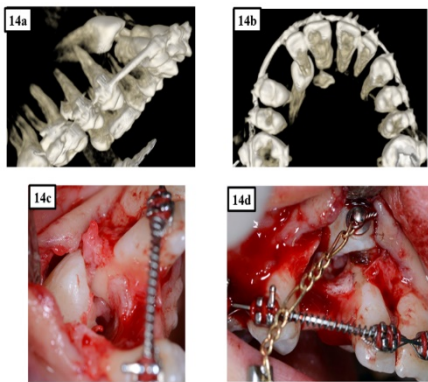


Fig. 14: a, d: CBCT shows the exact position of the displaced and impacted canine on the right side of the maxilla, a resorption of the lateral incisor. The CBCT enables the correct application of the forces for the up righting of the impacted tooth without major damage to the lateral incisor

specialist departments. A few panoramic units on the market are capable of exposing true tomographic images. Such units are dual-purpose units with separate programs and functions for panoramic radiography and tomography⁽¹⁻⁹⁾. Transtomography uses a well-established scanning method employing a narrow beam i.e., so called orthoradiographic technique or parallel scanning that is used with several existing digital panoramic units to expose. By using a narrow beam, we increase the magnification and thus minimize the unsharpness but layer thickness becomes very wide⁽⁵⁴⁾. To this simple translational scanning technique one more movement i.e., pendular movement is also added to decrease the layer thickness. But the problem of blurred images still exists to a certain depth⁽¹⁸⁾. Transtomography is useful for canine impactions that are not very highly placed and most useful in knowing the relationship between the impacted canine and the root resorption of the lateral incisor. The value of this useful technology is in the series of options

available for exposure. It is thus possible to expose transtomographs employing different tomographic angles, 25°, 10°, 5°, 3.4°, 1.7° and 0.9°, creating nominal layer thicknesses of 1 mm, 3 mm, 6 mm, 9 mm, 18 mm and 36 mm. It is possible to expose cross-sectional or longitudinal transtomographs of any part of the jaws including the temporomandibular joints. Such transtomographs may portray the upper or the lower jaw, or both. It is possible to combine four cross sectional transtomographs or three cross-sectional and one longitudinal transtomograph in one composite image^(54,55).

The advantages of this technique over are conventional tomography are low radiation, low cost and the easy availability and use of routine equipment⁽⁵⁴⁾.

6 DISCUSSION

Impaction of maxillary and mandibular canines is a frequently encountered clinical problem, the treatment of which usually requires an interdisciplinary approach. Surgical exposure of the impacted tooth and the complex orthodontic mechanisms that are applied to align the tooth into the arch may lead to varying amounts of damage to the supporting structures of the tooth, not to mention the long treatment duration and the financial burden to the patient. Hence, it seems worthwhile to focus on the means of early diagnosis and interception of this clinical situation. In the presentation, an overview of the incidence and sequelae, as well as the surgical, periodontal, and orthodontic considerations in the management of impacted canines is presented.

The management of impacted canines is important in terms of aesthetics and function. Clinicians must formulate treatment plans that are in the best interest of the patient, and they must be knowledgeable about the variety of treatment options. When patients are evaluated and treated properly, clinicians can reduce the frequency of ectopic eruption and subsequent impaction of the maxillary canine. This allows for complete control in efficient correction the impaction and for avoidance of damage to adjacent teeth. Careful selection of surgical and orthodontic techniques is essential for the successful alignment of impacted canine^(1-10,33).

The prevalence of maxillary canine impaction is significant and the frequency increases with other genetically associated dental anomalies.⁽⁵⁶⁾

Ericson and Kurok found that radiographic supervision of maxillary canine eruption usually is not necessary before 10 years of age.^(57,58)

6.1 Patients younger than 10 years of age

For patients younger than 10 years of age, the clinician should suspect that palatal impaction may occur in the future if either of the following two situations exists:

(i) there is a family history of palatally impacted maxillary canine in particular, but also small, peg-shaped, or missing

lateral, or incisors or other missing teeth

(ii) The patient has small, peg shaped, or missing lateral incisors⁽³³⁾

6.2 Patients older than 10 years of age

For patients older than 10 years of age, the clinician should suspect that impaction may have occurred if any of the following three features are observed:

(i) asymmetry on palpation, or a pronounced difference in the eruption of canines between the left and right side, i.e., one canine is in poor position and the other is in a favourable position,⁽⁵⁹⁾

(ii) the canines cannot be palpated, and occlusal development is advanced suggesting abnormal paths of eruption, i.e., both canines are in poor positions, and

(iii) the lateral incisor is proclined and tipped distally, which may indicate a labial impaction of the canine. Though distal tipping alone is not always associated with any eruption disturbance and may be the well-recognized “ugly duckling” stage of normal dental development.^(58–64)

The clinician should also suspect that impaction may be present if there is an abnormality in the magnification of the canine on the panoramic radiograph. In addition, an impaction should be suspected if on the panoramic radiograph, the canine overlaps either the lateral or central incisor^(59–64).

Multidisciplinary approach for guiding the impacted canine gives predictable results. Careful diagnosis is critical, and it is crucial that every patient should be managed with tailor-made treatment plan with sound scientific backing as there is no ‘cook book’ approach for all cases. The development of treatment and mechanical plans must be based on the careful analysis of the clinical situation and identification of the correct force system is necessary to obtain the desired tooth movement.

The management of an impacted canine is a complex procedure requiring a multidisciplinary approach. The clinicians should communicate with each other to provide the patient with an optimal treatment plan based on a scientific rationale.

7 CONCLUSIONS

- The unambiguous nature of the data suggests that both buccally and palatally impacted canines have similar etiology and mechanism of impaction.
- Diagnosis of an impacted maxillary canine can be done as early as 8 years of age therefore screening of patients to detect an early impaction could be done at this age.
- Visual inspection and digital palpation can frequently aid in the diagnosis and determination of the location of an impacted maxillary canine.
- Radiographs utilizing the vertical tube shift principle were found to have a higher capability of diagnosing, and a greater degree of accuracy in determining

the position, of an impacted maxillary canine when compared to the horizontal tube shift principle.

7.1 Financial support and sponsorship

Nil

7.2 Conflicts of interest

None declared

REFERENCES

- 1) Abu-Hussein M, Watted N, Hussien E, Proff P, Watted A. Maxillary Impacted Canines. Clinical Review. *International Journal of Dental and Medical Sciences Research*. 2017;1(6):10–26. Available from: <https://www.ijdmr.com/wp-content/uploads/2017/11/C161026.pdf>.
- 2) Abu-Hussein M, Watted N, Proff P, Watted A. Clinical Management of Bilateral Impacted Maxillary Canines. *SRL Dentistry*. 2017;1(1):001–007. Available from: https://www.researchgate.net/publication/316940541_Clinical_Management_of_Bilateral_Impacted_Maxillary_Canines.
- 3) Watted N, Hussein E, Proff P, Dodan A, Muhamad AH. Surgery of Labially Impacted Canine & Orthodontic Management - A Case Report. *Open Journal of Dentistry and Oral Medicine*. 2017;5(1):1–6. Available from: <https://doi.org/10.13189/ojdom.2017.050101>.
- 4) Borbély P, Watted N, Dubovská I, Hegedűs V, Abu-Hussein M. Interdisciplinary Approach in the Treatment of Impacted Canines – Review. *International Journal of Maxillofacial Research*. 2015;1(2):116–137. Available from: https://www.researchgate.net/publication/283485603_Interdisciplinary_Approach_in_the_Treatment_of_Impacted_Canines_-_Review.
- 5) Watted N, Hussein E, Proff P, Dodan A, Muhamad AH. Surgery of Labially Impacted Canine & Orthodontic Management - A Case Report. *Open Journal of Dentistry and Oral Medicine*. 2017;5(1):1–6. Available from: <https://doi.org/10.13189/ojdom.2017.050101>.
- 6) Watted N, Proff P, Bill J, Teusher T, Reiser V. Chirurgisches Management verlagertes Zähne unter besonderer Berücksichtigung der Eckzähne. *Kieferorthopädie*. 2011;3:207–225. Available from: <https://www.quintessence-publishing.com/deu/en/article/834257/kieferorthopaedie/2011/03/chirurgisches-management-verlagertes-zaehne-unter-besonderer-beruecksichtigung-der-eckzaehne>.
- 7) Abu-Hussein M, Watted N, Watted A, Abu-Hussein Y, Yehia M, Awadi O, et al. Prevalence of tooth agenesis in orthodontic patients at Arab population in Israel. *International Journal of Public Health Research*. 2015;3(3):77–82. Available from: <https://www.aaup.edu/sites/default/files/Publications/41-Prevalence%20of%20Tooth%20Agensis%20in%20Orthodontic%20-%20%D7%A2%D7%95%D7%AA%D7%A7.pdf>.
- 8) Watted N, Abu-Hussein M, Awadi O, Watted M, Watted AL. Clinical study of impacted maxillary canine in the Arab population in Israel. *International Journal of Public Health Research*. 2014;2(6):64–70. Available from: <https://www.aaup.edu/sites/default/files/Publications/33-Clinical%20study%20of%20impacted%20maxillary%20canine%20in%20the.pdf>.
- 9) Watted N, Abu-Hussein M, Awadi O, Watted M, Watted AL. Clinical study of impacted maxillary canine in the Arab population in Israel. *International Journal of Public Health Research*. 2014;2(6):64–70. Available from: <https://www.aaup.edu/sites/default/files/Publications/33-Clinical%20study%20of%20impacted%20maxillary%20canine%20in%20the.pdf>.
- 10) Abu-Hussein M, Watted N, Azzaldeen A, Yehia M, Awadi O. Prevalence of missing lateral incisor agenesis in an orthodontic Arabs population in Israel (Arab48). *International Journal of Public Health Research*. 2015;p. 1–7. Available from: <https://www.aaup.edu/publication/nezar.watted/article/prevalence-missing-lateral-incisor-agenesis-orthodontic-arabs-population-israelarab48>.

- 11) Bishara SE, Kommer DD, Mcneil MH, Montagano LN, Osterle LJ, Youngquist HW. Management of impacted canines. *American Journal of Orthodontics*. 1976;69(4):371–387. Available from: [https://doi.org/10.1016/0002-9416\(76\)90207-4](https://doi.org/10.1016/0002-9416(76)90207-4).
- 12) Hitchin AD. The impacted maxillary canine. *Dental practitioner and dental record*. 1951;2(4):100–103. Available from: <https://pubmed.ncbi.nlm.nih.gov/14896717/>.
- 13) Kettle MA. Treatment of the unerupted maxillary canine. *Transactions of the British Society for the Study of Orthodontics*. 1957;p. 74–84. Available from: <https://archive.org/details/s6867id1324640/page/74/mode/2up>.
- 14) Zilberman Y, Cohen B, Becker A. Familial trends in palatal canines, anomalous lateral incisors, and related phenomena. *The European Journal of Orthodontics*. 1990;12(2):135–139. Available from: <https://doi.org/10.1093/ejo/12.2.135>.
- 15) Brin I, Solomon Y, Zilberman Y. Trauma as a possible etiologic factor in maxillary canine impaction. *American Journal of Orthodontics and Dentofacial Orthopedics*. 1993;104(2):132–137. Available from: [https://doi.org/10.1016/S0889-5406\(05\)81002-9](https://doi.org/10.1016/S0889-5406(05)81002-9).
- 16) Newcomb MR. Recognition and interception of aberrant canine eruption. *Angle Orthodontist*. 1959;29(3):161–168. Available from: <https://meridian.allenpress.com/angle-orthodontist/article/29/3/161/55087/Recognition-And-Interception-Of-Aberrant-Canine>.
- 17) Baccetti T, Franchi L, De Lisa S, Giuntini V. Eruption of the maxillary canines in relation to skeletal maturity. *American Journal of Orthodontics and Dentofacial Orthopedics*. 2008;133(5):748–751. Available from: <https://doi.org/10.1016/j.ajodo.2007.10.031>.
- 18) Andreasen JO, Petersen JK, Laskin DM. Textbook and Colour Atlas of Tooth Impactions: Diagnosis and Treatment. 1st ed. and others, editor;Munksgaard. 1997. Available from: <https://www.amazon.in/Textbook-Colour-Atlas-Tooth-Impactions/dp/8716106938>.
- 19) Impacted canines. Etiology, diagnosis, and orthodontic management. *Journal of Pharmacy and Bioallied Sciences*. 2012;4(Suppl 2):S234–S238. Available from: <https://doi.org/10.4103/0975-7406.100216>.
- 20) Bishara SE. Clinical management of impacted maxillary canines. *Seminars in Orthodontics*. 1998;4(2):87–242. Available from: [https://doi.org/10.1016/S1073-8746\(98\)80006-6](https://doi.org/10.1016/S1073-8746(98)80006-6).
- 21) Lappin MM. Practical management of the impacted maxillary cuspid. *American Journal of Orthodontics*. 1951;37(10):769–778. Available from: [https://doi.org/10.1016/0002-9416\(51\)90048-6](https://doi.org/10.1016/0002-9416(51)90048-6).
- 22) Coulter J, Richardson A. Normal eruption of the maxillary canine quantified in three dimensions. *The European Journal of Orthodontics*. 1997;19(2):171–183. Available from: <https://doi.org/10.1093/ejo/19.2.171>.
- 23) Ferguson JW. Management of the unerupted maxillary canine. *British Dental Journal*. 1990;169:11–17. Available from: <https://doi.org/10.1038/sj.bdj.4807250>.
- 24) Moss JP. Autogenous transplantation of maxillary canines. *The Journal of Oral Surgery*. 1968;26(12):775–783. Available from: <https://pubmed.ncbi.nlm.nih.gov/5247087/>.
- 25) Muhamad A. Cleft lips and palates: the roles of specialists. *Minerva Pediatrics*. 2011;63(3):227–232. Available from: <https://pubmed.ncbi.nlm.nih.gov/21654602/>.
- 26) Muhamad AH. Genetic Basis of Dental Disorders, Why Teach Genetics? . *Global Journal of Medical and Clinical Case Reports* . 2021;1(1):005–009. Available from: https://www.researchgate.net/publication/352038712_Genetic_Basis_of_Dental_Disorders_Why_Teach_Genetics_Glob_J_Clin_Medical_Cas_Rep.
- 27) Abu-Hussein M, Watted N, Hegedús V, Borbély P, Azzaldeen A. Human genetic factors in non-syndromic cleft lip and palate: An update. *International Journal of Maxillofacial Research*. 2015;1(3):1–17. Available from: <https://www.aaup.edu/sites/default/files/Publications/32-Human%20genetic%20factors%20in%20nonsyndromic%20cleft%20lip%20and%20palate%20An%20update.pdf>.
- 28) Watted A, Watted N, Abu-Hussein M. Multidisciplinary Treatment in Cleft Lip and Palate Patients International Journal of Dental Research and Oral Health. *International Journal of Dental research and Oral Health*. 2020;2(1):1–12. Available from: https://www.researchgate.net/publication/343041284_Multidisciplinary_Treatment_in_Cleft_Lip_and_Palate_Patients_International_Journal_of_Dental_Research_and_Oral_Health.
- 29) Miller BH. The influence of congenitally missing teeth on the eruption of the upper canine. In: *Dental practitioner and dental record*;vol. 14. 1963;p. 497–504.
- 30) Bass TB. Observations on the misplaced upper canine tooth. *Dental practitioner and dental record*. 1967;18:25–33. Available from: <https://pubmed.ncbi.nlm.nih.gov/5235604/>.
- 31) Baccetti T. A controlled study of associated dental anomalies. *Angle Orthodontist* . 1998;68(3):267–274. Available from: <https://pubmed.ncbi.nlm.nih.gov/9622764/>.
- 32) Jacoby H. The etiology of maxillary canine impactions. *American Journal of Orthodontics*. 1983;84(2):125–132. Available from: [https://doi.org/10.1016/0002-9416\(83\)90176-8](https://doi.org/10.1016/0002-9416(83)90176-8).
- 33) Becker A. The orthodontic treatment of impacted teeth. 2nd ed. Informa Healthcare UK Ltd. 2007.
- 34) Peck S, Peck S, Kataja M. Sense and nonsense regarding palatal canines. *Angle Orthodontist*. 1995;34(2):99–102. Available from: <https://pubmed.ncbi.nlm.nih.gov/8526285/>.
- 35) Becker A. In defense of the guidance theory of palatal canine displacement. *Angle Orthodontist*. 1995;65(2):95–98. Available from: <https://pubmed.ncbi.nlm.nih.gov/7785811/>.
- 36) Svinhufvud E, Myllärniemi S, Norio R. Dominant inheritance of tooth malpositions and their association to hypodontia. *Clinical Genetics*. 1988;34(6):373–381. Available from: <https://doi.org/10.1111/j.1399-0004.1988.tb02895.x>.
- 37) Basdra EK, Kiokpasoglou M, Stellzig A. The class II division 2 craniofacial type is associated with numerous congenital tooth anomalies. *European Journal of Orthodontics*. 2000;22(5):529–535. Available from: <https://doi.org/10.1093/ejo/22.5.529>.
- 38) Vastardis H, Karimbux N, Guthua SW, Seidman JG, Seidman CE. A human MSX1 homeodomain missense mutation causes selective tooth agenesis. *Nature Genetics*. 1996;13:417–421. Available from: <https://doi.org/10.1038/ng0896-417>.
- 39) Gorlin RJ, Goldman HM. Thoma's oral pathology. 6th ed.. 1970.
- 40) Shafer WG, Hine MK, Levy BM. A Textbook of Oral Pathology. 4th ed. Philadelphia, PA, Saunders. 1983.
- 41) Becker A, Chaushu S. Dental age in maxillary canine ectopia. *American Journal of Orthodontics and Dentofacial Orthopedics*. 2000;117(6):657–662. Available from: [https://doi.org/10.1016/S0889-5406\(00\)70174-0](https://doi.org/10.1016/S0889-5406(00)70174-0).
- 42) Thilander B, Rönning O. Introduction to Orthodontics;vol. 80. 5th ed.. 1985.
- 43) Hu JCC, Chun YHP, Hazzazzi TA, Simmer JP. Enamel Formation and Amelogenesis Imperfecta. *Cells Tissues Organs* . 2007;186(1):78–85. Available from: <https://doi.org/10.1159/000102683>.
- 44) Proffit WR, Vig KWL. Primary failure of eruption: A possible cause of posterior open-bite. *American Journal of Orthodontics*. 1981;80(2):173–190. Available from: [https://doi.org/10.1016/0002-9416\(81\)90217-7](https://doi.org/10.1016/0002-9416(81)90217-7).
- 45) Bishara SE. Impacted maxillary canines: A review. *American Journal of Orthodontics and Dentofacial Orthopedics*. 1992;101(2):159–171. Available from: [https://doi.org/10.1016/0889-5406\(92\)70008-X](https://doi.org/10.1016/0889-5406(92)70008-X).
- 46) Ericson S, Kuroi J. Radiographic examination of ectopically erupting maxillary canines. *American Journal of Orthodontics and Dentofacial Orthopedics* . 1987;91(6):483–492. Available from: [https://doi.org/10.1016/0889-5406\(87\)90005-9](https://doi.org/10.1016/0889-5406(87)90005-9).
- 47) Nieri M, Crescini A, Rotundo R, Baccetti T, Cortellini P, Prato GPP. Factors affecting the clinical approach to impacted maxillary canines: A Bayesian network analysis. *American Journal of Orthodontics and Dentofacial Orthopedics* . 2010;137(6):755–762. Available from: <https://doi.org/10.1016/j.ajodo.2008.08.028>.
- 48) Watted N, Proff P, Reiser V, Shlomi B, Abu-Hussein M, Shamir D, et al. *Clinical Orthodontic Practice: Journal of Dental and Medical Sciences*. 2015;2:102–115.
- 49) Preda L, Fianza AL, Maggio EMD, Dore R, Schifino MR, Campani R, et al. The use of spiral computed tomography in the localization of impacted maxillary canines. *Dentomaxillofacial Radiology* . 1997;26(4):236–241. Available from: <https://doi.org/10.1038/sj.dmf.4600258>.

- 50) Scarfe WC, Farman AG, Sukovic P. Clinical Applications of Cone-Beam Computed Tomography in Dental Practice. *Journal of the Canadian Dental Association*. 2006;72(1):75–80. Available from: <https://www.cda-adc.ca/jcda/vol-72/issue-1/75.pdf>.
- 51) Watted N, Proff P, Reiser V, Shlomi B. CBCT; In Clinical Orthodontic Practice. *Journal of Dental and Medical Sciences*. 2015;14(2):102–115. Available from: https://www.researchgate.net/publication/273318169_CBCT_In_Clinical_Orthodontic_Practice.
- 52) Scarfe WC, Farman AG, Sukovic P, I. Clinical Applications of Cone-Beam Computed Tomography in Dental Practice. *Journal of the Canadian Dental Association*. 2006;72(1):75–80. Available from: <https://www.cda-adc.ca/jcda/vol-72/issue-1/75.pdf>.
- 53) Hechler SL. Cone-Beam CT: Applications in Orthodontics. *Dental Clinics of North America*. 2008;52(4):809–823. Available from: <https://doi.org/10.1016/j.cden.2008.05.001>.
- 54) Welander U, Li G, McDavid WD, Tronje G. Transtomography: a new tomographic scanning technique. *Dentomaxillofacial Radiology*. 2014;33(3):188–195. Available from: <https://doi.org/10.1259/dmfr/55001955>.
- 55) Kumar MA, Mody B, Nair GKR, Surender LR, Gopal SS, Prasad RVKA. Dimensional Accuracy and Details of the Panoramic Cross-sectional Tomographic Images: An in vitro Study. *The Journal of Contemporary Dental Practice*. 2012;13(1):85–97. Available from: <https://www.thejcdp.com/doi/pdf/10.5005/jp-journals-10024-1101>.
- 56) Pirinen S, Arte S, Apajalahti S. Palatal Displacement of Canine is Genetic and Related to Congenital Absence of Teeth. *Journal of Dental Research*. 1996;75(10):1742–1746. Available from: <https://journals.sagepub.com/doi/10.1177/00220345960750100601>.
- 57) Abu-Hussein M, Abdulgani A. Managing congenitally missing lateral incisors with single tooth implants. *American Journal of Orthodontics and Dentofacial Orthopedics*. 2016;2(4):318–324. Available from: https://www.researchgate.net/publication/306037474_Managing_congenitally_missing_lateral_incisors_with_single_tooth_implants.
- 58) Ericson S, Kurol J. Longitudinal study and analysis of clinical supervision of maxillary canine eruption. *Community Dentistry and Oral Epidemiology*. 1986;14(3):172–176. Available from: <https://doi.org/10.1111/j.1600-0528.1986.tb01526.x>.
- 59) Abu-Hussein M, Watted N, Abdulgani A, Zahalka M. Congenitally Missing Lateral Incisor with Orthodontics, Bone Grafting and Single-Tooth Implant: A Case Report. *Journal of Dental and Medical Sciences*. 2015;14(4):124–130. Available from: <https://www.iosrjournals.org/iosr-jdms/papers/Vol14-issue4/Version-6/Z01446124130.pdf>.
- 60) Hamada Y, Timothius CJC, Shin D, Vanchit John. Canine impaction – A review of the prevalence, etiology, diagnosis and treatment. *Seminars in Orthodontics*. 2019;25(2):117–123. Available from: <https://doi.org/10.1053/j.sodo.2019.05.002>.
- 61) Abu-Hussein M, Abdulgani A. Managing congenitally missing lateral incisors with single tooth implants. *Dental Oral and Craniofacial Research*. 2016;2(4):318–324. Available from: https://www.researchgate.net/publication/306037474_Managing_congenitally_missing_lateral_incisors_with_single_tooth_implants.
- 62) Abu-Hussein M, Watted N, Abdulgani A, Bajali M. Treatment of Patients With Congenitally Missing Lateral Incisors: Is an Interdisciplinary Task. *Research & Reviews: Journal of Dental Sciences*. 2014;2(4):53–68. Available from: <https://www.rroj.com/open-access/treatment-of-patients-with-congenitally-missing-lateral-incisors-is-an-interdisciplinary-task-53-68.pdf>.
- 63) Mai A, Azzaldeen A, Nezar W, Muhamad AH. Two Treatment Approaches for Missing Maxillary Lateral Incisors: A Case. *Journal of Dental and Medical Sciences*. 2016;15(7):78–85. Available from: <http://www.iosrjournals.org/iosr-jdms/papers/Vol15-Issue%207/Version-8/M150787885.pdf>.
- 64) Abu-Hussein M, Watted N. Congenitally Missing Upper Laterals. Clinical Considerations: Orthodontic Space Closure. *Journal of Dental and Oral Health*. 2015;1(3):1–6. Available from: <https://www.aaup.edu/publication/nezar.watted/article/congenitally-missing-upper-laterals.-clinical-considerations-orthodontic-space-closure>.