

The Year in Hungarian Cardiology 2022: Arrhythmias

Máté Vámos¹, Péter Kupó²

¹Cardiac Electrophysiology Division, Department of Internal Medicine, University of Szeged, Szeged, Hungary

²Heart Institute, Medical School, University of Pécs, Pécs, Hungary



Video summary from the author

Address for correspondence:

Máté Vámos, MD, PhD, Cardiac Electrophysiology Division, Department of Internal Medicine, University of Szeged
Semmelweis u. 8., 6725 Szeged, Hungary, E-mail: vamos.mate@gmail.com, vamos.mate@med.u-szeged.hu

The year 2022 yielded remarkable scientific papers from Hungary from the field of cardiac arrhythmias. During the search for improved efficacy of pulmonary vein isolation (PVI) interesting topics, such as first-line cryoballoon ablation, use of visualizable steerable sheaths, ablation on the intervenous carina, high-power and very high-power short-duration ablation techniques were investigated. We also learned important lessons from studies investigating the relationship between left atrial anatomy assessed by cardiac computed tomography (CT) and acute/long-term outcomes of PVI procedures. In the field of ablation of supraventricular tachycardias (SVT) researchers demonstrated better outcomes with prophylactic ablation of the peri-incisional isthmus in postoperative atrial flutters, limitations of ventricular pacing maneuvers in paroxysmal SVT diagnostics, the superiority of intracardiac echocardiography (ICE) guided slow pathway ablation, and the feasibility and safety of zero/minimal fluoroscopy approach.

Detailed baseline characteristics of patients from the BUDAPEST-CRT Upgrade Trial (NCT02270840.) were reported. Regarding cardiac resynchronization therapy interesting details were also published about reverse electrical remodeling, and the impact of premature ventricular contractions on atrial remodeling. We got valuable data on the comparative efficacy and safety of laser vs. mechanical lead extraction sheaths.



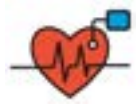

In the field of genetics of cardiac arrhythmias, a robust systematic review was performed and published by a Hungarian multicenter collaboration about the different phenotypic and genotypic manifestations of the CACNA1C gene mutations. Finally, a focused issue of the *Cardiologia Hungarica* on cardiac arrhythmias should be highlighted.

Keywords: pulmonary vein isolation, supraventricular tachycardia, cardiac resynchronization therapy, implantable cardioverter defibrillator, transvenous lead extraction, CACNA1C gene mutations

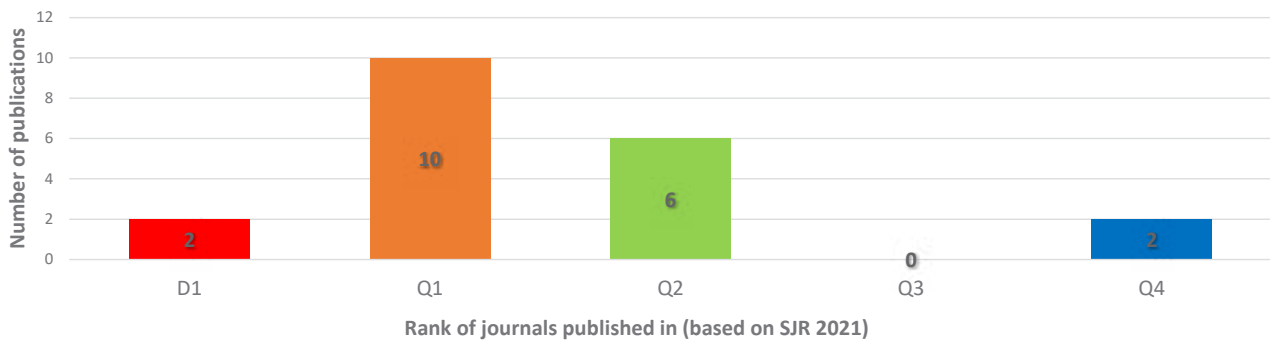
The year 2022 yielded remarkable scientific papers from Hungary in the field of cardiac arrhythmias. In the current review, we summarize those with the highest impact that are at least partly written by Hungarian author(s), the work included in was at least partially car-

ried out at a Hungarian research site(s), and were published in international, peer-reviewed journals. Original research papers are predominantly included, but spectacular case reports or reviews with special impact are also presented.

The Year in Hungarian Cardiology 2022: Arrhythmias

 <p>Ablation of AFib</p> <p>Improved efficacy by</p> <ul style="list-style-type: none"> • First-line cryoballoon ablation • Visualizable steerable sheaths • Bilateral ‘en bloc’ isolation • High-power and very high-power short-duration ablation <p>Improved predication models by</p> <ul style="list-style-type: none"> • Pre-procedural cardiac CT to assess LA and PV anatomy 	 <p>Ablation of PSVT</p> <ul style="list-style-type: none"> • Better outcomes with prophylactic ablation of the peri-incisional isthmus • Limitations of ventricular pacing maneuvers in PSVT • Superiority of ICE-guided slow pathway ablation • Feasibility and safety of zero/minimal fluoroscopy 	 <p>Device therapy</p> <ul style="list-style-type: none"> • Patient characteristics from the BUDAPEST-CRT Upgrade Study • Impact of reverse electrical remodeling in CRT • Impact of PVCs on atrial remodeling in CRT • Head-to-head comparison of laser vs. powered sheaths of transvenous lead extraction 	 <p>Genetics of arrhythmias</p> <ul style="list-style-type: none"> • CACNA1C gene mutation associated Timothy syndrome, “cardiac only” Timothy syndrome, and isolated LQTS8 exhibit major differences • Exon 8/8A mutations carry higher risk
---	--	---	---

A total of 20 international publications with a cumulative impact factor of 91,568 collaborated by Hungarian researchers from the field of cardiac arrhythmias.



GRAPHICAL ABSTRACT Afib: Atrial fibrillation, CRT: cardiac resynchronization therapy, ICE: intracardiac echocardiography, LA: left atrium, LQTS8: long QT syndrome 8, PV: pulmonary vein, PVCs: premature ventricular contractions, PSVT: paroxysmals supraventricular tachycardia, SJR: Scimago Journal Rank

Ablation of atrial fibrillation

Improving efficacy of pulmonary vein isolation

Isolation of the pulmonary veins (PVI) has evolved as the gold standard therapy of atrial fibrillation (AF). More and more evidences support first-line ablation over pharmacological rhythm control. In a sub-analysis of the Cryo Global Registry (participating Hungarian site: Gottsegen National Cardiovascular Center) AF patients treated with first-line cryoballoon ablation (CBA) were compared to CBA in antiarrhythmic drug (AAD)-refractory patients at 12 months. The first-line CBA demonstrated a larger reduction of symptoms compared with CBA after AAD failure (1). *Dr. János and colleagues* from the Electrophysiology Department of University of Pécs compared procedural data of visualizable vs. non-visualizable steerable sheath assisted PVI procedures in patients with AF. In their randomized study (N=100) using visualizable steerable sheaths left atrial (LA) procedure time, radiofrequency (RF) delivery and fluoroscopy exposure could have been reduced without compromising safety or effectiveness (2). In an international collaboration, *Dr. Vámos et al.* demonstrated

a lower arrhythmia recurrence rate in patients with bilateral ‘en bloc’ isolation when compared to those who needed additional carina ablation for complete PVI in a meta-analysis (3).

While we are gaining more and more knowledge about standard ablation methods, the technical development is continuously aiming for safer and more successful energy sources. One new promising method is the high-power short-duration (HPSD) RF ablation thought to be rapid, effective, and safe for PVI because it uses resistive rather than conductive heating in the generally thin-walled atrium (4). *Dr. Salló and researchers* from the Heart and Vascular Centre of Semmelweis University showed in their prospective, observational 3-arm cohort study of 156 patients with AF that both HPSD (ablation index-guided applications with 50W) and very HPSD (90 W for 4 s) RF ablation shortens procedure and RF time and results in a higher rate of first-pass isolation compared to low-power long-duration (ablation index-guided applications with 30W) ablation. Moreover, the use of HPSD and very HPSD ablation increased the acute and mid-term success rate without any safety concerns (5). The same working

group let us to have a closer look on the lesions created by very HPSD ablation (90 W for 4 s) by analyzing 6,551 very HPSD RF points: maximum contact force correlated with maximum temperature and contact force ≥ 5 g led to better tissue heating suggesting good lesion formation (6). *Dr. Kássa and colleagues* from the Gottsegen National Cardiovascular Center provided interesting comparative randomized data on LA lesion size, function, and tissue damage following PVI by HPSD RF vs. second-generation cryoballoon (CB2) ablation. They concluded that CB2 ablation produces a significantly larger LA lesion size compared to "point-by-point" HPSD ablation, both techniques preserve LA function, and the myocardial component of tissue loss appears to be higher using HPSD radio-frequency ablation suggesting less collateral damage, respectively (7).

Imaging in pulmonary vein isolation

Dr. Szegedi and colleagues have published more studies investigating the relationship between LA anatomy assessed by cardiac CT and acute and long-term outcomes of PVI procedures. In a retrospective cohort including 448 patients who underwent initial point-by-point PVI for AF ventral-caudal, dorsal-cranial and dorsal-caudal orientation of the right superior pulmonary vein (PV) showed an association with lower rates of AF recurrence when compared with the reference ventral-cranial orientation (8). They also published their results from a similar retrospective trial that enrolled 428 consecutive patients in which all patients underwent pre-procedural cardiac CT to assess LA and PV anatomy. Abutting left atrial appendage and left superior PV (defined as cases when the minimum distance between the vein and appendage was less than 2 mm) were associated with higher AF recurrence rates (9).

Dr. Boussoussou and colleagues from the Heart and Vascular Centre of Semmelweis University demonstrated in their single-center prospective study enrolled consecutive patients with symptomatic, drug-refractory AF undergoing catheter ablation that LA wall thickness (assessed by cardiac CT) does not have an influence on the acute procedural success of PVI using ablation index and a standardized ablation protocol (10).

News from supraventricular tachycardia ablations

Researchers from the University of Szeged questioned if prophylactic ablation of the peri-incisional isthmus in addition to the standard cavotricuspid isthmus justified in patients with postoperative right atrial (RA) flutter. In their single-center retrospective cohort study (N=142) after extended right atriotomy (for example mitral valve repair/replacement through a transseptal approach, tricuspid valve repair/replacement, atrial or ventricular

septal defect surgery, etc.), ablation of both the cavotricuspid and the peri-incisional isthmus significantly reduced the flutter recurrence rate compared to a cavotricuspid isthmus only ablation supporting the concept of prophylactic ablation of both isthmi even if not proven to support reentry (11). *Dr. Kupó and colleagues* published a paper about the limitations of ventricular pacing maneuvers to differentiate orthodromic reciprocating tachycardia (ORT) from atrioventricular nodal reentry tachycardia (AVNRT) including 60 patients with supraventricular tachycardia (SVT) undergoing invasive electrophysiology (EP) study. The authors found, that no single maneuver was 100% sensitive for ORT and semi-quantitative parameters of VOP (requiring the recognition of specific ECG patterns) have limited reproducibility (12). The same working group highlighted the benefits of intracardiac echocardiography (ICE) in slow pathway (SP) ablations for AVNRTs. In a single-center trial, 91 patients undergoing electrophysiologic study and SP ablation for AVNRT were randomized into fluoroscopy-only or ICE-guided groups. ICE-guidance significantly reduced mapping and ablation time, radiation exposure, and RF delivery in comparison to fluoroscopy-only procedures. Moreover, based on the subgroup analysis of a crossover group (allowed after 8 unsuccessful ablation attempts), early switching to ICE-guided ablation seemed to be an optimal choice in challenging cases (13).

Due to the technological progress made in the last decade, using 3D electroanatomical mapping systems and/or ICE the majority of the ablation procedures can be performed safely with minimal radiation exposure or even without the use of fluoroscopy. *Dr. Debreceni and researchers* from the University of Pécs conducted a meta-analysis including 9,074 patients from 24 trials comparing zero/minimal fluoroscopy (Z/MF) approach to conventional, fluoroscopy-guided strategy for the treatment of paroxysmal SVTs. The authors demonstrated that the Z/MF approach for the catheter ablation of SVTs is a feasible method that reduces radiation exposure and ablation time without compromising the acute and long-term success or complication rates (14).

Novelties in device therapy

Cardiac Resynchronization Therapy

The BUDAPEST-CRT Upgrade Study, one of the most important investigator-initiated, international, multicenter, randomized, controlled trials from Hungary (ClinicalTrials.gov NCT02270840) is getting closer to the final analysis. *Prof. Merkely et al.* published their article in the European Journal of Heart Failure about the baseline clinical characteristics of 360 heart failure (HF) patients with reduced ejection fraction enrolled in the study (15). When comparing with prior CRT trial cohorts, the BUDAPEST-CRT Upgrade study included

older patients with a strong male predominance and a high burden of atrial fibrillation and other comorbidities pinpointing those who should be followed strictly in our clinical practice and making the final results more interesting which are expected to be published in the first half of 2023.

In a systematic review and meta-analysis *Pilecky and colleagues* analyzed the incidence and impact of intrinsic QRS complex width during follow-up in CRT recipients, a simple method to assess reverse electrical remodeling (RER). After inclusion of 16 studies comprising 930 patients, they found that shortening of intrinsic QRS duration (i.e. RER) is a common finding during follow-up of patients undergoing CRT and is associated with mechanical reverse remodeling and clinical improvement (16).

Researchers from the Heart and Vascular Center of the Semmelweis University reported atrial remodeling ($\geq 15\%$ improvement of left atrial volume) and a trend for a better mortality outcome in CRT recipients with a lower number of premature ventricular contractions (PVCs < 11401 within the 1-month follow-up) underlying the importance of the early assessment of ventricular extrasystoles in this patient population (17).

An interesting case was reported by *Dr. Riba and colleagues* about a patient with a previous chest burn injury in whom due to skin necrosis explantation of the primarily implanted CRT-D system was needed. After that, a surgical reimplantation with the combination of transatrial and transapical lead placement and abdominal device pocket was successfully applied (18).

Implantable Cardioverter Defibrillators

To preserve the benefit of atrial sensing without the need to implant an additional lead, a single-lead ICD system with a floating atrial dipole (VDD or DX ICD) has been developed as previously reported in detail also in *Cardiologia Hungarica* (19). *Dr. Vámos et al.* now presented a spectacular case report of a patient with a successful implantation of VDD ICD system via a persistent left superior vena cava (20).

Transvenous lead extraction

Single-center data from 166 consecutive patients undergoing transvenous lead extraction (245 leads, dwelling time 9.4 ± 6.3 years) were retrospectively analyzed at the University of Szeged to compare outcomes directly with the laser and powered mechanical tools. In their analysis published in *Europace* the efficacy and safety of laser and mechanical sheaths were similar, however, in the subgroup of crossover procedures mechanical tools had better performance regarding clinical success. Based on a step-by-step efficacy analysis it could be also demonstrated that device diversity (i.e. availability of different extraction tools) helps to improve outcomes of transvenous lead extraction (21).

Genetics of cardiac arrhythmias

Mutations in the CACNA1C gene – encoding the major Ca^{2+} channel of the heart – may exhibit a variety of clinical manifestations, including typical or atypical Timothy syndromes (TS). They can be associated with multiple organ manifestations, and cardiac involvement in form of malignant arrhythmias, QT_c prolongation, or AV block. “Cardiac only” Timothy syndrome (COTS) shows no extracardiac manifestation, whereas some CACNA1C gene mutations are associated only with QT_c prolongation alone (i.e. long QT syndrome 8, LQT8). *Dr. Borbas et al.* in a Hungarian multicenter collaboration performed a robust systematic review of the different phenotypic and genotypic manifestations of the CACNA1C gene mutations. This comprehensive systematic review demonstrated that CACNA1C gene mutation-associated TS, “cardiac only” TS, and isolated LQTS8 exhibit major differences regarding clinical manifestations and outcomes. Among the phenotypes, TS showed the most severe clinical manifestations with much earlier disease onset, much more pronounced QT_c prolongation, and much higher mortality than other forms. Their work warrants a high degree of surveillance if these diseases especially TS is identified because of the high rate of adverse cardiac events. Based on this report, genotyping of the patients may also help to stratify the risk of the patients as exon 8/8A mutations carry a higher risk (22).

Focus issue of *Cardiologia Hungarica* on arrhythmias

According to traditions, a focused issue of the *Cardiologia Hungarica* was published in 07/2022, presenting interesting reviews and case reports from the world of cardiac arrhythmias. *Martinez-Parachini and Ansel P. Amaral* from the USA summarized our knowledge about cardiac amyloidosis and its electrophysiologic manifestations (23). Moreover, five reviews provided insights into the actualities of vascular ultrasound-guided femoral vein puncture (24), resynchronization therapy in the elderly (25), AF ablation in heart failure (26), subclinical AF and anticoagulant therapy (27), sudden cardiac arrest and resuscitation (28). Furthermore, three interesting case studies were reported covering the topics of left bundle branch area pacing (29), cardiac contractility modulation (30), and AV-nodal reentrant tachycardia (31). It is a special pleasure to mention that from the issue 11/2022, the traditional “I show you an ECG” topic was relaunched (32).

Conclusions

As we proudly presented in the current review, in 2022 Hungarian researchers collaborated in several valuable

scientific papers from the field of clinical and invasive electrophysiology and arrhythmology. The current review summarized a total of 20 international publications, comprising 91,568 cumulative impact factor, published in two D1, ten Q1, six Q2, and two Q4 journals based on the Scimago Journal Rank (see Graphical abstract). Current topics, like ablation of AF and SVTs, CRT, ICD, transvenous lead extraction, and genetics of arrhythmias were covered. The presented publications demonstrate a very active, up-to-date, and internationally highly-rated Hungarian scientific work related to cardiac arrhythmias.

Declaration of interest

The authors has reported that they has no relationships relevant to the contents of this paper to disclose.

References

1. Zucchelli G, Chun KRJ, Khelae SK, et al. Cryo Global Registry Investigators. Impact of first-line cryoablation for atrial fibrillation on healthcare utilization, arrhythmia disease burden and efficacy outcomes: real-world evidence from the Cryo Global Registry. *J Interv Card Electrophysiol* 2022 Nov 4. Epub ahead of print. PMID: 36331681. <https://doi.org/10.1007/s10840-022-01388-6>
2. Janosi K, Debreceni D, Janosa B, et al. Visualizable vs. standard, non-visualizable steerable sheath for pulmonary vein isolation procedures: Randomized, single-centre trial. *Front Cardiovasc Med* 2022 Nov 16; 9: 1033755. PMID: 36465461; PMCID: PMC9709402 <https://doi.org/10.3389/fcvm.2022.1033755>
3. Vamos M, Saghy L, Jankelson L, et al. Inability to perform 'en bloc' pulmonary vein isolation requiring ablation of the intervenous carina increases recurrence of atrial fibrillation: A meta-analysis. *Pacing Clin Electrophysiol* 2022 Dec; 45(12): 1415–1418. Epub 2022 Nov 9. PMID: 36272168. <https://doi.org/10.1111/pace.14604>
4. Leshem E, Zilberman I, Tschabrunn CM, et al. High-Power and Short-Duration Ablation for Pulmonary Vein Isolation: Biophysical Characterization. *JACC Clin Electrophysiol* 2018 Apr; 4(4): 467–479. Epub 2018 Feb 2. PMID: 30067486 <https://doi.org/10.1016/j.jacep.2017.11.018>
5. Salló Z, Perge P, Balogi B, et al. Impact of High-Power and Very High-Power Short-Duration Radiofrequency Ablation on Procedure Characteristics and First-Pass Isolation During Pulmonary Vein Isolation. *Front Cardiovasc Med* 2022 Jul 7; 9: 935705. PMID: 35872909; PMCID: PMC9300971. <https://doi.org/10.3389/fcvm.2022.935705>
6. Orbán G, Salló Z, Perge P, et al. Characteristics of Very High-Power, Short-Duration Radiofrequency Applications. *Front Cardiovasc Med* 2022 Jul 13; 9: 941434. PMID: 35911564; PMCID: PMC9326019. <https://doi.org/10.3389/fcvm.2022.941434>
7. Kassa KI, Nagy Z, Simkovits D, et al. Evaluation of Isolation Area, Myocardial Injury and Left Atrial Function Following High-Power Short-Duration Radiofrequency or Second-Generation Cryoballoon Ablation for Atrial Fibrillation. *J Cardiovasc Dev Dis* 2022 Sep 28; 9(10): 327. PMID: 36286279; PMCID: PMC9604661. <https://doi.org/10.3390/jcdd9100327>
8. Szegedi N, Vecsey-Nagy M, Simon J, et al. Orientation of the right superior pulmonary vein affects outcome after pulmonary vein isolation. *Eur Heart J Cardiovasc Imaging* 2022 Mar 22; 23(4): 515–523. PMID: 33693618. <https://doi.org/10.1093/ehjci/jeab041>
9. Szegedi N, Simon J, Szilveszter B, et al. Abutting Left Atrial Appendage and Left Superior Pulmonary Vein Predicts Recurrence of Atrial Fibrillation After Point-by-Point Pulmonary Vein Isolation. *Front Cardiovasc Med* 2022 Feb 15; 9: 708298. PMID: 35242821; PMCID: PMC8885731. <https://doi.org/10.3389/fcvm.2022.708298>
10. Boussoussou M, Szilveszter B, Vattay B, et al. The effect of left atrial wall thickness and pulmonary vein sizes on the acute procedural success of atrial fibrillation ablation. *Int J Cardiovasc Imaging* 2022 Feb 9. Epub ahead of print PMID: 35138472. <https://doi.org/10.1007/s10554-022-02533-y>
11. Benak A, Kupo P, Bencsik G, et al. Is prophylactic ablation of the cavotricuspid and peri-incisional isthmus justified in patients with postoperative atrial flutter after right atriotomy? *J Cardiovasc Electrophysiol* 2022 Jun; 33(6): 1190–1196. Epub 2022 Apr 10. PMID: 35362181. <https://doi.org/10.1111/jce.15481>
12. Kupó P, Tutuianu CI, Kaninski G, et al. Limitations of ventricular pacing maneuvers to differentiate orthodromic reciprocating tachycardia from atrio-

- ventricular nodal reentry tachycardia. *J Interv Card Electrophysiol* 2022 Mar; 63(2): 323–331. PMID: 33871788. <https://doi.org/10.1007/s10840-021-00993-1>
13. Kupo P, Saghy L, Bencsik G, et al. Randomized trial of intracardiac echocardiography-guided slow pathway ablation. *J Interv Card Electrophysiol* 2022 Apr; 63(3): 709–714. Epub 2022 Jan 19. PMID: 35044581. <https://doi.org/10.1007/s10840-022-01126-y>
14. Debreceni D, Janosi K, Vamos M, et al. Zero and Minimal Fluoroscopic Approaches During Ablation of Supraventricular Tachycardias: A Systematic Review and Meta-Analysis. *Front Cardiovasc Med* 2022 Apr 11; 9: 856145. PMID: 35479287; PMCID: PMC9037593. <https://doi.org/10.3389/fcvm.2022.856145>
15. Merkely B, Gellér L, Zima E, et al. Baseline clinical characteristics of heart failure patients with reduced ejection fraction enrolled in the BUDAPEST-CRT Upgrade trial. *Eur J Heart Fail* 2022 Sep; 24(9): 1652–1661. Epub 2022 Jul 22. PMID: 35791276; PMCID: PMC9796950. <https://doi.org/10.1002/ehfj.2609>
16. Pilecky D, Duray GZ, Elsner D, et al. Association between electrical and mechanical remodeling after cardiac resynchronization therapy: systematic review and meta-analysis of observational studies. *Heart Fail Rev* 2022 Nov; 27(6): 2165–2176. Epub 2022 Jun 7. PMID: 35670890. <https://doi.org/10.1007/s10741-022-10234-w>
17. Merkel ED, Boros AM, Schwertner WR, et al. Effect of single ventricular premature contractions on response to cardiac resynchronization therapy. *BMC Cardiovasc Disord* 2022 Jun 25; 22(1): 289. PMID: 35752761; PMCID: PMC9233778 <https://doi.org/10.1186/s12872-022-02725-3>
18. Riba A, Rashed A, Toth R, Tahin T. Concomitant Transatrial and Transapical CRT-D Lead Implantation in a Patient with Chest Burn Injury. *Thorac Cardiovasc Surg Rep* 2022 Nov 9; 11(1): e61–e63. PMID: 36389130; PMCID: PMC9646397. <https://doi.org/10.1055/s-0042-1757788>
19. Németh M, Zima E, Duray GZ, et al. Clinical utility of the atrioventricular, single-lead defibrillator systems with a floating atrial dipole (DX ICD): an executive summary. *Card Hung* 2021; 51: 189–195. <https://doi.org/10.26430/CHUNGARICA.2021.51.3.189>
20. M Vamos, L Saghy, G Bencsik. Implantation of a VDD implantable cardioverter-defibrillator lead via a persistent left superior vena cava. *Herzschrittmacherther Elektrophysiol* 2022; 10.1007/s00399-021-00835-7. (published online ahead of print, 2022 Jan 6). <https://doi.org/10.1007/s00399-021-00835-7>
21. Zsigmond EJ, Saghy L, Benak A, et al. A head-to-head comparison of laser vs. powered mechanical sheaths as first choice and second line extraction tools. *Europace* 2022 Nov 10; euac200. Epub ahead of print PMID: 36352816. <https://doi.org/10.1093/europace/euac200>
22. Borbás J, Vámos M, Hategan L, et al. Geno- and phenotypic characteristics and clinical outcomes of CACNA1C gene mutation associated Timothy syndrome, “cardiac only” Timothy syndrome and isolated long QT syndrome 8: A systematic review. *Front Cardiovasc Med* 2022 Nov 29; 9: 1021009. PMID: 36523353; PMCID: PMC9745330 <https://doi.org/10.3389/fcvm.2022.1021009>
23. Jose R. Martinez-Parachini, Ansel P. Amaral, Cardiac amyloidosis and its electrophysiologic manifestations. *Cardiologia Hungarica* 2022; 52: 198–203. <https://doi.org/10.26430/CHUNGARICA.2022.52.3.198>
24. Kupó P, Jánosi K, Debreceni D, et al. Vascular ultrasound guided femoral vein puncture in cardiac electrophysiology procedures. *Cardiologia Hungarica* 2022; 52: 204–207. <https://doi.org/10.26430/CHUNGARICA.2022.52.3.204>
25. Behon A, Merkel ED, Schwertner WR, et al. Cardiac resynchronization therapy in the elderly: Systematic Review. *Cardiologia Hungarica* 2022; 52: 208–217. <https://doi.org/10.26430/CHUNGARICA.2022.52.3.208>
26. Tóth P, Komlósi F, Vámosi P, et al. Atrial fibrillation ablation in heart failure *Cardiologia Hungarica* 2022; 52: 218–225
27. Vámos M, Kupó P, Miklós M, et al. Subclinical atrial fibrillation and anticoagulant therapy: What do we know in 2022? *Cardiologia Hungarica* 2022; 52: 234–238. <https://doi.org/10.26430/CHUNGARICA.2022.52.3.234>
28. Nagy B, Kiss B, Pál-Jakab Á, et al. Sudden cardiac arrest and resuscitation: novelties. *Cardiologia Hungarica* 2022; 52: 239–245. <https://doi.org/10.26430/CHUNGARICA.2022.52.3.239>
29. Miklós M, Benák A, Sággy L, et al. Left bundle branch area pacing using a stylet-driven lead and a new type of delivery sheath with a 3D curve. *Cardiologia Hungarica* 2022; 52: 246–250. <https://doi.org/10.26430/CHUNGARICA.2022.52.3.246>
30. Tóth AZ, Csanádi Z, Sándorfi G, et al. Cardiac contractility modulation induced left ventricular reverse remodelling in a patients with dilated cardiomyopathy. *Cardiologia Hungarica* 2022; 52: 251–253. <https://doi.org/10.26430/CHUNGARICA.2022.52.3.251>
31. Jánosi KF, Debreceni D, Simor T, et al. AV-nodal reentrant tachycardia as a potential trigger for atrial fibrillation: a case report. *Cardiologia Hungarica* 2022; 52: 254–256. <https://doi.org/10.26430/CHUNGARICA.2022.52.3.254>
32. Simon A. The application of the Lewis-lead. *Cardiologia Hungarica* 2022; 52: 323, 336. <https://doi.org/10.26430/CHUNGARICA.2022.52.4.323>