


# Transesophageal echocardiography-guided versus fluoroscopy-guided patent foramen ovale closure: A single center registry

Alexandru Achim MD<sup>1,2,3</sup>  | Paul Hochegger MD<sup>1</sup> | Sadeek S. Kanoun Schnur MD<sup>1,3,4</sup> | Lisa Moser MD<sup>1</sup> | Cosima Stark MD<sup>1</sup> | Robertas Pranevičius MD<sup>1,5</sup> | Dan Prunea MD<sup>1</sup> | Albrecht Schmidt MD<sup>1</sup> | Klemens Ablasser MD<sup>1</sup> | Nicolas Verheyen MD<sup>1</sup> | Ewald Kolesnik MD<sup>1</sup> | Robert Maier MD<sup>1</sup> | Olev Luha MD<sup>1</sup> | Zoltan Ruzsa MD<sup>3</sup> | Andreas Zirlik MD<sup>1</sup> | Gabor G. Toth MD<sup>1</sup>

<sup>1</sup>Department of Cardiology, University Heart Center Graz, Medical University of Graz, Graz, Austria

<sup>2</sup>“Nicolae Stancioiu” Heart Institute, University of Medicine and Pharmacy “Iuliu Hatieganu” Cluj-Napoca, Cluj-Napoca, Romania

<sup>3</sup>Department of Internal Medicine, Invasive Cardiology Division, University of Szeged, Szeged, Hungary

<sup>4</sup>South West Peninsula Deanery, University Plymouth Hospitals NHS Trust, Plymouth, UK

<sup>5</sup>Department of Cardiology, Hospital of Lithuanian University of Health and Sciences, Vilnius, Lithuania

## Correspondence

Gabor G. Toth, MD, PhD, Department of Cardiology, University Heart Center Graz, Department of Cardiology, Medical University of Graz, Auenbruggerplatz 15, 8036, Graz, Austria.

Email: [gabor.g.toth@medunigraz.at](mailto:gabor.g.toth@medunigraz.at), [toth.gabr@gmail.com](mailto:toth.gabr@gmail.com)

All authors take responsibility for all aspects of the reliability and freedom from bias of the data presented and their discussed interpretation.

## Abstract

**Background:** Percutaneous closure of patent foramen ovale (PFO) is conventionally performed under continuous transesophageal echocardiographic (TEE) guidance. We aimed to evaluate whether a simplified procedural approach, including pure fluoroscopy-guidance and final TEE control, as well as an aimed ‘next-day-discharge’ is comparable with the conventional TEE-guided procedure in terms of periprocedural and intermediate-term outcomes.

**Methods:** All patients who underwent a PFO closure at our center between 2010 and 2022 were retrospectively included. Prior to June 2019 cases were performed with continuous TEE guidance (TEE-guided group). Since June 2019, only pure fluoroscopy-guided PFO closures have been performed with TEE insertion and control just prior to device release (fluoroscopy-guided group). We analyzed procedural aspects, as well as long term clinical and echocardiographic outcomes.

**Results:** In total 291 patients were included in the analysis: 197 in the TEE-guided group and 94 in the fluoroscopy-guided group. Fluoroscopy-guided procedures were markedly shorter ( $48 \pm 20$  min vs.  $25 \pm 9$  min;  $p < .01$ ). There was no difference in procedural complications, including death, major bleeding, device dislodgement, stroke

**Abbreviations:** PFO, patent foramen ovale; TEE, transesophageal echocardiography.

Alexandru Achim and Paul Hochegger contributed equally to this work.

This is an open access article under the terms of the [Creative Commons Attribution-NonCommercial-NoDerivs](https://creativecommons.org/licenses/by-nc-nd/4.0/) License, which permits use and distribution in any medium, provided the original work is properly cited, the use is non-commercial and no modifications or adaptations are made.

© 2023 The Authors. *Echocardiography* published by Wiley Periodicals LLC.

or clinically relevant peripheral embolization between the two groups (.5% vs. 0%;  $p = .99$ ). Hospital stay was also shorter with the simplified approach ( $2.5 \pm 1.6$  vs.  $3.5 \pm 1.2$  days;  $p < .01$ ), allowing 85% same-day discharges during the last 12 months of observation period.

At  $6 \pm 3$  months echocardiographic follow-up a residual leakage was described in 8% of the TEE-guided cases and 2% of the fluoroscopy-guided cases ( $p = .08$ ).

**Conclusion:** While a complete TEE-free PFO closure might have potential procedural risks, our approach of pure fluoroscopy-guided with a brisk final TEE check seems to be advantageous in terms of procedural aspects with no sign of any acute or intermediate-term hazard and it could offer an equitable compromise between the two worlds: a complete TEE procedure and a procedure without any TEE.

#### KEYWORDS

patent foramen ovale, percutaneous closure, transesophageal echocardiography

## 1 | INTRODUCTION

Patent foramen ovale (PFO) is the most common congenital heart defect, affecting around 20%–25% of the total population but remains clinically irrelevant and undetected in the majority of cases.<sup>1</sup> However, it is frequently diagnosed among patients with cryptogenic stroke and identified as a potential source of paradoxical embolization,<sup>2,3,4</sup> as well as among patients with migraine with aura,<sup>5</sup> making the indication for percutaneous closure.<sup>1</sup>

During PFO closure transesophageal echocardiography (TEE) has traditionally played a key role in the guidance to minimize the risk of severe complications such as cardiac perforation or device embolization due to inaccurate sizing or failed positioning.<sup>6</sup> Conventionally, percutaneous PFO closures are performed under continuous TEE-guidance to facilitate proper septal crossing, accurate sizing, appropriate device positioning and to confirm stability as well as final positioning prior to device release. However, such utilization of TEE has its logistical burdens especially regarding patient discomfort and the necessity for continuous sedation or even general anesthesia.<sup>6</sup> Contrarily, some experienced centers perform the procedure with pure fluoroscopy guidance with or without a brisk final TEE control of correct device position and stability prior to final release.<sup>7,8</sup>

The aim of the present registry was to evaluate, whether a purely fluoroscopy-guided procedure is comparable with conventional continuous TEE-guided PFO closure in terms of procedural aspects and clinical outcomes.

## 2 | METHODS

### 2.1 | Patient selection

In this single center retrospective registry patients were included, who underwent elective isolated percutaneous PFO closure with

an Amplatzer-like self-expanding double-disk PFO occluder between 2010 and 2021 at the Department of Cardiology of the Medical University of Graz (Graz, Austria).

Until June 2019 the standard operating protocol indicated continuous TEE guidance for the whole procedure, including the crossing of the PFO, the sizing, positioning of the device, and final position check prior to release (which consisted the TEE-guided group). As of July 2019, the standard operating protocol has been changed, indicating pure fluoroscopic guidance with final TEE-control of the device position prior to release, allowing recapturing and repositioning if necessary (forming the fluoroscopy-guided group).

As an indication, all patients experienced at least one cryptogenic ischemic stroke and had a PFO with at least 2 mm separation with a spontaneous or provoked right-to-left shunt proven by TEE-derived color Doppler or contrast echocardiography. Absence of atrial fibrillation on Holter ECG monitoring was a prerequisite prior to PFO closure. Echocardiographic measurements such as PFO channel length, channel separation and morphological characteristics were also assessed.

The local ethics commission approved the study. Due to the retrospective nature of this study, an informed consent was not available.

### 2.2 | Procedure

All PFO closure procedures were performed via femoral vein access using Amplatzer-like self-expanding double-disk PFO occluders. Body weight adjusted unfractionated heparin (100 IU/kg) was administered. PFO cannulation was with a multipurpose catheter. Over an extra-stiff guidewire either balloon-sizing was performed at the operators' discretion, or the delivery sheath was directly positioned into the left atrium. Subsequently, the occluder was delivered by firstly releasing the left-side disk in the left atrium, then withdrawing the device against the atrial septum maintaining tension to facilitate the release of the right-sided disk in the right atrium. Once properly positioned, fully opened

**TABLE 1** Patient demographic and clinical characteristics.

	All		TEE guided		Fluoroscopy-guided		p
	n = 291		n = 197		n = 94		
	n/means	%/SD	n/means	%/SD	n/means	%/SD	
Age	50.8	10.8	49.8	10.9	52.9	10.2	.07
Gender	191	65.6	127	64.5	64	68.1	.83
Hypertension	114	39.2	72	36.5	42	44.7	.41
Dyslipidemia	166	57.0	103	52.3	63	67.0	.06
Diabetes mellitus	17	5.8	11	5.6	6	6.4	.96
Coronary artery disease	9	3.1	7	3.6	2	2.1	.81
Peripheral artery disease	6	2.1	3	1.5	3	3.2	.64
BMI	26.3	4.4	25.8	4.2	27.2	4.9	.08
Stroke/TIA, as indication	245	84.2	161	81.7	84	89.4	.25
Channel length	10.1	3.9	9.7	3.6	11.5	4.6	.02
Channel separation	2.0	1.6	1.4	1.3	3.1	1.6	<.01
Atrial septal aneurysm	138	47.4	101	51.3	37	39.4	.16

Abbreviations: BMI, body mass index; TIA, transient ischemic attack.

and attachment of disks on either side of the septum were confirmed, the occluder was completely released from the delivery sheath which was subsequently removed. A single-shot antibiotic was given prior to the procedure as prophylaxis.

For the *TEE-guided group* the entire procedure was performed under continuous TEE- and fluoroscopic guidance, including (1) cannulation of the PFO, (2) balloon sizing if performed, (3) the positioning of the left sided disk, (4) the positioning of the right-sided disk, (5) checking the final position and (6) the release of the occluder. Accordingly, for these cases conscious sedation was induced for the entire procedure.

For the *fluoroscopy-guided group* (1) cannulation of the PFO, (2) the positioning of the left sided disk, (3) the positioning of the right-sided disk were done under pure fluoroscopic guidance, followed by (4) brisk TEE-control of the final position and (5) the release of the occluder. These cases were performed with local anesthesia alone, except brief conscious sedation for the final TEE-control. For these cases sizing was based on preprocedural TEE, when diagnosis of PFO was made.

In the absence of other indications, patients received aspirin for at least 2 years and clopidogrel for 1–6 months after the procedure.

## 2.3 | Follow-up

Data were collected on procedural characteristics, such as duration, used device sizes and procedural complications. Clinical and echocardiographic follow-up was assessed in terms of residual shunt at 6 months, embolic events and atrial fibrillation at latest clinical follow-up.

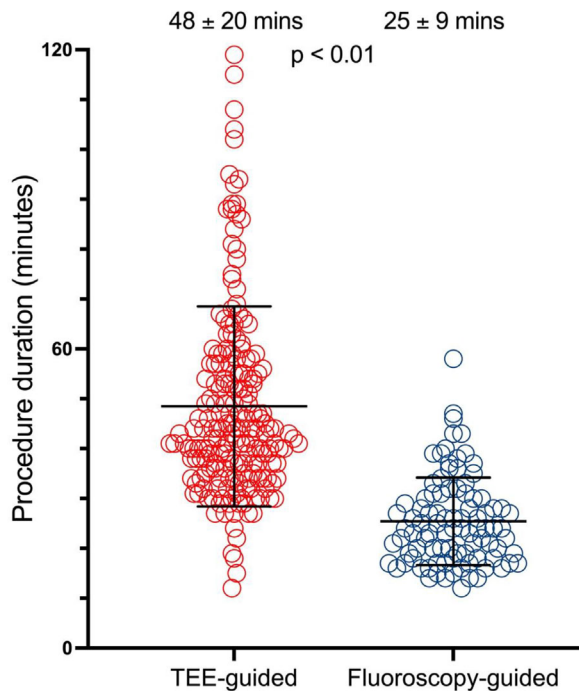
## 2.4 | Statistical analysis

All analyses were performed with Prism GraphPad 5.0 (GraphPad Software Inc., California, US). Summary descriptive statistics are reported as mean  $\pm$  SD or *n* (%), as appropriate. Normal distribution was tested by D'Agostino-Pearson omnibus normality test. Continuous variables were compared by Mann-Whitney tests or Kruskal-Wallis test and categorical variables were compared with Fisher's exact or chi-square tests, as appropriate. A probability value of  $p < .05$  was considered as significant.

## 3 | RESULTS

### 3.1 | Patients

In total 291 patients were included and divided into two cohorts: the *TEE-guided group* ( $n = 197$ ) and the *fluoroscopy-guided group* ( $n = 94$ ). The two groups were divided chronologically, after the operation protocol change in 2019, described in the Methods section. Patient characteristics are listed in Table 1. The study found no significant difference in age, gender and cardiovascular risk factors between the two groups. Pre-operative echocardiographic measurements demonstrated significant difference between the two groups, showing larger and longer PFOs in the fluoroscopy-guided cohort. This difference might originate from the fact that due to the methodologic difference between the two groups (TEE during procedure vs. historical TEE) the measurements were made at different timepoints.



**FIGURE 1** Scatter dot plot of procedural time in TEE-guided PFO closure cases versus fluoroscopy-guided PFO closure cases.

### 3.2 | Procedure

All patients, included in the analysis underwent successful PFO closure. During the recruitment period, four patients had failed PFO closure procedure attempts and therefore were excluded, all due to small-sized or misdiagnosed PFO.

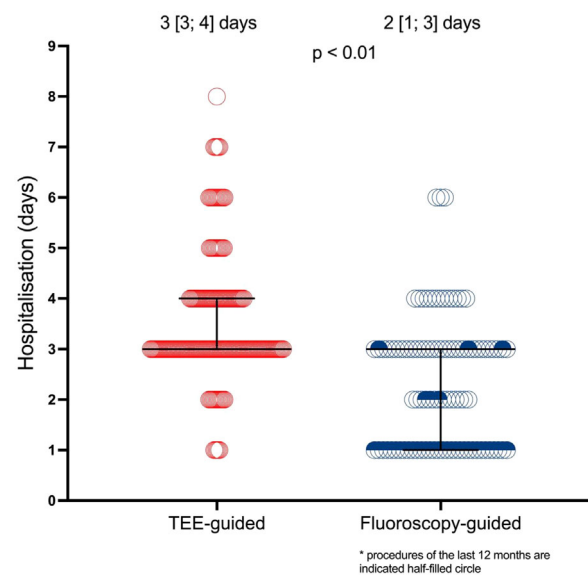
Fluoroscopy-guided cases crossed-over to TEE-guidance in 6% due to failed wiring with pure fluoroscopic guidance. Still, compared to TEE-guided cases, the intentional fluoroscopy-guided procedures were markedly shorter ( $48 \pm 20$  min vs.  $25 \pm 9$  mins;  $p < .01$ ) as shown in Figure 1. Whilst sizing was determined intraprocedural for the TEE-guided group, TEE-guided cases with device sizing based on the preprocedural TEE resulted in smaller devices (left-sided disc of  $26 \pm 2$  mm vs.  $18 \pm 2$  mm;  $p < .01$ ).

There were no differences in the composite of all relevant procedural complications, including major bleeding and device dislodgement between the two groups (0.5% vs. 0%;  $p = .99$ ).

The fluoroscopy-guided approach allowed performing the procedures in the day-clinic concept in 35% of the cases, with an increase to 86% for the last 12 months. The total hospitalization appears also to be markedly shorter for fluoroscopy-guided approach than for TEE-guided approach (3 [3; 4] vs. 2 [1; 3] days;  $p < .01$ ). Figure 2.

### 3.3 | Follow-up

About 85% of all patients completed 6-months clinical follow-up and 75% of all patients completed 6-months (mean average  $6 \pm 3$  months) echocardiography follow-up. The rate of embolic events dur-



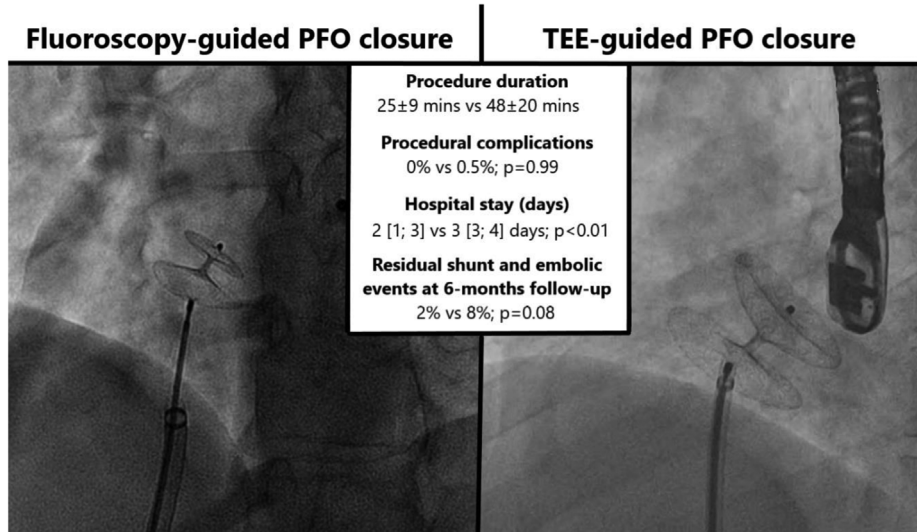
**FIGURE 2** Scatter Dot Plot of hospitalization duration in TEE-guided PFO closure cases versus fluoroscopy-guided PFO closure cases.

ing follow-up was 5% in the TEE-guided patients versus 0% in the fluoroscopy-guided patients ( $p = .13$ ). Atrial fibrillation was numerically more frequent in the TEE-guided group during the first 6 months (3.6% vs. 1.1%;  $p = .44$ ). Echocardiography follow-up indicated in the TEE-guided group a trend for more frequent residual shunts (8.4% vs. 1.6%;  $p = .08$ ).

## 4 | DISCUSSION

The present data suggest that (1) pure fluoroscopy-guided PFO closure procedures are markedly shorter (2) with comparable efficacy (3) and without any signal of increased hazard during the procedure or on long term, and (4) crossover due to necessity of TEE-guidance is rare. The key findings of our head-to-head study are illustrated in Figure 3.

The choice of intraprocedural imaging during PFO closure varies across institutions and operators mainly depending on their experiences and the local practices. While current guidelines recommend routine intraprocedural use of either TEE or intracardiac echocardiography to guide the procedure,<sup>9</sup> still many centers are exploring to base the procedure on fluoroscopy-guidance alone.<sup>10-12</sup> However that implies refraining from obtaining certain information that can be only brought by echocardiographic visualization alone. Most notably, procedural echocardiography allows the operator to detect potentially detrimental complications such as an atrial thrombus, pericardial effusion or intracardiac air bubbles immediately and intervene accordingly. Additionally, use of angiography alone has limited accuracy in detecting residual right-to-left shunts. As immediate post-procedural residual shunt has been shown to predict late shunt after PFO closure, literature data suggest that patients, undergoing pure fluoroscopy guided



**FIGURE 3** Central figure—better logistics with fluoroscopy-guided PFO closure if TEE is performed only as a final step during the procedure rather than a continuous guidance tool.

PFO closure may have a higher incidence of residual interatrial shunts requiring reintervention.<sup>13,14</sup>

Our combined fluoroscopy-TEE-guided approach is considered therefore to offer an 'optimal compromise of the two worlds': (1) fluoroscopy guidance allows to identify a significant proportion of patients at the time of index procedure, who otherwise would have presented with ineffective PFO closure at follow-up; (2) Being performed at the pre-release phase, TEE guidance also allows to react on suboptimal findings with repositioning or re-sizing of the device, if necessary; still (3) the very short TEE examination requires shorter and milder sedation with improved patient comfort and last but not least (4) dividing the fluoroscopy-guided steps and the echocardiography-control reduces the radiation exposure for the echocardiographer.

Once the PFO closure indication has been made, imaging plays a pivotal role both pre- and peri-procedurally. Transthoracic echocardiography (TTE), TEE, and transcranial Doppler, in conjunction with agitated saline contrast (a "bubble study"), can all detect a right-to-left shunt associated with a PFO. Among these methods, only TEE allows visualization of the site and size of the shunt and it is currently considered the gold standard for PFO investigation.<sup>15</sup> TEE has two key roles: (1) preprocedural to record the shunt and determine its size and anatomical position in relation to other structures from the right atrium as well as selection of the appropriate size and type of closure device (2) intraprocedural to guide the guidewire and catheter during crossing of the PFO and the positioning of the device. It can also visualize the final device location, its stability and its efficacy but also its relation to adjacent structures, particularly mitral valve competency and patency of the coronary sinus, monitoring for complications immediately following deployment. The disadvantage in using TEE during procedure is that this demands the use of general sedation and mechanical ventilation that has the potential risk of anesthetic-related complications. Moreover, it prolongs the procedure and the patient may have to be supervised and hospitalized for 12–24 h. If only con-

scious sedation is used, it will be to the detriment of the patient's comfort.

The approach remains different from center to center, some prefer only fluoroscopy,<sup>16,17</sup> others avoid it completely, performing the entire procedure under exclusively ultrasound guidance.<sup>18</sup> In an analysis of these studies, one observes an equipoise in terms of outcomes, but operative times are always increased when TEE is introduced.<sup>16–19</sup> Therefore, the reduction of TEE offers immediate practical, logistical benefits—an important fact in the context in which more and more centers aim to perform this procedure in same-day discharge clinics. The authors believe that operator- and institutional-level PFO closure volumes may affect procedural outcomes more than one approach vs. the other. Concerns regarding a potentially higher incidence of residual shunts were not reported in centers reducing the TEE guidance steps and a selective, rather than routine use of TEE represents a maturation of the respective center.<sup>20</sup>

The Patent Foramen Ovale Closure or Anticoagulation versus Antiplatelets after Stroke (CLOSE) trial has demonstrated that in patients with a previous cryptogenic stroke percutaneous PFO closure is associated with less recurrent ischemic strokes, as compared to antiplatelet therapy alone.<sup>21</sup> However, percutaneous PFO closure was associated with a higher incidence of new onset atrial fibrillations in the CLOSE group, showing the dark side of the approach. The same clinical advantage was confirmed by the Patent Foramen Ovale Closure or Antiplatelet Therapy for Cryptogenic Stroke (REDUCE) trial, where a lower rate of brain ischemic events was even demonstrated on neuroimaging by systematic follow-up with magnetic resonance imaging.<sup>22</sup>

There is lately a growing interest for alternative indications, among which migraine impacts the widest population. So far two randomized multicentric trials have been conducted in the field, both were negative: Closure of Patent Foramen Ovale in Migraine With Aura (PRIMA) was a randomized sham-controlled trial, failing



meet the primary endpoint of reduction in responder rate in patients with frequent migraine.<sup>23</sup> Prospective Randomized Investigation to Evaluate Incidence of Headache Reduction in Subjects with Migraine and PFO Using the Amplatzer PFO Occluder Compared to Medical Management (PREMIUM) trial, a randomized non-blinded trial that showed no difference in the monthly migraine days, when comparing PFO closure to medical therapy alone.<sup>24</sup> Still, pooled meta-analysis of the two trials revealed that PFO closure may still markedly improve symptomatic relief for patients.

There are some limitations of our study that need to be mentioned: (1) This analysis was performed in the context of a retrospective registry with no randomization, however a potential selection-bias can be excluded due to an on-date switch from old to new standard operating procedure; (2) All cases were performed with conventional Amplatzer-like devices therefore it is not generalizable for novel techniques; (3) It is reassuring that the reduction in total procedure time translated into improved catheterization lab efficiency and that the reported incidence of complications remained low but this must be interpreted in the context in which these procedures were carried out which is in a high-volume institution by two experienced operators and that these data do not guarantee reproducibility or applicability in other centers.

## 5 | CONCLUSION

Our study showed that purely fluoroscopy-guided PFO closure procedures with a brisk final TEE control are markedly shorter in duration than continuous TEE-guided procedures and yet, no excess in periprocedural and intermediate-term hazards were identified.

## ACKNOWLEDGMENTS

The authors have nothing to report.

## CONFLICT OF INTEREST STATEMENT

G.T. reports consultancy fees and unrestricted research- or educational grants from Abiomed, Abbott, Medtronic, Biotronik and Terumo. Other authors report no conflicts of interest.

## DATA AVAILABILITY STATEMENT

The data presented in this study are available on request from the corresponding author.

## ORCID

Alexandru Achim MD  <https://orcid.org/0000-0002-5540-3478>

## REFERENCES

- Homma S, Sacco RL. Patent foramen ovale and stroke. *Circulation*. 2005;112:1063-1072. doi: [10.1161/CIRCULATIONAHA.104.524371](https://doi.org/10.1161/CIRCULATIONAHA.104.524371)
- Lechat P, Mas JL, Lascault G, et al. Prevalence of patent foramen ovale in patients with stroke. *N Engl J Med*. 1988;318:1148-1152.
- Overell JR, Bone I, Lees KR. Interatrial septal abnormalities and stroke: a meta-analysis of case-control studies. *Neurology*. 2000;55(8):1172-1179. doi: [10.1212/wnl.55.8.1172](https://doi.org/10.1212/wnl.55.8.1172)
- Handke M, Harloff A, Olschewski M, Hetzel A, Geibel A. Patent foramen ovale and cryptogenic stroke in older patients. *N Engl J Med*. 2007;357:2262-2268.
- Anzola GP, Magoni M, Guindani M, Rozzini L, Dalla Volta G. Potential source of cerebral embolism in migraine with aura: a transcranial Doppler study. *Neurology*. 1999;52:1622-1625.
- Mojadidi MK, Bogush N, Caceres JD, Msaouel P, Tobis JM. Diagnostic accuracy of transesophageal echocardiogram for the detection of patent foramen ovale: a meta-analysis. *Echocardiography*. 2014;31:752-758. doi: [10.1111/echo.12462](https://doi.org/10.1111/echo.12462)
- Wahl A, Tai T, Praz F, et al. Late results after percutaneous closure of patent foramen ovale for secondary prevention of paradoxical embolism using the amplatzer PFO occluder without intraprocedural echocardiography: effect of device size. *JACC Cardiovasc Interv*. 2009;2:116-123.
- Hildick-Smith D, Behan M, Haworth P, Rana B, Thomas M. Patent foramen ovale closure without echocardiographic control: use of 'standby' intracardiac ultrasound. *JACC Cardiovasc Interv*. 2008;1:387-391.
- Silvestry FE, Cohen MS, Armsby LB, et al. Guidelines for the echocardiographic assessment of atrial septal defect and patent foramen ovale: from the American Society of Echocardiography and Society for Cardiac Angiography and Interventions. *J Am Soc Echocardiogr*. 2015;28:910-958.
- Mangieri A, Godino C, Montorfano M, et al. PFO closure with only fluoroscopic guidance: 7 years real-world single centre experience. *Catheter Cardiovasc Interv*. 2015;86:105-112.
- Manolis AS, Koulouris S, Rouska E, Pyrros J. Simplified percutaneous closure of patent foramen ovale and atrial septal defect with use of plain fluoroscopy: single operator experience in 110 consecutive patients. *Indian Heart J*. 2018;70:24-31.
- Barker M, Muthuppalaniappan AM, Abrahamyan L, et al. Periprocedural outcomes of fluoroscopy-guided patent foramen ovale closure with selective use of intracardiac echocardiography. *Can J Cardiol*. 2020;36:1608-1615.
- Diaz T, Cubeddu RJ, Rengifo-Moreno PA, et al. Management of residual shunts after initial percutaneous patent foramen ovale closure: a single center experience with immediate and long-term follow-up. *Catheter Cardiovasc Interv*. 2010;76:145-150.
- Deng W, Yin S, McMullin D, et al. Residual shunt after patent foramen ovale closure and long-term stroke recurrence: a prospective cohort study. *Ann Intern Med*. 2020;172:717-725. doi: [10.7326/M19-3583](https://doi.org/10.7326/M19-3583)
- Pinto FJ. When and how to diagnose patent foramen ovale. *Heart*. 2005;91(4):438-440. doi: [10.1136/hrt.2004.052233](https://doi.org/10.1136/hrt.2004.052233)
- Mangieri A, Godino C, Montorfano M, et al. PFO closure with only fluoroscopic guidance: 7 years real-world single centre experience. *Catheter Cardiovasc Interv*. 2015;86(1):105-112. doi: [10.1002/ccd.25735](https://doi.org/10.1002/ccd.25735)
- Guo Y, Shi Z, Zheng Y, et al. Short-term results of percutaneous closure of a patent foramen ovale guided by transoesophageal echocardiography in patients with cryptogenic stroke: a retrospective study. *J Cardiothorac Surg*. 2022;17(1):96. doi: [10.1186/s13019-022-01845-3](https://doi.org/10.1186/s13019-022-01845-3)
- Wang S, Zhu G, Liu Z, Zhou J, Zang W. Only transesophageal echocardiography guided patent foramen ovale closure: a single-center experience. *Front Surg*. 2022;9:977959. doi: [10.3389/fsurg.2022.977959](https://doi.org/10.3389/fsurg.2022.977959)
- Barker M, Muthuppalaniappan AM, Abrahamyan L, et al. Periprocedural outcomes of fluoroscopy-guided patent foramen ovale closure with selective use of intracardiac echocardiography. *Can J Cardiol*. 2020;36(10):1608-1615. doi: [10.1016/j.cjca.2019.12.032](https://doi.org/10.1016/j.cjca.2019.12.032)
- Asbeutah AA, Junaid M, Hassan F, et al. Same day discharge after structural heart disease interventions in the era of the coronavirus-19 pandemic and beyond. *World J Cardiol*. 2022;14(5):271-281. doi: [10.4330/wjcv.14.5.271](https://doi.org/10.4330/wjcv.14.5.271)
- Mas JL, Derumeaux G, Guillon B, et al, CLOSE Investigators. Patent foramen ovale closure or anticoagulation vs. antiplatelets after stroke. *N Engl J Med*. 2017;377:1011-1021. doi: [10.1056/NEJMoa1705915](https://doi.org/10.1056/NEJMoa1705915)

22. Søndergaard L, Kasner SE, Rhodes JF, et al, Gore REDUCE Clinical Study Investigators. Patent foramen ovale closure or antiplatelet therapy for cryptogenic stroke. *N Engl J Med*. 2017;377:1033-1042. doi: [10.1056/NEJMoa1707404](https://doi.org/10.1056/NEJMoa1707404)
23. Mattle HP, Evers S, Hildick-Smith D, et al. Percutaneous closure of patent foramen ovale in migraine with aura, a randomized controlled trial. *Eur Heart J*. 2016;37(26):2029-2036. doi: [10.1093/eurheartj/ehw027](https://doi.org/10.1093/eurheartj/ehw027)
24. Tobis JM, Charles A, Silberstein SD, et al. Percutaneous closure of patent foramen ovale in patients with migraine: the PREMIUM trial. *J*

*Am Coll Cardiol*. 2017;70(22):2766-2774. doi: [10.1016/j.jacc.2017.09.1105](https://doi.org/10.1016/j.jacc.2017.09.1105)

**How to cite this article:** Achim A, Hochegger P, Kanoun Schnur SS, et al. Transesophageal echocardiography-guided versus fluoroscopy-guided patent foramen ovale closure: A single center registry. *Echocardiography*. 2023;1-7. <https://doi.org/10.1111/echo.15630>