

# Normal reference values of tricuspid annular dimensions and functional properties in healthy adults using three-dimensional speckle-tracking echocardiography (Insights from the MAGYAR-Healthy Study)

Attila Nemes, Árpád Kormányos, Gergely Rácz, Zoltán Ruzsa, Nóra Ambrus, Csaba Lengyel

Department of Medicine, Albert Szent-Györgyi Medical School, University of Szeged, Szeged, Hungary

*Contributions:* (I) Conception and design: A Nemes; (II) Administrative support: N Ambrus, Z Ruzsa; (III) Provision of study materials or patients: A Nemes, Á Kormányos, G Rácz; (IV) Collection and assembly of data: Á Kormányos, G Rácz; (V) Data analysis and interpretation: Á Kormányos; (VI) Manuscript writing: All authors; (VII) Final approval of manuscript: All authors.

*Correspondence to:* Attila Nemes, MD, PhD, DSc, FESC. Department of Medicine, Albert Szent-Györgyi Medical School, University of Szeged, H-6725 Szeged, Semmelweis street 8, Hungary. Email: nemes.attila@med.u-szeged.hu.

**Background:** Three-dimensional speckle-tracking echocardiography (3DSTE) is a relatively new non-invasive imaging modality with ability for simultaneous chamber quantifications and determination of valvular dimensions. The aim of the present retrospective cohort study was to determine normal reference values of 3DSTE-derived tricuspid annular (TA) dimensions and functional properties and to evaluate their age- and gender dependency.

**Methods:** The present study comprised 156 healthy adult subjects, from which 28 cases were excluded due to inferior image quality, therefore the remaining group consisted of 128 cases with the mean age of  $35.4 \pm 12.5$  years (72 males). The subject population was further divided into the following categories: 18–29 years ( $n=57$ ; mean age:  $25.2 \pm 2.8$  years, 51 males), 30–39 years ( $n=29$ ; mean age:  $34.1 \pm 2.5$  years, 31 males), 40–49 years ( $n=17$ ; mean age:  $44.1 \pm 3.2$  years, 11 males) and  $\geq 50$  years of age ( $n=25$ , mean age:  $59.2 \pm 6.4$  years, 14 males).

**Results:** End-diastolic TA diameter ( $2.2 \pm 0.3$  vs.  $2.5 \pm 0.3$  cm,  $P < 0.05$ ), area ( $7.1 \pm 1.3$  vs.  $8.1 \pm 1.7$  cm<sup>2</sup>,  $P < 0.05$ ) and perimeter ( $10.3 \pm 0.9$  vs.  $11.0 \pm 1.2$  cm,  $P < 0.05$ ) were lower in females than in males in the 18–29 year-old group and TA area ( $6.1 \pm 0.8$  vs.  $8.0 \pm 1.2$  cm<sup>2</sup>,  $P < 0.05$ ) and TA perimeter ( $9.7 \pm 0.8$  vs.  $11.0 \pm 0.9$  cm,  $P < 0.05$ ) were lower in females than in males in the 40–49 year-old group. End-systolic TA diameter were lower in females than in males in the 18–29 year-old group ( $1.8 \pm 0.2$  vs.  $1.9 \pm 0.3$  cm,  $P < 0.05$ ) and TA area ( $4.7 \pm 0.3$  vs.  $6.3 \pm 1.2$  cm<sup>2</sup>,  $P < 0.05$ ) and TA perimeter ( $8.6 \pm 0.4$  vs.  $9.5 \pm 0.9$  cm,  $P < 0.05$ ) were lower in females than in males in the 40–49 year-old group. TA fractional area change was found to be reduced in the 40–49 year-old group as compared to the 30–39 year-old group ( $21.7\% \pm 8.7\%$  vs.  $29.2\% \pm 10.0\%$ ,  $P < 0.05$ ).

**Conclusions:** 3DSTE is a novel method for non-invasive assessment of TA dimensions and functional properties. Results highlight the importance of age- and gender-specific reference values in case of TA diameter, area and perimeter and calculated functional features respecting the cardiac cycle.

**Keywords:** Healthy; tricuspid; annulus; three-dimensional echocardiography; speckle-tracking; dimension

Submitted Jan 27, 2022. Accepted for publication Oct 19, 2022.

doi: 10.21037/qims-22-88

View this article at: <https://dx.doi.org/10.21037/qims-22-88>

## Introduction

Three-dimensional (3D) speckle-tracking echocardiography (STE) is a relatively new non-invasive imaging modality with the ability to determine valvular dimensions and functional properties in addition to simultaneous chamber quantifications (1-6). 3DSTE is using a block-matching algorithm and merges advantages of 3D echocardiography (visualizing the heart as a 3D organ) and speckle-tracking echocardiography (quantitative featuring of wall contractility by strain and rotational parameters), and became clinically available in the early 2000s (1-4). Recently, normal reference values of 3DSTE-derived left ventricular (LV) (7-9), left atrial (LA) (10,11) and right atrial (RA) (12,13) and mitral annular (MA) (14) dimensions and functional properties were determined in the MAGYAR-Healthy Study (3).

The apparatus of the tricuspid valve (TV) is a complex structure between the RA and the right ventricle (RV) consisting of anterior, posterior and septal leaflets inserted in the fibrous tricuspid annulus (TA) and connected to the papillary muscle via the chordae tendinae (15). The TV guides blood flow from the RA to the RV and prevents backflow during systole (15,16). More and more studies are focusing on the importance of accurate assessment of the tricuspid valve, as new therapeutic strategies emerge for certain disorders affecting the right heart including pulmonary hypertension and congenital heart diseases. Therefore, the aim of the present study was to determine the normal reference values of 3DSTE-derived TA dimensions and functional properties. Additional aim of the study was to determine whether there is age- and gender-dependency. Our aim was to evaluate the reproducibility and feasibility of 3DSTE-derived TA measurements as well. We present the following article in accordance with the STROBE reporting checklist (available at <https://qims.amegroups.com/article/view/10.21037/qims-22-88/rc>).

## Methods

### Subject population

A total of 156 healthy adults who had no symptoms were involved in the present retrospective cohort study. Subjects were recruited on a voluntary basis between 2011–2015, and were examined at the outpatient clinic of the Department of Medicine, University of Szeged, Hungary. From this population, 28 subjects were excluded due to inferior image

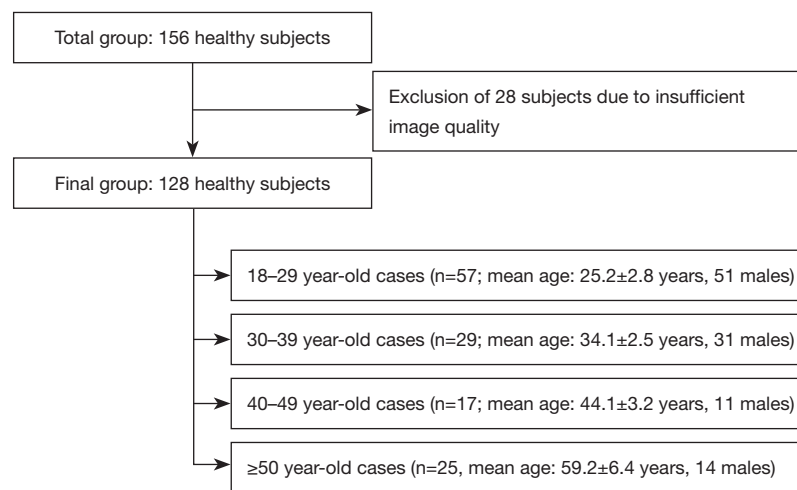
quality for 3DSTE measurement. The remaining healthy population consisted of 128 subjects (age:  $35.4 \pm 12.5$  years, 72 males). Only subjects who had no valvular regurgitation more severe than grade 1 in any valves and who had no significant valvular stenosis were enrolled in the study. None of them had any known disease or pathological state, or received any medication which could affect the results. Nothing abnormal was found with routine electrocardiography and two-dimensional Doppler echocardiography of the subjects. This subject population was further divided into the following categories based on age (*Figure 1*):

- ❖ 18–29 years of age (n=57; mean age:  $25.2 \pm 2.8$  years, 51 males)
- ❖ 30–39 years of age (n=29; mean age:  $34.1 \pm 2.5$  years, 31 males)
- ❖ 40–49 years of age (n=17; mean age:  $44.1 \pm 3.2$  years, 11 males)
- ❖ and  $\geq 50$  years of age (n=25, mean age:  $59.2 \pm 6.4$  years, 14 males).

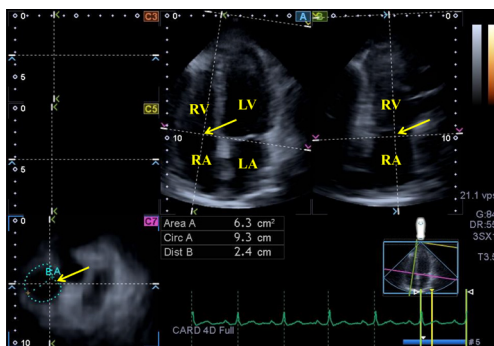
The presented results are part of the MAGYAR-Healthy (Motion Analysis of the heart and Great vessels by three-dimensional speckle-tracking echocardiography in Healthy subjects) Study, an aim of which was to determine the normal reference values of 3DSTE-derived parameters in healthy adults ('Magyar' means 'Hungarian' in Hungarian language). Institutional and Regional Human Biomedical Research Committee of University of Szeged, Hungary approved the study (No. 71/2011); the study complied with the Declaration of Helsinki (as revised in 2013). Informed consent was given by all subjects.

### Two-dimensional Doppler echocardiography

Routine 2D Doppler echocardiography was performed before the 3DSTE in all subjects using the available guidelines. Cardiac chamber quantifications and valvular assessments were performed by the same observers (ÁK, RG) using the same commercial Toshiba Artida<sup>TM</sup> echocardiographic tool (Toshiba Medical Systems, Tokyo, Japan) attached to a PST-30BT (1–5 MHz) phased-array transducer in accordance with the guidelines (17). Routine LA and LV dimensions and LV ejection fraction were calculated together with mitral and tricuspid annular plane systolic excursion (MAPSE and TAPSE, respectively) and RV fractional area change (RV-FAC). Doppler echocardiography was used for valvular assessments and to determine mitral inflow velocities (17).



**Figure 1** Total number of cases, excluded subjects and distribution of remaining cases in the subgroups.



**Figure 2** Extract from a three-dimensional full-volume dataset showing the tricuspid annulus (TA) in a healthy subject is presented: (A) apical four-chamber view, (B) apical two-chamber view and (C7) a cross sectional view at the level of the TA optimized in apical four- and two-chamber views. The yellow arrow represents the TA plane in the long- (A,B) and short-axis (C7) images. ‘En-face view’ of the TA is demonstrated in image C7 (see yellow arrow). LA, left atrium; LV, left ventricle; RA, right atrium; RV, right ventricle; TA, tricuspid annulus; Area, TA area; Circ, TA perimeter; Dist, TA diameter.

### Three-dimensional speckle-tracking echocardiography

The same Toshiba Artida™ echocardiographic machine (Toshiba Medical Systems, Tokyo, Japan) was used for 3DSTE attached to a PST-25SX matrix-array transducer (1-4). All subjects were in sinus rhythm, which was required to be able to perform the 3DSTE. First, a full volume 3D ‘echocloud’ was acquired from the apical window, then a special software (3D Wall Motion Tracking, version 2.7,

Toshiba Medical Systems, Tokyo, Japan) was used for off-line analysis. Lateral and septal TA endpoints in AP2CH and AP4CH views were optimized, then TA dimensions were determined in the C7 short-axis view (Figure 2) (6,18,19):

TA dimensions were measured in end-systole and end-diastole:

- ❖ TA diameter (TAD) was defined as the perpendicular line drawn from the peak of TA curvature to the opposite side of the TA border,
- ❖ TA area (TAA) was assessed by planimetry,
- ❖ TA perimeter (TAP) was evaluated by planimetry, as well.

TA functional properties were calculated using end-systolic and end-diastolic TAD and TAA:

- ❖ TA fractional shortening (TAFS) =  $[\text{end-diastolic TAD} - \text{end-systolic TAD}] / \text{end-diastolic TAD} \times 100$
- ❖ TA fractional area change (TAFAC) =  $[\text{end-diastolic TAA} - \text{end-systolic TAA}] / \text{end-diastolic TAA} \times 100$ .

### Statistical analysis

SPSS software was used (SPSS Inc., Chicago, IL, USA) for the statistical analyses. While continuous variables were presented as mean  $\pm$  standard deviation, categorical data were demonstrated in frequencies and percentage.  $P > 0.05$  was considered to be statistically significant. Shapiro-Wilks test was used to test normality of distribution: normally distributed datasets were assessed by Student’s *t*-test, while not-normally distributed datasets were analysed by

**Table 1** Demographic and two-dimensional echocardiographic data

Variables	Data
n	128
Age (years)	35.4±12.5
Male gender (%)	72 (56)
Two-dimensional echocardiography	
Left atrium (mm)	37.4±3.6
Left ventricular end-diastolic diameter (mm)	48.0±3.5
Left ventricular end-diastolic volume (mL)	105.7±22.7
Left ventricular end-systolic diameter (mm)	32.1±3.3
Left ventricular end-systolic volume (mL)	37.8±9.0
Interventricular septum (mm)	9.2±1.2
Left ventricular posterior wall (mm)	9.3±1.4
Left ventricular ejection fraction (%)	64.6±3.9
Mitral annular plane systolic excursion (mm)	18.2±3.1
Tricuspid annular plane systolic excursion (mm)	23.1±2.5
Right ventricular fractional area change (%)	46.2±5.2
Three-dimensional speckle-tracking echocardiography	
End-diastolic TAD (cm)	2.4±0.3
End-diastolic TAA (cm <sup>2</sup> )	7.5±1.7
End-diastolic TAP (cm)	10.6±1.2
End-systolic TAD (cm)	1.9±0.3
End-systolic TAA (cm <sup>2</sup> )	5.5±1.5
End-systolic TAP (cm)	9.2±1.1
TAFAC (%)	26.4±12.3
TAFS (%)	20.8±10.8

Data are presented as mean ± standard deviation and number (frequency). TAD, tricuspid annular diameter; TAA, tricuspid annular area; TAP, tricuspid annular perimeter; TAFAC, tricuspid annular fractional area change; TAFS, tricuspid annular fractional shortening.

Mann-Whitney-Wilcoxon test. Levene's test was used to evaluate homogeneity of variances. Categorical variables were analysed by Fisher's exact test. Inter- and intraobserver variability of measurements of TAD, TAA and TAP was tested in 30 randomly selected healthy subjects at rest in end-diastole and end-systole. Agreements were verified using the Bland-Altman method and Pearson's coefficient was calculated for intraobserver and interobserver correlations.

## Results

### *Demographic and two-dimensional echocardiographic data*

2D echocardiographic data of subjects were in the normal range as shown in *Table 1*. None of the healthy adults showed ≥ grade 1 regurgitations or had significant stenosis in any valves. 2D echocardiography-derived LA, LV and RV data did not show significant differences between the age-groups.

### *Age-dependency of 3DSTE-derived TA parameters*

No significant changes were found in end-diastolic TA dimensions between subjects with different age groups, but tendentially lower end-diastolic TAA and TAP with preserved end-systolic TA dimensions were found in older subjects. While TAFS showed a non-significant reduction in patients over the age of 40 years, TAFAC was found to be reduced in the 40–49 year-old group as compared to the 30–39 year-old group (*Table 2, Figures 3,4*). The frame rate of the 3DSTE acquisition for the measurements was 27±3 volumes per second.

### *Gender-dependency of 3DSTE-derived TA parameters*

End-diastolic TAD, TAA and TAP were lower in females than in males in the 18–29 year-old group and TAA and TAP were lower in females than in males in the 40–49 year-old group. End-systolic TAD were lower in females than in males in the 18–29 year-old group and TAA and TAP were lower in females than in males in the 40–49 year-old group (*Figure 3*). TAFS and TAFAC were tendentially higher in females, significant difference could be found between female and male subjects in TAFS in subjects over the age of 50. TAFAC of 30–39 year-old female subjects was significantly increased as compared to that of subjects in all other age groups. TAFS was significantly reduced in 50+ year-old male subjects as compared to that of 18–29 and 30–39 year-old subjects. Changes in TAFS and TAFAC with age and gender are presented in *Figure 4*.

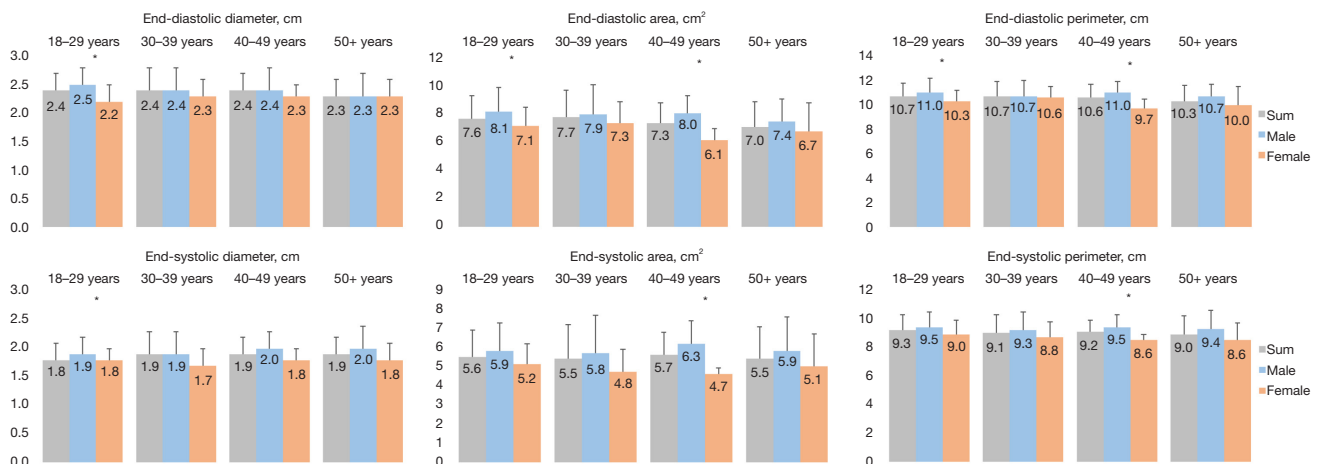
### *Correlations*

TAPSE and RV-FAC did not correlate with any 3DSTE-derived TA dimensions or TA functional properties including TAFAC and TAFS.

**Table 2** Tricuspid annular dimensions and functional parameters in different age groups

Parameters	18–29 year-old subjects (n=57)	30–39 year-old subjects (n=29)	40–49 year-old subjects (n=17)	50+ year-old subjects (n=25)
<b>End-diastole</b>				
TAD (cm)	2.4±0.3	2.4±0.4	2.4±0.3	2.3±0.3
TAA (cm <sup>2</sup> )	7.6±1.6	7.7±1.9	7.3±1.4	7.0±1.8
TAP (cm)	10.7±1.1	10.7±1.2	10.6±1.1	10.3±1.3
<b>End-systole</b>				
TAD (cm)	1.8±0.3	1.9±0.4	1.9±0.3	1.9±0.3
TAA (cm <sup>2</sup> )	5.6±1.4	5.5±1.8	5.7±1.2	5.5±1.7
TAP (cm)	9.3±1.1	9.1±1.3	9.2±0.8	9.0±1.3
<b>Functional parameters</b>				
TAFAC	26.8±10.0	29.2±10.0	21.7±8.7*	25.3±19.4
TAFS	21.4±9.5	21.6±8.1	17.2±7.5	18.2±7.9

Data are presented as mean ± standard deviation. \*P<0.05 between age groups of 30–39 year-old subjects and 40–49 year-old subjects. TAD, tricuspid annular diameter; TAA, tricuspid annular area; TAP, tricuspid annular perimeter; TAFAC, tricuspid annular fractional area change; TAFS, tricuspid annular fractional shortening.



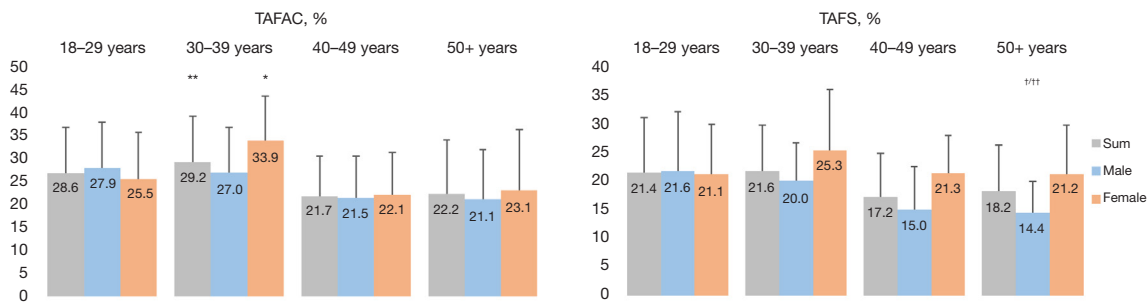
**Figure 3** Age- and gender-dependency of tricuspid annular end-diastolic and end-systolic diameter, area and perimeter in subjects in different age groups. Significant differences (P<0.05) could be demonstrated in tricuspid annular dimensions between males and females in certain age groups (see asterisks).

**Feasibility of 3DSTE-derived TA measurements**

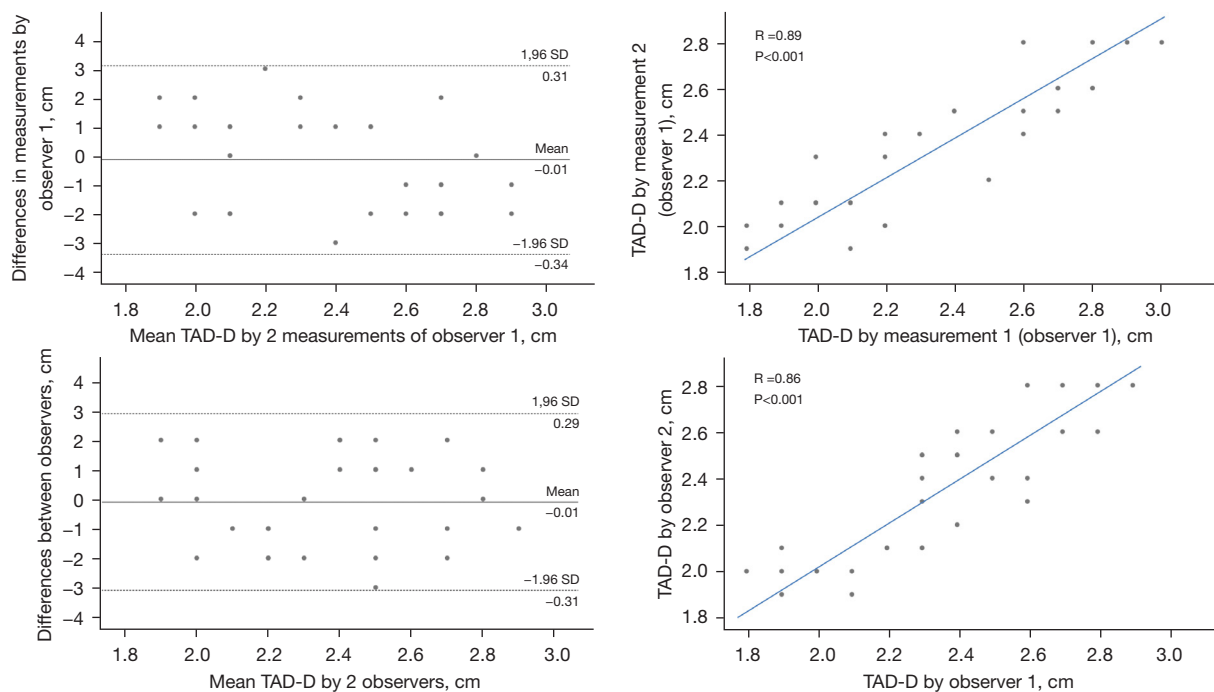
The original study comprised 156 healthy adults, from which 28 subjects were excluded due to insufficient image quality. The overall feasibility was found to be 82.1%.

**Reproducibility of 3DSTE-derived TA measurements**

Mean ± standard deviation of the difference in values obtained by two observers in case of the measurements of end-diastolic and end-systolic TAD, TAA and TAP with a correlation coefficient between these independent



**Figure 4** Age- and gender-dependency of tricuspid annular functional properties in subjects in different age groups. Tricuspid annular fractional area change of 30–39 year-old female subjects was significantly increased as compared to that of subjects in all other age groups (see asterisk). Difference in tricuspid annular fractional area change was significant comparing 30–39 year-old subjects and 40–49 year-old subjects (see double asterisk). Tricuspid annular fractional shortening was significantly reduced in 50+ year-old male subjects as compared to that of 18–29 and 30–39 year-old subjects (see cross). Gender differences were found in case of tricuspid annular fractional shortening in 50+ year-old subjects (see double crosses). TAFAC, tricuspid annular fractional area change; TAFS, tricuspid annular fractional shortening.



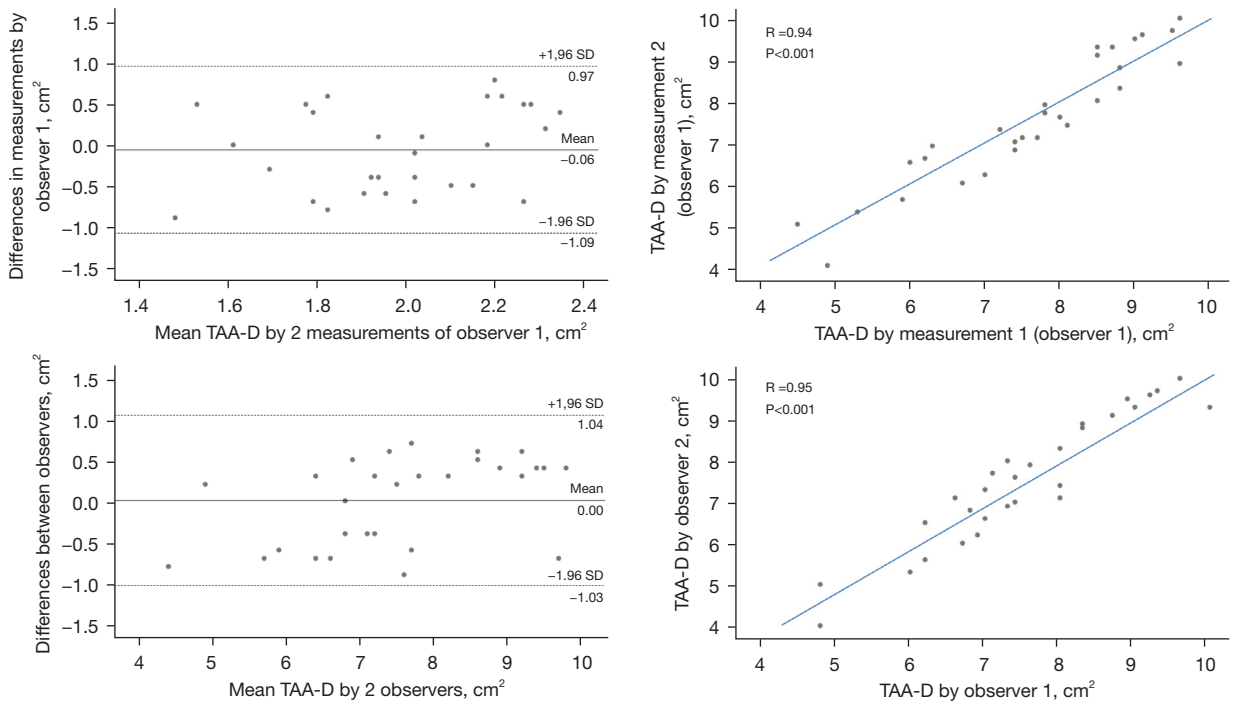
**Figure 5** Intra-observer (upper graphs) and inter-observer (lower graphs) agreements and correlations for measuring end-diastolic tricuspid annular diameter (TAD-D) by three-dimensional speckle tracking echocardiography are presented.

measurements are presented in *Figures 5-10* (interobserver agreement). Mean  $\pm$  standard deviation of the difference in values obtained by 2 measurements of the same observer with a correlation coefficient between these independent measurements are demonstrated in *Figures 5-10*, as well (intraobserver agreement).

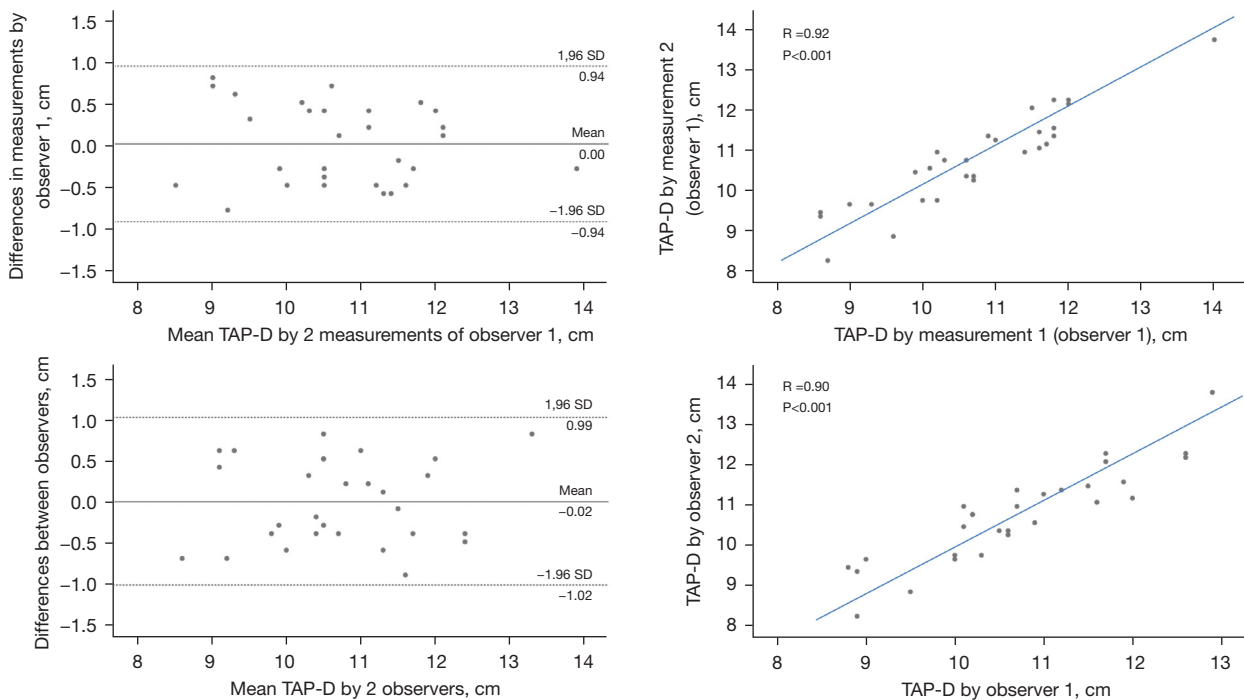
## Discussion

Similarly to the mitral valve, dynamic deformation occur in the TV during the cardiac cycle. Valvular lesions or other cardiovascular diseases could cause disturbed leaflet or TA deformation leading to tricuspid regurgitation. These facts may draw attention to the importance of normal reference

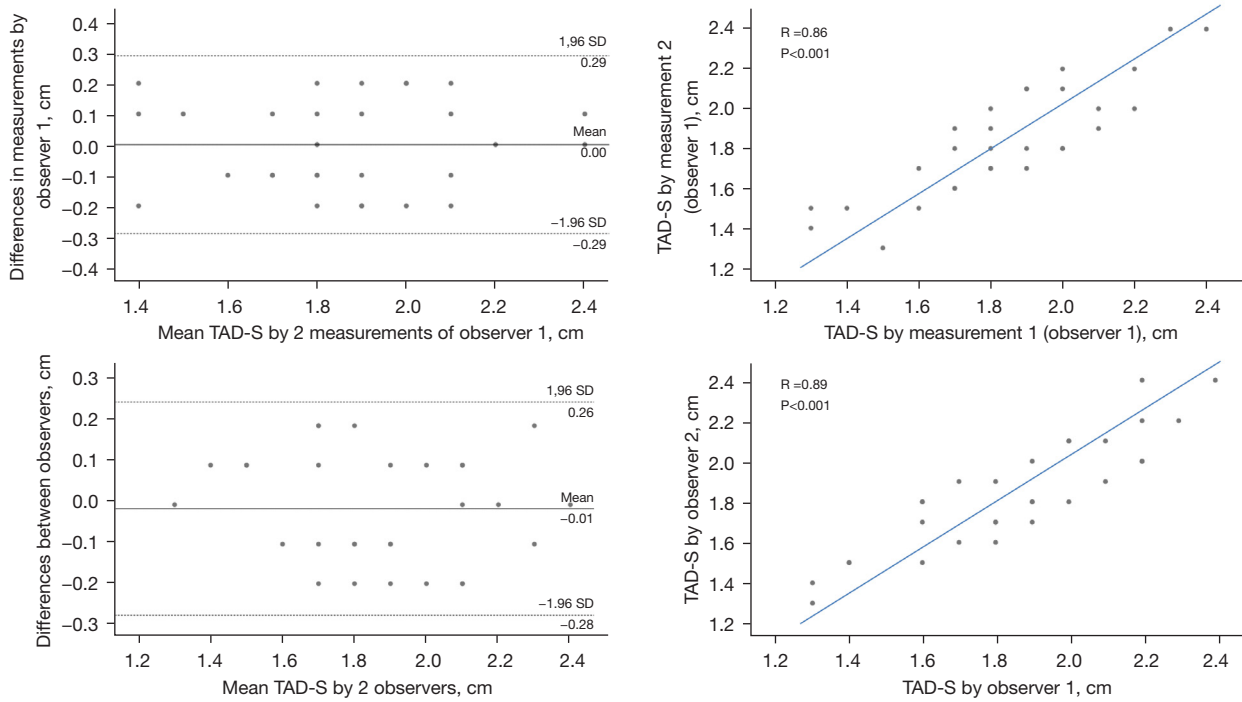




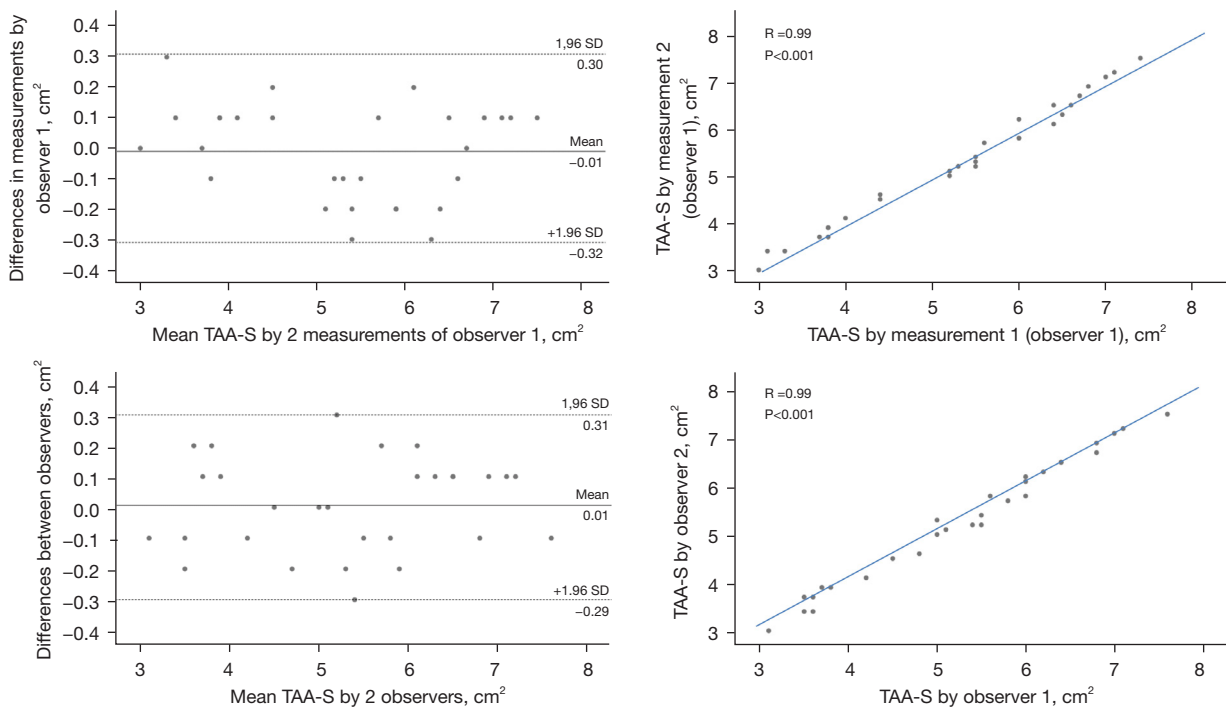
**Figure 6** Intraobserver (upper graphs) and interobserver (lower graphs) agreements and correlations in case of the measurement of end-diastolic tricuspid annular area (TAA-D) by three-dimensional speckle tracking echocardiography are presented.



**Figure 7** Intraobserver (upper graphs) and interobserver (lower graphs) agreements and correlations in case of the measurement of end-diastolic tricuspid annular perimeter (TAP-D) by three-dimensional speckle tracking echocardiography are presented.

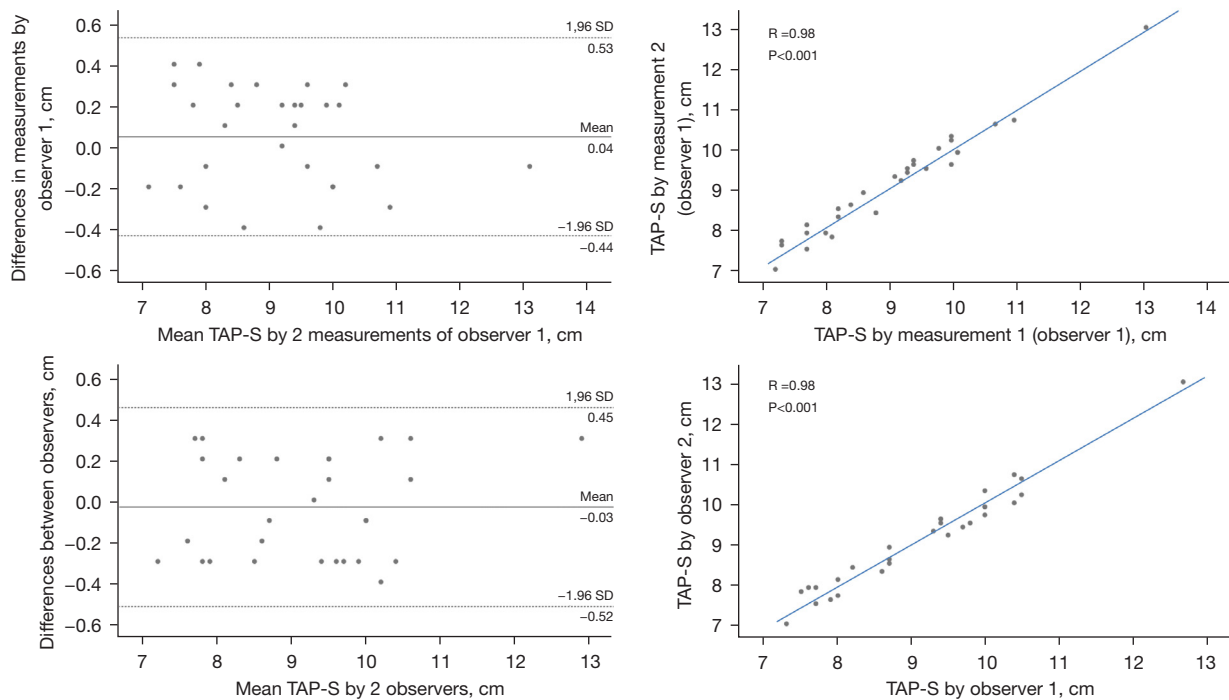


**Figure 8** Intraobserver (upper graphs) and interobserver (lower graphs) agreements and correlations in case of the measurement of end-systolic tricuspid annular diameter (TAD-S) by three-dimensional speckle tracking echocardiography are presented.



**Figure 9** Intraobserver (upper graphs) and interobserver (lower graphs) agreements and correlations in case of the measurement of end-systolic tricuspid annular area (TAA-S) by three-dimensional speckle tracking echocardiography are presented.





**Figure 10** Intraobserver (upper graphs) and interobserver (lower graphs) agreements and correlations in case of the measurement of end-systolic tricuspid annular perimeter (TAP-S) by three-dimensional speckle tracking echocardiography are presented.

values for TA dimensions during the cardiac cycle. Moreover, there is an increasing interest in the non-invasive evaluation of the right heart as recently new treatment options have become available in case of pulmonary hypertension (20). Unfortunately, only limited data are available regarding the normal values of TA dimensions assessed by non-invasive cardiovascular imaging (21–23). Reference values for 2D echocardiography- (21) and cardiac magnetic resonance imaging-derived (22,23) TA dimensions are available, but the more reliable and accurate 3D (speckle-tracking) echocardiographic data are missing from literature. Therefore, this is the first time to define normal reference values of 3DSTE-derived end-diastolic and end-systolic TA dimensions and calculated functional properties together with their age- and gender-dependency in healthy adults.

Compering our results to the recently published results of MA normal reference ranges from the MAGYAR-Healthy Study (14), we found that TA and MA dimensions were similar in end-diastole. TA dimensions proved to be dilated in end-systole compared to MA dimensions, as a result, TAFAC and TAFS were significantly reduced compared to MA functional properties based on similar

calculation methods. Differences were seen in MA and TA dimensions and functional properties and changes were seen in the parameters with age (decades) and gender. Although end-diastolic MA and TA diameters did not show significant change with age (decades), continuous tendentious reduction could be demonstrated in TA area and perimeter, while MA area and perimeter showed an increase-decrease pattern. While dilated end-systolic MA dimensions could be detected in  $\geq 50$  year-old subjects compared to 18–29 year-old subjects, end-systolic TA dimensions did not change with age (decades) (14). Both MAFAC and TAFAC showed reduction in older subjects compared to younger subjects. While MAFS showed a decrease-increase-decrease pattern with age (decades) due to changes in end-systolic MAD, TAFS showed a non-significant reduction over the age of 40 years. Regarding gender, while end-diastolic MA parameters did not show any differences, end-diastolic TA dimensions were lower in young females and in females in the 40–49 year-old group. While end-systolic MA dimensions were lower in young females, lower end-systolic TAD was seen in females in the 18–29 year-old group and TAA and TAP were lower in females in the 40–49 year-old group. MA and TA functional properties were tendentious higher in

females compared to those of males (14).

Several theories could explain these changes in TA dimensions with age and gender and the differences between TA and MA. Aging-associated changes with calcification, increased fluid accumulation, fibrosis, low-grade inflammation, deposition and infiltration of certain molecules could partially explain our findings. Moreover, although healthy subjects were selected to be involved in the present study, subclinical and undetected abnormalities/disorders were not excluded by certain invasive or non-invasive procedures due to the absence of any symptoms. Differences in TA and MA dimensions and functional properties could be elucidated by considering the differences in the left and right ventricles and atria and in their structure, movement, contractility and function, but genetic and epigenetic factors should also be considered. Theoretically, hormonal differences could be responsible for gender differences. However, further studies are needed to confirm these findings and to compare the role of 3DSTE in the evaluation of TA dimensions with other routine imaging methods.

#### **Limitation section**

- ❖ The present study was a retrospective cohort study, differences in parameters were from subjects in different age groups.
- ❖ Quality of 3DSTE-derived images is worse compared to that of 2D echocardiography, which could affect the results (1-4).
- ❖ Using 3DSTE, only 2D-projected TA planimetry could be performed, the special 3D saddle-shape of TV was not evaluated, which could affect the results (1-6).
- ❖ The present study did not aim to assess dimensions, volumetric and functional properties of any cardiac chambers or MA. Moreover, the study did not consider the validation of TA dimensions measured by 3DSTE as its objective either.
- ❖ It was not planned to compare 3D modalities of different vendors in the assessment of TV and TA.
- ❖ In some age-groups, mainly in older ages, only limited number of healthy adults were selected. No subjects over 60 years of age participated in the study due to the presence of TR.
- ❖ It was not aimed to compare the results with subjects

with significant TR. It could be a topic of another paper.

#### **Conclusions**

3DSTE is a novel method for non-invasive assessment of TA dimensions and functional properties. Results highlight the importance of age- and gender-specific reference values for TA diameter, area and perimeter and calculated functional features respecting the cardiac cycle.

#### **Acknowledgments**

*Funding:* None.

#### **Footnote**

*Reporting Checklist:* The authors have completed the STROBE reporting checklist. Available at <https://qims.amegroups.com/article/view/10.21037/qims-22-88/coif>

*Conflicts of Interest:* All authors have completed the ICMJE uniform disclosure form (available at <https://qims.amegroups.com/article/view/10.21037/qims-22-88/coif>). Attila Nemes serves as an unpaid editorial board member of Quantitative Imaging in Medicine and Surgery. The other authors have no conflicts of interest to declare.

*Ethical Statement:* The authors are accountable for all aspects of the work in ensuring that questions related to the accuracy or integrity of any part of the work are appropriately investigated and resolved. The study was conducted in accordance with the Declaration of Helsinki (as revised in 2013). The human research committee of the University of Szeged approved the study (No. 71/2011). Informed consent was given by all patients.

*Open Access Statement:* This is an Open Access article distributed in accordance with the Creative Commons Attribution-NonCommercial-NoDerivs 4.0 International License (CC BY-NC-ND 4.0), which permits the non-commercial replication and distribution of the article with the strict proviso that no changes or edits are made and the original work is properly cited (including links to both the formal publication through the relevant DOI and the license). See: <https://creativecommons.org/licenses/by-nc-nd/4.0/>.

## References

1. Franke A, Kuhl HP. Second-generation real-time 3D echocardiography: a revolutionary new technology. *MedicaMundi* 2003;47:34.
2. Urbano-Moral JA, Patel AR, Maron MS, Arias-Godinez JA, Pandian NG. Three-dimensional speckle-tracking echocardiography: methodological aspects and clinical potential. *Echocardiography* 2012;29:997-1010.
3. Nemes A, Kalapos A, Domsik P, Forster T. Three-dimensional speckle-tracking echocardiography -- a further step in non-invasive three-dimensional cardiac imaging. *Orv Hetil* 2012;153:1570-7.
4. Muraru D, Niero A, Rodriguez-Zanella H, Cherata D, Badano L. Three-dimensional speckle-tracking echocardiography: benefits and limitations of integrating myocardial mechanics with three-dimensional imaging. *Cardiovasc Diagn Ther* 2018;8:101-17.
5. Nemes A, Kovács Z, Kormányos Á, Domsik P, Kalapos A, Piros GÁ, Kemény L, Forster T, Szolnoky G. The mitral annulus in lipedema: Insights from the three-dimensional speckle-tracking echocardiographic MAGYAR-Path Study. *Echocardiography* 2019;36:1482-91.
6. Nemes A, Rác G, Kormányos Á, Ambrus N, Havasi K. Tricuspid annular abnormalities following different surgical strategies in adults with corrected tetralogy of Fallot (Results from the CSONGRAD Registry and MAGYAR-Path Study). *Cardiovasc Diagn Ther* 2021;11:1276-83.
7. Kormányos Á, Kalapos A, Domsik P, Gyenes N, Lengyel C, Nemes A. Normal reference values of left ventricular volumetric parameters in healthy adults-real-life single-center experience from the three-dimensional speckle-tracking echocardiographic MAGYAR-Healthy Study. *Quant Imaging Med Surg* 2021;11:1496-503.
8. Nemes A, Kormányos Á, Kalapos A, Domsik P, Gyenes N, Ambrus N, Lengyel C. Normal reference values of left ventricular strain parameters in healthy adults: Real-life experience from the single-center three-dimensional speckle-tracking echocardiographic MAGYAR-Healthy Study. *J Clin Ultrasound* 2021;49:368-77.
9. Kormányos Á, Kalapos A, Domsik P, Lengyel C, Forster T, Nemes A. Normal values of left ventricular rotational parameters in healthy adults-Insights from the three-dimensional speckle tracking echocardiographic MAGYAR-Healthy Study. *Echocardiography* 2019;36:714-21.
10. Nemes A, Kormányos Á, Domsik P, Kalapos A, Ambrus N, Lengyel C. Normal reference values of left atrial volumes and volume-based functional properties using three-dimensional speckle-tracking echocardiography in healthy adults (Insights from the MAGYAR-Healthy Study). *J Clin Ultrasound* 2021;49:49-55.
11. Nemes A, Kormányos Á, Domsik P, Kalapos A, Lengyel C, Forster T. Normal reference values of three-dimensional speckle-tracking echocardiography-derived left atrial strain parameters (results from the MAGYAR-Healthy Study). *Int J Cardiovasc Imaging* 2019;35:991-8.
12. Nemes A, Kormányos Á, Domsik P, Kalapos A, Ambrus N, Lengyel C. Normal reference values of three-dimensional speckle-tracking echocardiography-derived right atrial volumes and volume-based functional properties in healthy adults (Insights from the MAGYAR-Healthy Study). *J Clin Ultrasound* 2020;48:263-8.
13. Nemes A, Kormányos Á, Domsik P, Kalapos A, Ambrus N, Lengyel C, Forster T. Normal reference values of right atrial strain parameters using three-dimensional speckle-tracking echocardiography (results from the MAGYAR-Healthy Study). *Int J Cardiovasc Imaging* 2019;35:2009-18.
14. Nemes A, Kormányos Á, Domsik P, Kalapos A, Gyenes N, Lengyel C. Normal reference values of three-dimensional speckle-tracking echocardiography-derived mitral annular dimensions and functional properties in healthy adults: Insights from the MAGYAR-Healthy Study. *J Clin Ultrasound* 2021;49:234-9.
15. Putthapiban P, Amini MR, Abudayyeh I. Anatomy of the Tricuspid Valve and Pathophysiology of Tricuspid Regurgitation. *Interv Cardiol Clin* 2022;11:1-9.
16. Khoiy AK, Asgarian KT, Loth F, Amini R. Dilation of tricuspid valve annulus immediately after rupture of chordae tendineae in ex-vivo porcine hearts. *PLoS One* 2018;13:e0206744.
17. Lang RM, Badano LP, Mor-Avi V, Afilalo J, Armstrong A, Ernande L, Flachskampf FA, Foster E, Goldstein SA, Kuznetsova T, Lancellotti P, Muraru D, Picard MH, Rietzschel ER, Rudski L, Spencer KT, Tsang W, Voigt JU. Recommendations for cardiac chamber quantification by echocardiography in adults: an update from the American Society of Echocardiography and the European Association of Cardiovascular Imaging. *Eur Heart J Cardiovasc Imaging* 2015;16:233-70.
18. Anwar AM, Geleijnse ML, Soliman OI, McGhie JS, Frowijn R, Nemes A, van den Bosch AE, Galema TW, Ten Cate FJ. Assessment of normal tricuspid valve anatomy in adults by real-time three-dimensional echocardiography.

- Int J Cardiovasc Imaging 2007;23:717-24.
19. Anwar AM, Soliman OI, Nemes A, van Geuns RJ, Geleijnse ML, Ten Cate FJ. Value of assessment of tricuspid annulus: real-time three-dimensional echocardiography and magnetic resonance imaging. *Int J Cardiovasc Imaging* 2007;23:701-5.
  20. Kaemmerer AS, Gorenflo M, Huscher D, Pittrow D, Ewert P, Pausch C, et al. Medical treatment of pulmonary hypertension in adults with congenital heart disease: updated and extended results from the International COMPERA-CHD Registry. *Cardiovasc Diagn Ther* 2021;11:1255-68.
  21. Dwivedi G, Mahadevan G, Jimenez D, Frenneaux M, Steeds RP. Reference values for mitral and tricuspid annular dimensions using two-dimensional echocardiography. *Echo Res Pract* 2014;1:43-50.
  22. Zhan Y, Debs D, Khan MA, Nguyen DT, Graviss EA, Shah DJ. Normal Reference Values and Reproducibility of Tricuspid Annulus Dimensions Using Cardiovascular Magnetic Resonance. *Am J Cardiol* 2019;124:594-8.
  23. Ricci F, Aung N, Gallina S, Zemrak F, Fung K, Bisaccia G, Paiva JM, Khanji MY, Mantini C, Palermi S, Lee AM, Piechnik SK, Neubauer S, Petersen SE. Cardiovascular magnetic resonance reference values of mitral and tricuspid annular dimensions: the UK Biobank cohort. *J Cardiovasc Magn Reson* 2020;23:5.

**Cite this article as:** Nemes A, Kormányos Á, Rác G, Ruzsa Z, Ambrus N, Lengyel C. Normal reference values of tricuspid annular dimensions and functional properties in healthy adults using three-dimensional speckle-tracking echocardiography (Insights from the MAGYAR-Healthy Study). *Quant Imaging Med Surg* 2022. doi: 10.21037/qims-22-88