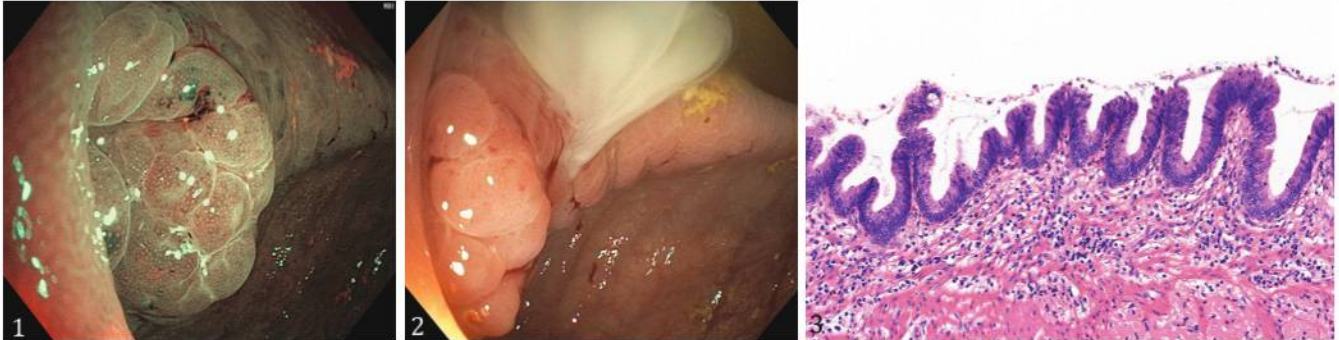


Appendiceal Mucinous Neoplasm Appearance on NBI Colonoscopy

Péter Bacsur¹, Tamás Resál¹, Klaudia Farkas¹, Szabolcs Ábrahám², Tamás Molnár¹

1) Department of Medicine, Albert Szent-Györgyi Medical School, University of Szeged, Szeged; 2) Department of Surgery, Albert Szent-Györgyi Medical School, University of Szeged, Szeged, Hungary



A 71-year-old woman presented to the general physician with recent weight loss and uncertain pain located to the right inguinal region, starting 8 weeks before. She did not report fever or change in the bowel habits. There was no familial history of colon polyps, cancer or inflammatory bowel diseases. Physical examination and laboratory tests excluded an acute disease. C-reactive protein (CRP) was slightly elevated (2.6 mg/l), leukocyte number and hemoglobin level were in normal range. Abdominal ultrasonography was negative. Because of a fecal blood test positivity, the patient was referred to the Gastroenterology Department for a colonoscopy. Colonoscopy revealed a polypoid, edematous lesion at the base of the coecum, abutting and extending into the appendiceal orifice with regular pit pattern on the surface (Fig. 1). During biopsy acquisition a purulent/mucinous discharge from the appendiceal orifice was noted (Fig. 2). No other abnormalities were found in the colon. Control blood test obtained immediately after colonoscopy showed leukocytosis, but not CRP elevation. Abdominal/pelvic CT imaging reported appendicolithiasis with focal thickening and obstructive dilatation of the appendix (Supplementary file). After referring the patient to the Surgical Department, urgent appendectomy and coecum resection were performed. Histology depicted few areas of a slit-like mucinous neoplasia with neutrophilic granulocytic infiltration with massive acute inflammatory infiltration, not reaching the subserosa, suggestive for a low-grade appendiceal mucinous neoplasm (AMN) (Fig. 3, H&E, 200x). Peritoneal mucinous - pseudomyxoma-like image was not identified.

The diagnosis of acute appendicitis is predominantly based on typical clinical features usually confirmed by laboratory or radiological findings [1]. However, few case-reports have described silent appendicitis diagnosed via endoscopy [2-4]. According to our knowledge, there is no previous report on AMN suspected at endoscopy. However, leakage after targeted biopsy can be diagnostic for either inflammation or AMN. Older age

could predispose to silent appendicitis, and in such uncertain cases an underlying malignancy should be considered.

Corresponding author: Tamás Molnár, molnar.tamas@med.u-szeged.hu

Conflicts of interest: None to declare.

Acknowledgements: The authors thanks Béla Vasas (Pathology Dept) and Anita Tóth (Radiology Dept), (Albert Szent-Györgyi Medical School, University of Szeged) for their contribution to case management. Supporting research grants: National Research, Development and Innovation Office (Grant ID: 125377, 129266 and 134863), National Excellence Programme (20391-3/2018/FEKUSTRAT to FK), New National Excellence Program of the Ministry of Human Capacities (UNKP-19-4-SZTE-44, UNKP-20-5-SZTE-161 to FK and UNKP-21-3-SZTE-49 to BP) and Janos Bolyai Research Grant (BO/00598/19/5) and Géza Hetényi Research Grant (to FK) by the Faculty of Medicine, University of Szeged.

Supplementary material: To access the supplementary material visit the online version of the *J Gastrointestin Liver Dis* at <http://dx.doi.org/10.15403/jgld-4478>

REFERENCES

- Gorter RR, Eker HH, Gorter-Stam MAW, et al. Diagnosis and management of acute appendicitis. EAES consensus development conference 2015. *Surg Endosc* 2016;30:4668-4690. doi:10.1007/s00464-016-5245-7
- Tursi A. Endoscopic diagnosis of appendicitis. *Intern Med* 2013;52:1141. doi:10.2169/internalmedicine.52.0012
- Zimmer V. Gastrointestinal: An uncommon finding during screening colonoscopy: silent appendicitis. *J Gastroenterol Hepatol* 2021;36:1387. doi:10.1111/jgh.15338
- Duarte P, Ramos R, Casteleiro Alves C. Suppurative appendicitis at colonoscopy. *Endoscopy* 2010;42 Suppl 2:E104. doi:10.1055/s-0029-1243908