Author Query Form

Journal: *Cardiovascular Diagnosis and Therapy*
Manuscript ID: CDT-22-207
doi: 10.21037/cdt-22-207
Title: Left ventricular rotational abnormalities in patients with transposition of the great arteries late after atrial switch operation: detailed analysis from the CSONGRAD Registry and MAGYARPath Study
Corresponding author: Attila Nemes

Dear Dr. Nemes,

The proof of your manuscript is attached on the following pages. Please read through the document carefully to check for accuracy, reference citations, and figures and tables. Please also be aware a professional copyeditor may have edited your manuscript to comply with the CDT style requirements.

In addition to proofing the article, the following queries have arisen during the preparation of your paper. Please address the queries listed below by making the appropriate changes in the text.

If you have any other revisions that you would like to make, this will be the last opportunity to do so before the article is published. In particular, please ensure that the author's names and affiliations have been identified correctly, and the address of the corresponding author is correct.

If the changes cannot be easily described through email, please annotate this proof according to the annotation guidelines as detailed on the following page.

Query Reference	Query	Author's response
Q1	Please note that alterations cannot be made after you have approved for publication, irrespective of whether it is Online First.	
Q2	Please check the authors' names [Author SURNAMES (family names) have been highlighted in red], the affiliations, and the correspondence details.	
Q3	Please check the Acknowledgements section and the Footnote.	
Q4	For standardization, the texts/data appeared on the figures may be re-formatted during typesetting. Please check if all the texts/data are correct.	
Q5	Please have a final double check for all the details including any data or numbers described in the text, abstract, figure and table (e.g., percentage).	
Q6	As the Helvetica Neue LT Pro font is used in typesetting, where the letter "c", "o" and "I", "l" may look similar in normal reading mode, please zoom in on the text for distinguishing.	
Q7	Please confirm the G.R. in Contributions.	
Q8	Table 1: Please add a header to 1st column.	

Once you have completed your revisions and/or addressed all the queries, or if you are satisfied with the proof in its existing form, please email: yuanj@amegroups.com.

To ensure the timely publication of your article, please respond within 48 hours.

Making corrections

Use Adobe Reader – available for free from http://get.adobe.com/reader/ – to open the attached document.

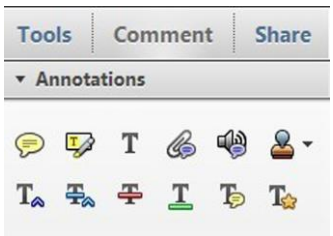

Figure 1 Adobe Acrobat X

Adobe Professional 7:
Tools → Commenting → show Commenting Toolbar

Adobe Reader 8:
Tools → Comments & Markup → show Comments and Markup Toolbar

Adobe Reader 10 and above:
Comment → choose either Sticky Note or Highlight Text

In-text edits	**Select the appropriate symbol and then click and drag over the text to be modified.** **Replace** : denotes where the text should be replaced with an alternative option **Strikethrough** : crosses out the text **Underline** : underlines the text **Add note to text** : links selected text with a pop-up note
Sticky notes	**To make a note:** choose the Sticky Note option and then click on a desired location **Changing the name:** double-click and choose Options → Sticky Note Properties → General → insert desired name **To move:** click anywhere (apart from the text field) and drag **To resize:** click on the right or left hand order and drag **To close:** click the box on the upper right corner; this does NOT delete your note **To delete:** click and press the Delete keyboard button or right click and select delete from the drop-down menu
Highlighting	**This allows you can highlight parts of the text.** **To highlight:** select Highlight and then click and drag over the text to be highlighted. When finished, click on Highlight again to turn off the option. **To change the colour:** double-click on the highlighted text and choose Options → Properties → Appearance → Color

Saving your changes:
Click on *File* → *Save* before closing the document.

For more detailed instructions on using Adobe Acrobat, please refer to
http://www.adobe.com/support/acrobat/gettingstarted/

Original Article

Left ventricular rotational abnormalities in patients with transposition of the great arteries late after atrial switch operation: detailed analysis from the CSONGRAD Registry and MAGYAR-Path Study

Attila Nemes, Árpád Kormányos, Zoltán Ruzsa, Nóra Ambrus, Kálmán Havasi

Department of Medicine, Albert Szent-Györgyi Medical School, University of Szeged, Szeged, Hungary

Contributions: (I) Conception and design: A Nemes; (II) Administrative support: N Ambrus; (III) Provision of study materials or patients: A Nemes; (IV) Collection and assembly of data: G.R., ÁKormányos; (V) Data analysis and interpretation: G.R., ÁKormányos, A Nemes; (VI) Manuscript writing: All authors; (VII) Final approval of the manuscript: All authors.

Correspondence to: Attila Nemes, MD, PhD, DSc, FESC. Department of Medicine, Albert Szent-Györgyi Medical School, University of Szeged, H-6725 Szeged, Semmelweis street 8, Hungary. Email: nemes.attila@med.u-szeged.hu.

Background: Dextro-transposition of the great arteries (dTGA) is one of the most common cyanotic congenital heart defects, when the origins of the main arteries are switched in position. The present retrospective cohort study aimed three-dimensional speckle-tracking echocardiography-derived determination of apical and basal morphologic left ventricular (mLV) rotations and twist in adults with dTGA late after atrial switch. It was also purposed to compare whether differences in mLV rotational parameters were present in Senning- and Mustard-operated subjects.

Methods: Sixteen dTGA patients were willing to participate late after atrial switch in this study, however, 6 subjects were excluded due to inferior image quality. The remaining group of 10 dTGA patients had a mean age of 29.4±8.8 years (5 males). Their clinical data were from the CSONGRAD Registry. Their results were compared to 24 age- and gender-matched healthy controls with a mean age of 34.4±12.6 years (14 males).

Results: From the dTGA patient population, only 5 out of 10 subjects had normally directed mLV rotational mechanics, 5 dTGA cases had significant mLV rotational abnormality with counterclockwise mLV basal rotation in 4 patients (mLV rigid body rotation, mLV-RBR). One patient had complete reversal of apical and basal mLV rotations. Compared to the matched healthy controls, dTGA patients showed mLV-RBR significantly more frequently (50% *vs.* 0%, P=0.0009) regardless of the fact whether Senning- or Mustard-procedure was performed. dTGA patients with normally directed mLV rotational mechanics proved to have increased mLV basal rotation (−7.9±4.1 *vs.* −3.7±1.9 degree, P=0.001) with preserved mLV twist (16.4±3.3 *vs.* 14.0±4.1 degree, P=ns) as compared to matched controls.

Conclusions: Significant mLV rotational abnormalities are present in dTGA late after atrial switch procedures including mLV-RBR and reversed mLV twist. In dTGA patients with normally directed mLV rotational mechanics, mLV basal rotation is increased with preserved mLV twist. Some differences in mLV rotational abnormalities are present between Senning- and Mustard-procedures.

Keywords: Left ventricular; rotation; three-dimensional; echocardiography; transposition of the great arteries

Submitted Apr 25, 2022. Accepted for publication Aug 16, 2022.
doi: 10.21037/cdt-22-207
View this article at: https://dx.doi.org/10.21037/cdt-22-207

Introduction

Dextro-transposition of the great arteries (dTGA) is one of the most common cyanotic congenital heart defect (CHD), when the origins of the main arteries are switched (reversed or transposed) in position (1,2). Namely, the aorta arises from the morphologic right ventricle (mRV), while the pulmonary artery arises from the morphologic left ventricle (mLV), thus creating an mRV-based systemic circulation and an mLV-engined pulmonary circulation not communicating with each other (1,2). Surgical treatment for dTGA is possible, it was formerly performed as atrial redirection (switch), and many of these patients are still alive today (3). Nevertheless, the atrial switch operations, Senning- and Mustard-procedures were the method of choice until the early 1990s, when arterial switch procedures (ASO) emerged as an anatomically and physiologically appropriate solution (4). With the Senning-procedure, a baffle is created using the atrial septum to reroute blood flow from the caval veins to the pulmonary circulation via the mitral valve and mLV. During the Mustard-procedure, following excision of the atrial septum, a conduit is produced from prosthetic tissue (4). These techniques however do not correct the pathological states at the ventricular level (3,4).

Evaluation of myocardial mechanics could help understanding adaptations to certain conditions. mLV rotational mechanics (twist) is a significant contribution to LV function, in normal circumstances, the mLV apex has counterclockwise rotation, while the mLV base has a clockwise rotation leading to a towel-wringing-like movement of the mLV responsible for significant part of mLV ejection (5,6). In corrected dTGA, mLV plays a special role compared to its role in the physiological circulation. However, only limited information is available at this moment about mLV rotational mechanics in dTGA (7,8). Due to recent developments in cardiovascular imaging, three-dimensional speckle-tracking echocardiography (3DSTE) is considered to be a method of choice for quantification of mLV rotations as a non-invasive validated technique (9-12). Therefore, 3DSTE-derived determination of mLV rotational mechanics in adults with dTGA late after Senning- and Mustard-procedures was purposed. In addition, it was purposed to compare whether differences in mLV rotational parameters were present in Senning- and Mustard-operated subjects. We present the following article in accordance with the STROBE reporting checklist (available at https://cdt.amegroups.com/article/view/10.21037/cdt-22-207/rc).

Methods

Patient population

Clinical data of dTGA patients originate from the CSONGRAD Registry (Registry of C(S)ONGenital caRdiAc Disease patients at the University of Szeged), which was created to summarize clinical variables and parameters of CHD patients treated and cared for at the Departments of Pediatrics, Cardiology and Heart Surgery at the University of Szeged, Hungary (4). From this pool of patients, only 196 infants with dTGA were operated on with non-arterial switch surgery between 1961–2013, from which Senning-procedure was performed in 37 patients and Mustard-procedure was performed in 48 cases. From this pool, 16 dTGA patients were willing to participate in this study late after atrial switch, however, 6 subjects were not included due to inferior image quality. The remaining group of 10 dTGA patients had a mean age of 29.4±8.8 years (5 males). All these patients were followed by the Outpatient Clinics of the Division of Cardiology at the University of Szeged (*Figure 1*). Their results were compared to those of 24 healthy controls, who were age- and gender-matched (age: 34.4±12.6 years, 14 males). None of the healthy subjects had any known disorder, pathological state, used any drug or had any clinical condition, which could affect the results. Laboratory, routine electrocardiographic and echocardiographic findings were normal as well. In all cases, a complete two-dimensional (2D) Doppler echocardiography extended with 3DSTE data acquisition was performed according to recent guidelines and practices (13). Detailed 3DSTE analysis was performed later offline. The present retrospective cohort study is part of the Motion Analysis of the heart and Great vessels bY three-dimensionAl speckle-tRacking echocardiography in Pathological cases (MAGYAR-Path) Study, which has been organized at the University of Szeged partly assessing disease-specific abnormalities of 3DSTE-derived features of cardiac mechanics including mLV rotations and twist in dTGA ('Magyar' means 'Hungarian' in Hungarian language). The study was conducted in accordance with the Declaration of Helsinki (as revised in 2013). The study was approved by the Institutional and Regional Human Biomedical Research Committee of University of Szeged, Hungary (No.: 71/2011) and informed consent was taken from all individual participants.

2D Doppler echocardiography

All corrected dTGA patients and healthy control

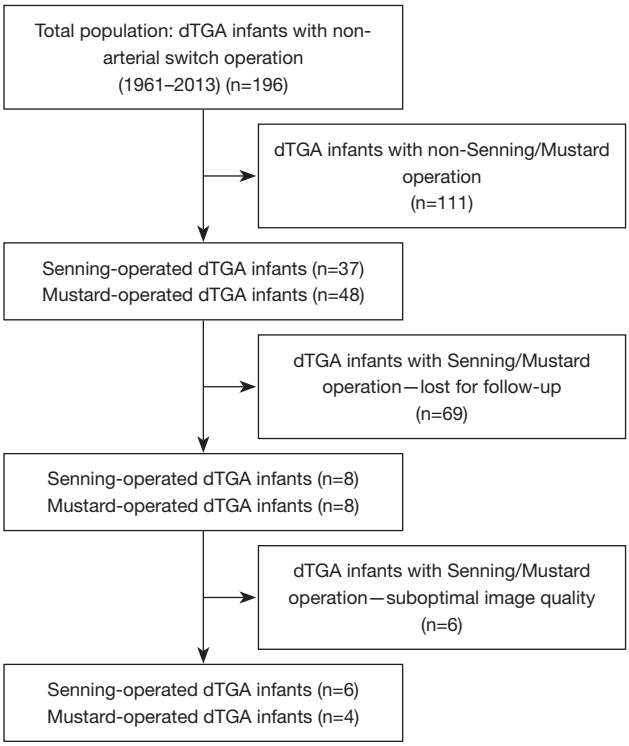

Figure 1 Inclusion and exclusion criteria for patients with corrected transposition of the great arteries are presented.

subjects have undergone a complete routine 2D Doppler echocardiographic examination with the use of Toshiba Artida™ system (Toshiba Medical Systems, Tokyo, Japan) attached to a PST-30SBP (1-5 MHz) phased-array transducer. Chamber quantifications and valvular assessments were performed in accordance with recent guidelines (13).

3DSTE

For completion of a 3DSTE study, the same Toshiba Artida™ cardiac ultrasound system (Toshiba Medical Systems, Tokyo, Japan) was applied with a PST-25SX matrix-array transducer with 3D capability (9-12). Firstly, when subjects were lying on left lateral position, 3D echocardiographic data acquisition was performed from the apical window. For optimal images, with patients asked to hold breath, 6 subvolumes were acquired, which were merged together automatically creating a full volume 3D echocardiographic dataset. Later, acquired data were analysed offline using the vendor-provided 3D Wall Motion Tracking software version 2.7 (Ultra Extend, Toshiba Medical Systems, Tokyo, Japan). Following selection of optimal typical apical longitudinal views and basal, midventricular and apical cross-sectional planes and definition of mitral annular-mLV edges and endocardial surface of the mLV apex, virtual 3D mLV model was created after a sequential analysis (14) (*Figure 2*).

By using 3D model of the mLV, clockwise basal mLV rotation (in degrees) and counterclockwise apical mLV rotation (in degrees), mLV twist (net difference of mLV apical and basal rotations in degrees) and time-to-peak mLV twist (in milliseconds) were calculated.

If the direction of the apical and basal rotation of the mLV is the same, mLV twist is absent, this is called mLV 'rigid body rotation' (RBR). In mLV-RBR, mLV twist could not be determined as appropriate, only the difference in mLV apical and basal rotations called as mLV apico-basal rotation (14).

Statistical analysis

Continuous variables are presented as mean ± standard deviation format, while categorical variables are expressed in number and percentage format. The selected significance level was P less than 0.05. Fischer's exact test was used for all categorical variables. To test normality of distribution for continuous variables, Shapiro-Wilks test was performed. Student's *t*-test was used in the presence of normal distribution, in case of non-normal distribution, Mann-Whitney-Wilcoxon test was used. Statistical analyses were performed with Medcalc software (Medcalc, Mariakerke, Belgium).

Results

Clinical and demographic data

Inclusion and exclusion criteria for dTGA patients are presented in *Figure 1*. No differences in regard to mean age (34.4±12.8 *vs.* 29.4±8.8 years, P=0.30) and gender (14 males, 58% *vs.* 5 males, 50%) could be detected between the groups examined. None of the dTGA patients or matched healthy controls had hypercholesterolaemia or diabetes mellitus. Hypertension was present in 3 dTGA patients (30%). Atrial and ventricular septal defects and patent ductus arteriosus were present in 3, 3, 4 dTGA patients, respectively. At the time of the first procedure, the average age was 1.5±1.1 years in the population of patients with dTGA. On average, 28.0±8.4 years elapsed between the intervention and the 3DSTE in this group of subjects.

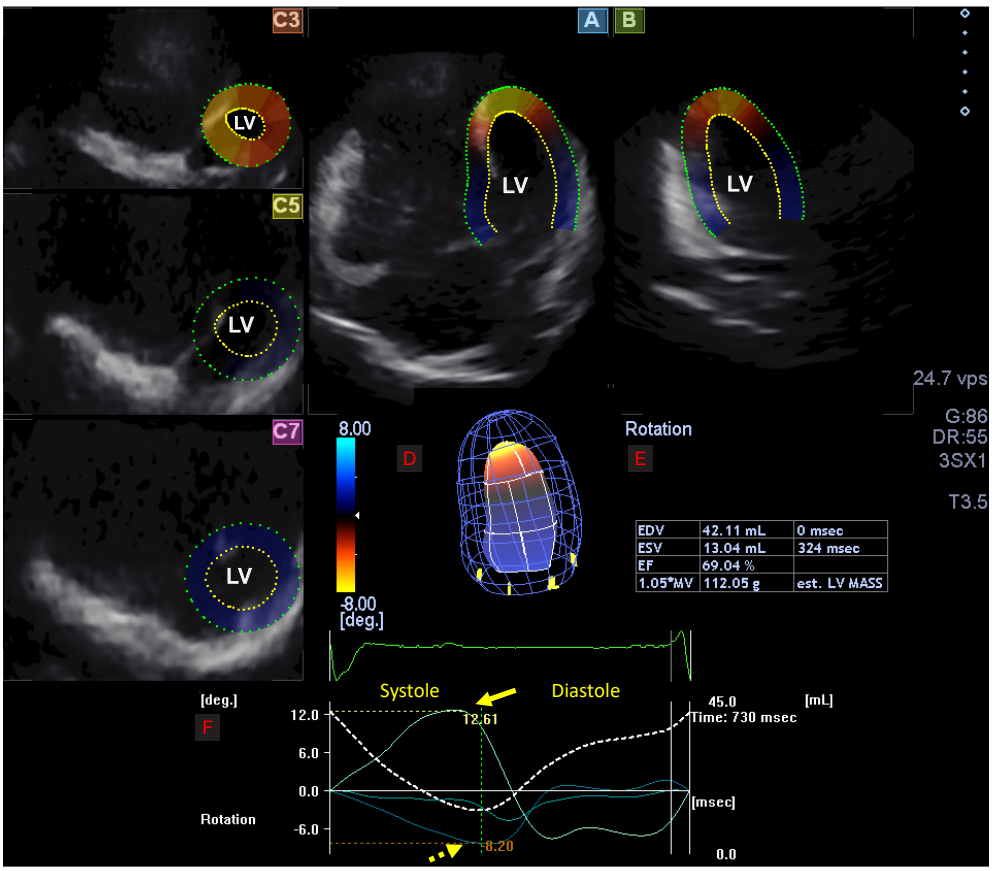

Figure 2 Three-dimensional (3D) speckle-tracking assessment of left ventricular (LV) apical and basal rotations from an LV focused view in a patient with corrected transposition of the great arteries. Apical four-chamber (A) and two-chamber views (B) and basal (C3), midventricular (C5) and apical (C7) short-axis views are demonstrated, that can be automatically extracted from the acquired 3D echocardiographic database. (Red D) shows 3D model of the LV, while (red E) shows LV volumetric parameters and ejection fraction. (Red F) shows apical and basal LV rotations. Yellow arrow represents counterclockwise LV apical rotation, while dashed yellow arrow represents clockwise basal LV rotation.

Two-dimensional Doppler echocardiography

From basic routine echocardiographic parameters, only interventricular septum and mLV posterior wall proved to be thicker in dTGA patients as compared to those of matched controls. The other parameters were similar between the groups (*Table 1*). Mitral and tricuspid regurgitations in dTGA patients are also presented in *Table 1*. None of the matched healthy controls showed larger than grade 1 valvular regurgitation or valvular stenosis on any valves.

3DSTE-derived mLV volumes

3DSTE-derived mLV end-systolic and end-diastolic volumes and mLV ejection fractions are presented in all dTGA patients and controls and in Senning-operated and Mustard-operated dTGA subgroups in *Table 2*, as well. 3DSTE-derived mLV end-diastolic volume was significantly reduced compared to that of matched controls regardless which atrial switch procedure was performed. In Senning-operated dTGA patients, mLV end-systolic volume was also decreased. No difference was seen in mLV-EF between the groups examined.

3DSTE-derived mLV rotational parameters

All matched healthy controls showed normally directed mLV rotational mechanics (clockwise basal and

Table 1 Routine two-dimensional Doppler echocardiographic data in the groups examined

xxxx	Controls (n=24)	dTGA patients (n=10)	dTGA patients following Senning-procedure (n=6)	dTGA patients following Mustard-procedure (n=4)
LA (mm)	37.3±4.0	36.6±6.0	39.3±6.5	32.5±2.1
LV-EDD (mm)	48.2±3.8	48.7±2.3	48.8±2.9	48.5±0.7
LV-EDV (mL)	113.6±27.4	112.2±13.0	112.5±16.5	111.5±5.0
LV-ESD (mm)	33.0±4.1	30.7±4.3	29.5±5.0	33.0±1.4
LV-ESV (mm)	38.7±10.3	38.8±10.9	35.8±12.2	45.0±5.7
IVS (mm)	8.7±1.3	10.7±1.4*	10.3±1.0**	11.5±2.1***
LV-PW (mm)	8.9±1.2	10.2±1.5****	10.0±1.4	10.5±2.1
LV-EF (%)	66.0±5.1	64.3±5.9	66.8±4.7	59.5±6.4
Mild MR (%)	0 (0)	2 (20.0)	1 (16.7)	1 (25.0)
Mild TR (%)	0 (0)	2 (20.0)	1 (16.7)	1 (25.0)
Moderate TR (%)	0 (0)	4 (40.0)†	2 (33.3)†††	2 (50.0)††††
Severe TR (%)	0 (0)	3 (30.0)††	1 (16.7)	2 (50.0)††††

*, P=0.004 *vs.* Controls (CI: 0.71 to 3.43); **, P=0.04 *vs.* Controls (CI: 0.09 to 2.95); ***, P=0.03 *vs.* Controls (CI: 0.69 to 4.84); ****, P=0.04 *vs.* Controls (CI: 0.01 to 2.58); †, P=0.005 *vs.* Controls; ††, P=0.02 *vs.* Controls; †††, P=0.03 *vs.* Controls; ††††, P=0.01 *vs.* Controls. dTGA, dextro-transposition of the great arteries; EDD, end-diastolic diameter; EDV, end-diastolic volume; ESD, end-systolic diameter; ESV, end-systolic volume; EF, ejection fraction; IVS, interventricular septum; mLV, morphologic left ventricular MR, mitral regurgitation; PW, posterior wall; TR, tricuspid regurgitation.

Table 2 Left ventricular volumes as assessed by three-dimensional speckle-tracking echocardiography in the groups examined

mLV volumetric parameters	Controls (n=24)	dTGA patients(n=10)	dTGA patients following Senning-procedure (n=6)	dTGA patients following Mustard-procedure (n=4)
EDV (mL)	83.8±14.8	62.5±21.1*	66.3±25.7**	56.8±13.0***
ESV (mL)	35.6±7.7	29.8±15.9	26.0±12.8****	35.5±20.3
EF (%)	57.6±4.5	57.8±11.0	59.6±12.8	55.1±8.5

*, P=0.002 *vs.* Controls (CI: 8.42 to 34.21); **, P=0.03 *vs.* Controls (CI: −33.67 to −1.41); ***, P=0.002 *vs.* Controls (CI: −43.19 to −10.75); ****, P=0.02 *vs.* Controls (CI: −17.83 to −1.31). dTGA, dextro-transposition of the great arteries; EDV, end- diastolic volume; ESV, end-systolic volume; EF, ejection fraction; mLV, morphologic left ventricular.

counterclockwise apical mLV rotations). From the dTGA patient population, only 5 out of 10 subjects had normal pattern, 5 dTGA cases had significant mLV rotational abnormality with counterclockwise mLV basal rotation in 4 patients (counterclockwise mLV-RBR with 1.9±1.0 degree apico-basal gradient). One patient had complete reversal of apical and basal mLV rotations (apical rotation was −10.7 degrees, basal rotation was 10.6 degrees, reversed mLV twist proved to be 21.3 degrees). Out of the Senning-operated patient population, 3 patients had normal pattern, 2 cases showed counterclockwise mLV -RBR (apico-basal gradient 1.1±0.5 degree). The patient with reversed mLV twist proved to be also Senning-operated. In the Mustard-operated subgroup, only 1 subject showed normal pattern, 3 patients had counterclockwise mLV-RBR mechanism (apico-basal gradient 2.5±0.8 degrees). Occurrence of mLV-RBR between the Senning- and Mustard-operated subgroups was not significantly different (P=0.5). Compared to the matched healthy controls, dTGA patients showed mLV-RBR significantly more frequently (P=0.004) regardless of which operation was performed (Senning-procedure: P=0.03; Mustard-procedure: P=0.001). dTGA patients with normal pattern of mLV rotational mechanics proved to have increased mLV basal rotation as compared to

Table 3 Features of left ventricular rotational mechanics as assessed by three-dimensional speckle-tracking echocardiography in the groups examined

Features	Controls (n=24)	dTGA patients (n=10)	dTGA patients following Senning-procedure (n=6)	dTGA patients following Mustard-procedure (n=4)
mLV rotational patterns				
Normal pattern of mLV rotational mechanics (%)	24 (100.0)	4 (40.0)	3 (50.0)	1 (25.0)
Presence of mLV-RBR (%)	0 (0)	5 (50.0)*	2 (33.3)**	3 (75.0)***
Presence of mLV rotation reversal (%)	0 (0)	1 (10.0)	1 (16.7)	0 (0)
mLV rotational parameters in subject with normal pattern of mLV rotational mechanics				
Basal rotation (degrees)	−3.7±1.9	−7.9±4.1****	−6.3±3.1	−12.6
Apical rotation (degrees)	10.3±3.5	8.5±4.9	10.8±4.6	3.6
Twist (degrees)	14.0±4.1	16.4±3.3	16.4±4.1	16.3
Time to peak twist (msec)	355±89	353±71	361±84	328

*, P=0.0009 *vs.* Controls; **, P=0.03 *vs.* Controls; ***, P=0.001 *vs.* Controls; ****, P=0.001 *vs.* Controls (CI: −6.72 to −1.64). dTGA, dextro-transposition of the great arteries; mLV, morphologic left ventricle; mLV-RBR, morphologic left ventricular 'rigid body rotation'.

matched controls. mLV rotational parameters are presented in *Table 3*.

Intra- and interobserver variability analysis

Intraobserver ICCs were 0.82, 0.83 and 0.86 for basal and apical mLV rotations and mLV twist, respectively. Interobserver ICCs proved to be 0.83, 0.83, and 0.81 for the same parameters, respectively.

Discussion

dTGA is one of the most common cyanotic CHD characterised by an abnormal connection of the ventricles and great arteries, possibly due to an abnormal rotation of the outflow tract during cardiac development (1,2,15).

Due to recent developments and improvements in non-invasive cardiovascular imaging including 3D echocardiography, more detailed functional assessment of cardiac chambers became clinical reality including evaluation of mLV rotational mechanics (9-13). In the past, invasive procedures were available for its assessment like sonomicrometry (5,6), but due to the development of 3DSTE, a new non-invasive methodology became the part of everyday practice with a short-leaning-curve and an easy-to-learn nature (9-12). In contrast with mLV strains representing mLV deformation with a significant prognostic role, although mLV rotational mechanics serve a significant part in mLV function, its prognostic significance is not clearly confirmed (14,16). The number of studies investigating mLV rotational mechanics in dTGA even in corrected cases is limited (7,8).

Currently, ASO is the treatment of choice for infants with dTGA (4). Little is known, however, about the mLV rotational abnormalities following repair. According to recent findings, infants early after the primary ASO repair (1-3,5 months) had significantly lower mLV peak apical rotation, twist and peak untwisting velocity with preserved peak basal rotation compared to controls. No significant difference in mLV twisting and untwisting was noted early and late after (6–60 months) the operation (7). Although standard measurements of global mLV were normal in 12.4±2.3-year-old children, who were ASO-operated as infants with TGA, mLV torsion was found to be similarly decreased. Greater dispersion of LV rotation was found in TGA patients with mLV basal rotation being the largest in the inferior wall and mLV apical rotation being the greatest in the anterior wall. Slightly decreased longitudinal shortening in the 2 ventricles could also be detected (8). Although Senning- and Mustard-atrial switch procedures are not up-do-date procedures, patients treated with such operations appear in the clinics (4). Therefore, results evaluating their cardiovascular status would have a value in the clinical practice. However, mLV rotational mechanics

in dTGA patients late after atrial switch has not been investigated until now.

3DSTE-derived mLV-EF and mLV volumes proved to be smaller than those determined by 2D echocardiography, which fact is in accordance with previous findings. It is known that 3DSTE underestimates LV volumes with more effect on end-diastolic LV volume resulting in lower mLV-EF due to lower 3DSTE-associated spatial resolution as compared to magnetic resonance imaging (7,8). On the other side, regressed/rudimentary mLVs were overestimated by 2D echocardiography due to methodological limitations (6,9).

The main finding of the present study is that approximately half of dTGA patients showed significant mLV rotational abnormalities including mLV-RBR and reversed mLV rotations (twist). Although a small number of dTGA patients were examined, differences in distribution of different mLV rotational patterns including above presented abnormalities could be detected late after Senning- and Mustard-procedures. mLV-RBR has been demonstrated to be associated with a number of diseases without obvious prognostic impact (17). In dTGA patients with normally directed mLV rotational mechanics, mLV basal rotation was found to be increased suggesting a compensatory mechanism resulting in a preserved mLV twist as compared to matched controls. These findings allow deeper insights into the pathophysiology of dTGA and could be theorized to be due to dTGA-associated congenital abnormalities in mLV mechanics. Further studies are warranted to confirm results with higher number of patients involved.

Limitation section

The following important limitations were found during the assessments:

- 2D Doppler echocardiography-derived image quality is known to be better compared to 3DSTE-derived ones, which could be considered as one of the most important limitation (9-12). Some patients had to be excluded due to inferior image quality as mentioned above.
- Only limited number of dTGA patients were involved in the present study due to its rare nature and as the atrial switch methodology is a rarely used procedure.
- Although 3DSTE is a suitable method for mLV strain assessments, the present study did not aim to provide a detailed investigation of LV deformation (9-12).
- The present study did not aim to validate 3DSTE-derived rotational parameters. However, inter- and intravariability data are given.

Conclusions

Significant mLV rotational abnormalities are present in dTGA late after atrial switch procedures including mLV-RBR and reversed mLV twist. In dTGA patients with normally directed mLV rotational mechanics, mLV basal rotation is increased with preserved mLV twist. There are some differences in mLV rotational abnormalities between Senning- and Mustard-procedures.

Acknowledgments

Funding: None.

Footnote

Provenance and Peer Review: This article was commissioned by the Guest Editors (Yskert von Kodolitsch, Harald Kaemmerer and Koichiro Niwa) for the series "Current Management Aspects in Adult Congenital Heart Disease (ACHD): Part V" published in *Cardiovascular Diagnosis and Therapy*. The article has undergone external peer review.

Reporting Checklist: The authors have completed the STROBE reporting checklist. Available at https://cdt.amegroups.com/article/view/10.21037/cdt-22-207/rc

Data Sharing Statement: Available at https://cdt.amegroups.com/article/view/10.21037/cdt-22-207/dss

Peer Review File: Available at https://cdt.amegroups.com/article/view/10.21037/cdt-22-207/prf

Conflicts of Interest: All authors have completed the ICMJE uniform disclosure form (available at https://cdt.amegroups.com/article/view/10.21037/cdt-22-207/coif). The series "Current Management Aspects in Adult Congenital Heart Disease (ACHD): Part V" was commissioned by the editorial office without any funding or sponsorship. The authors have no other conflicts of interest to declare.

Ethical Statement: The authors are accountable for all aspects of the work in ensuring that questions related to the accuracy or integrity of any part of the work are appropriately investigated and resolved. The study

was conducted in accordance with the Declaration of Helsinki (as revised in 2013). The study was approved by the Institutional and Regional Human Biomedical Research Committee of University of Szeged, Hungary (No.: 71/2011) and informed consent was taken from all individual participants.

References

1. Liebman J, Cullum L, Belloc NB. Natural history of transpositon of the great arteries. Anatomy and birth and death characteristics. Circulation 1969;40:237-62.
2. Warnes CA. Transposition of the great arteries. Circulation 2006;114:2699-709.
3. Konstantinov IE, Alexi-Meskishvili VV, Williams WG, et al. Atrial switch operation: past, present, and future. Ann Thorac Surg 2004;77:2250-8.
4. Haeffele C, Lui GK. Dextro-Transposition of the Great Arteries: Long-term Sequelae of Atrial and Arterial Switch. Cardiol Clin 2015;33:543-58, viii.
5. Nakatani S. Left ventricular rotation and twist: why should we learn? J Cardiovasc Ultrasound 2011;19:1-6.
6. Nemes A, Kalapos A, Domsik P, et al. Left ventricular rotation and twist of the heart. Clarification of some concepts. Orv Hetil 2012;153:1547-51.
7. Xie M, Zhang W, Cheng TO, et al. Left ventricular torsion abnormalities in patients after the arterial switch operation for transposition of the great arteries with intact ventricular septum. Int J Cardiol 2013;168:4631-7.
8. Pettersen E, Fredriksen PM, Urheim S, et al. Ventricular function in patients with transposition of the great arteries operated with arterial switch. Am J Cardiol 2009;104:583-9.
9. Nemes A, Kalapos A, Domsik P, et al. Three-dimensional speckle-tracking echocardiography - a further step in non-invasive three-dimensional cardiac imaging. Orv Hetil 2012;153:1570-7.
10. Ammar KA, Paterick TE, Khandheria BK, et al. Myocardial mechanics: understanding and applying three-dimensional speckle tracking echocardiography in clinical practice. Echocardiography 2012;29:861-72.
11. Urbano-Moral JA, Patel AR, Maron MS, et al. Three-dimensional speckle-tracking echocardiography: methodological aspects and clinical potential. Echocardiography 2012;29:997-1010.
12. Muraru D, Niero A, Rodriguez-Zanella H, et al. Three-dimensional speckle-tracking echocardiography: benefits and limitations of integrating myocardial mechanics with three-dimensional imaging. Cardiovasc Diagn Ther 2018;8:101-17.
13. Lang RM, Badano LP, Mor-Avi V, et al. Recommendations for cardiac chamber quantification by echocardiography in adults: an update from the American Society of Echocardiography and the European Association of Cardiovascular Imaging. Eur Heart J Cardiovasc Imaging 2015;16:233-70.
14. Kormányos Á, Kalapos A, Domsik P, et al. Normal values of left ventricular rotational parameters in healthy adults-Insights from the three-dimensional speckle tracking echocardiographic MAGYAR-Healthy Study. Echocardiography 2019;36:714-21.
15. Houyel L, Bajolle F, Capderou A, et al. The pattern of the coronary arterial orifices in hearts with congenital malformations of the outflow tracts: a marker of rotation of the outflow tract during cardiac development? J Anat 2013;222:349-57.
16. Sun M, Kang Y, Cheng L, et al. Global longitudinal strain is an independent predictor of cardiovascular events in patients with maintenance hemodialysis: a prospective study using three-dimensional speckle tracking echocardiography. Int J Cardiovasc Imaging 2016;32:757-66.
17. Nemes A, Kormányos Á. Prevalence of left ventricular 'rigid body rotation', the near absence of left ventricular twist (insights from the MAGYAR studies). Rev Cardiovasc Med 2022;23:5.

Cite this article as: Nemes A, Kormányos Á, Ruzsa Z, Ambrus N, Havasi K. Left ventricular rotational abnormalities in patients with transposition of the great arteries late after atrial switch operation: detailed analysis from the CSONGRAD Registry and MAGYAR-Path Study. Cardiovasc Diagn Ther 2022. doi: 10.21037/cdt-22-207