

# Transforming Hypertension Treatment

## SYMPPLICITY SPYRAL

### SAFE AND SUSTAINED BLOOD PRESSURE REDUCTION<sup>1,2</sup>




Medtronic Renal Denervation with the Symplicity Spyral™ system optimizes performance with a low-profile, easy-to-use design that delivers controlled, targeted RF energy resulting in clinically meaningful blood pressure reduction.

Explore the evidence at [Medtronic.com/RenalDenervation](https://www.Medtronic.com/RenalDenervation)

<sup>1</sup> Kandzari DE, Böhm M, Mahfoud F, et al. Effect of renal denervation on blood pressure in the presence of antihypertensive drugs: 6-month efficacy and safety results from the SPYRAL HTN-ON MED proof-of-concept randomised trial. *The Lancet*. 2018 Jun 9;391(10137):2346-2355.

<sup>2</sup> Mahfoud F, Mancia G, Schmieder R, et al. Renal Denervation in high-risk patients with hypertension. *Journal of the American College of Cardiology*. 2020; 75(23): 2879-2888.

# Finding the optimal access for proximal upper limb artery (PULA) interventions: Lessons learned from the PULA multicenter registry

Sándor Nardai MD, PhD<sup>1</sup>  | Biljana Zafirovska MD<sup>3</sup> | Ákos Pataki MD<sup>1</sup> |  
Balázs Nemes MD, PhD<sup>1</sup> | Júlia Tóth MD<sup>2</sup> | Mónika Deák MD<sup>2</sup> |  
Sasko Kedev MD, PhD<sup>3</sup>  | Olivier Francois Bertrand MD, PHD<sup>4</sup> |  
Charles Pirllet MD<sup>4</sup> | Béla Merkely MD, PhD<sup>1</sup> | Zoltán Ruzsa MD, PhD<sup>2,5</sup> 

<sup>1</sup>Heart and Vascular Center, Semmelweis University, Budapest, Hungary

<sup>2</sup>Bács-Kiskun County Hospital, Invasive Cardiology Department, Teaching Hospital of the Szent-Györgyi Albert Medical University, Kecskemét, Hungary

<sup>3</sup>University Clinic of Cardiology, Ss. Cyril and Methodius University, Skopje, Macedonia

<sup>4</sup>Cardiology Department, University Laval, Quebec, Canada

<sup>5</sup>Department of Internal Medicine, Invasive Cardiology Division, University of Szeged, Szeged, Hungary

## Correspondence

Zoltán Ruzsa, University of Szeged, Second Department of Internal Medicine and Cardiology Center, 6725 Szeged, Semmelweis Str. 6, Hungary.

Email: zruzsa25@gmail.com

## Abstract

**Objective:** The multicenter proximal upper limb artery (PULA) Registry was created to study the optimal puncture sites for the interventions involving the subclavian, axillary, and innominate arteries.

**Background:** Little is known about the optimal vascular access for PULA interventions, despite the well-known technical complexity of these procedures.

**Methods:** We performed the retrospective analysis of consecutive patients treated for symptomatic steno-occlusive disease of the proximal upper limb arteries between January 2015 and December 2019 in three high-volume centers. Acute thrombotic occlusions were excluded from the study.

**Results:** Two hundred and seventy-two patients were treated for significant stenosis and 108 for total occlusion. The baseline patient's characteristics were similar, except for the higher median age of the stenotic patients: 68.5 years (31.1; 90.0) versus 64 years (38.0; 86.0)  $p = 0.0015$ . Successful revascularization rate was higher in the stenotic group 93.75% (255/272) versus 86.11% (93/108)  $p = 0.0230$ , while the procedure length 27 min (8; 133) versus 46 min (7; 140)  $p = 0.0001$  and fluoroscopy times 439 s (92; 2993) versus 864 s (86; 4176)  $p = 0.0001$  were higher in the occlusion group. The main adverse event rate was similarly low. Dual access was used more often to treat occlusions (60.19% (65/108) vs. 11.40% (31/272)  $p = 0.0001$ ) without significantly increasing the complication rate. The safest access was ultrasound-guided distal radial artery puncture, significantly better than conventional radial access with 0% (0/31) versus 13.6% (18/131)  $p = 0.0253$  complication.

**Conclusions:** The percutaneous revascularization of proximal upper limb arteries is a safe and effective. Dual access can be applied to increase treatment efficacy, without significantly compromising safety.

This is an open access article under the terms of the Creative Commons Attribution-NonCommercial License, which permits use, distribution and reproduction in any medium, provided the original work is properly cited and is not used for commercial purposes.

© 2021 The Authors. *Catheterization and Cardiovascular Interventions* published by Wiley Periodicals LLC.

## KEYWORDS

carotid and super-aortic disease, radial approach, subclavian PTA

## 1 | INTRODUCTION

Peripheral arterial disease (PAD) involving the upper extremities affects approximately 2% of the general population, while in the case of concomitant lower extremity PAD the prevalence increases to 9%. The clinical picture associated with this upper limb PAD is quite diverse: while the majority remains asymptomatic, in many cases severe symptoms, such as embolization to the fingers, subclavian steal syndrome, or even ischemic events in the vertebrobasilar territory may occur. Five percent of all affected patients develop critical limb ischemia, and 25% will require revascularization due to symptoms significantly altering their quality of life.<sup>1</sup> Subclavian artery stenosis can even lead to myocardial ischemia in patients who benefited from aorto-coronary bypass grafting (ACBG).<sup>2</sup>

While asymptomatic patients can generally be managed by optimal medical therapy, symptomatic cases often require invasive treatment.<sup>3</sup> The revascularization of subclavian and innominate arteries can be performed both surgically and percutaneously, and no randomized controlled trials comparing the two approaches were performed until today. According to observational data, the risk of severe complications like vertebrobasilar stroke is low using both treatment modalities, and the 1-year overall survival of all treated patients is over 95%.<sup>4</sup> Due to the need for more extensive resource utilization during the complex surgical reconstructions,<sup>5</sup> the endovascular approach became the initial default strategy in most centers, and open surgery is mainly reserved for patients with extensive disease and for treating re-occlusions after stenting.<sup>3</sup>

Despite the lack of randomized data, a large meta-analysis including 544 patients have concluded, that stent implantation was superior to balloon angioplasty alone in providing vessel patency and event-free survival,<sup>6</sup> and the use of balloon-expandable stents are

preferred over self-expandable devices, especially in the case of lesion calcification.<sup>7</sup>

Providing safe access for percutaneous subclavian and innominate artery interventions can be exceedingly challenging, due to the frequent concomitant involvement of femoral arteries by PAD,<sup>1</sup> and the difficulty of puncturing the radial arteries distal to the treated lesion. Another important technical obstacle highly related to the vascular access is the cannulation of the true lumen during the recanalization of total occlusions. Although the initial choice of the puncture site and the decision to upgrade to dual access may have substantial influence on the outcome of endovascular procedures in the proximal upper extremity, no previous studies have addressed this issue before. Our analysis of the large-scale, multicenter PULA Registry is the first published data aimed to provide information on the optimal selection of access site for interventions in these arterial segments.

## 2 | METHODS

### 2.1 | Patient subgroups

We retrospectively analyzed the prospectively assembled registry data of consecutively treated symptomatic patients with higher than 50% stenosis or occlusion of the axillary, subclavian, and innominate arteries (Table 1). All patients were treated percutaneously during 5 years' time-period in three high-volume interventional centers. In the majority of cases, stent implantation was equally performed following the balloon angioplasty. We compared the demographic and procedural data of the stenotic cases with the group treated for total occlusions of the proximal upper limb arteries. Patients admitted for acute thrombotic occlusions were excluded from our study.

**TABLE 1** Baseline clinical data of all proximal upper limb artery (PULA) PTA patients

	PULA stenosis <i>n</i> = 272/380; 71.58%	PULA occlusion <i>n</i> = 108/380; 28.42%	<i>p</i>
Median age (min; max) in years	68.5 (31.0; 90.0)	64.0 (38.0; 86.0)	0.0015
Male gender	36.03% (98/272)	39.81% (43/108)	0.5563
Hypertension	91.54% (249/272)	85.19% (92/108)	0.0090
Hyperlipidemia	73.53% (200/272)	72.22% (78/108)	0.7985
Diabetes	22.06% (60/272)	22.22% (24/108)	1.0000
Smoking	38.97% (106/272)	47.22% (51/108)	0.1657
Chronic kidney disease	9.56% (26/272)	10.19% (11/108)	0.8492
Coronary heart disease	41.54% (113/272)	36.11% (39/108)	0.3545
Occlusion site			
Right subclavian	23.53% (64/272)	14.81% (16/108)	0.0697
<b>Left subclavian</b>	<b>65.07% (177/272)</b>	<b>76.85% (83/108)</b>	<b>0.0278</b>
Anonymous artery	12.50% (34/272)	8.33% (9/108)	0.2852

Note: Bold values are considered significant.

Institutional Review Committee approved the registry at all sites, and all patients provided written informed consent prior to inclusion in the database.

## 2.2 | Percutaneous transluminal angioplasty of the proximal upper limb arteries

The choice of access site was left to the operator's discretion. In case of palpable pulse, the radial artery was cannulated with dedicated trans-radial needle and 5–6 Fr sheath (Terumo Co, Tokyo, Japan). Only distal radial artery punctures were performed routinely under ultrasound guidance (Vivid I, General Electric, USA). Femoral and brachial access was provided using the standard Seldinger's technique with 6 or 7 Fr sheath (Terumo, Tokyo, Japan). During the recanalization of total occlusions, dual access was frequently used as a primary or bail-out treatment strategy allowing bilateral lesion preparation and guiding the reentry to the true lumen of the vessel distal to the occlusion. In the primary dual-access cases, the recanalization was always initiated from the upper extremity access in retrograde direction, and antegrade technic was used from the femoral artery in case of failure of the initial retrograde attempt. In selected stenotic cases, dual access was also applied as a complementary diagnostic technique to help determine the lesion length by improving visualization of the diseased segments.

During transfemoral interventions, 6 or 7 Fr vertebral shaped guiding catheters (Cordis, Santa Clara, CA) were advanced to the origin of the involved artery. Transradial interventions were performed using 6 Fr long (45–70 cm) hydrophilic sheaths (Terumo, Tokyo, Japan), while in case of a distal radial puncture, dedicated 11 cm-long, 6 Fr. slender radial sheaths were used (Terumo, Tokyo, Japan) (Figure 1).

The stenotic lesion was passed initially with a 35'' hydrophilic wire (Terumo, Tokyo, Japan), and the revascularization was performed routinely with 35'' wire compatible balloons and balloon-mounted peripheral stents. In case of difficult crossing, various dedicated 14'' chronic

total occlusion (CTO) guidewires and coronary balloons were also applied during the revascularization attempt. The need for stent implantation was decided individually in each case (Figure 1).

## 2.3 | Antithrombotic regimen

All patients were on dual antiplatelet therapy for 2 months (aspirin 100 mg and clopidogrel 75 mg orally) started with a loading dose of 325 mg aspirin and 300 mg clopidogrel, days before the procedure. The intra-arterial cocktail (2.5 mg verapamil, 5000 IU heparin sodium, 250 mcg nitroglycerine) was given directly in the radial artery through the sheath. In case of the femoral approach, only Na-Heparin was given until 100 IU/kg dose.

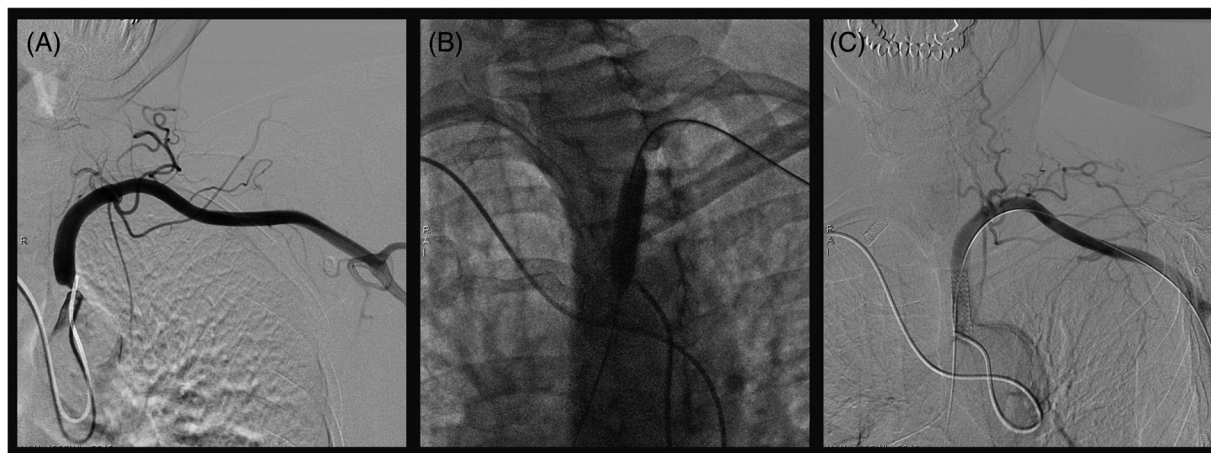
## 2.4 | Postoperative management

After the procedure, the sheath was removed immediately in all RA and BA cases, and hemostasis was achieved with a tourniquet for 6 h. Dedicated hemostatic device was applied in all RA cases (RadiStop, Terumo, Tokyo, Japan). All patients were mobilized immediately. For the FA approach, a closure device (Angioseal, St. Jude Medical, Saint Paul, MN) was used. Mechanic compression bandage was applied for 4 h over the groin, before the patients were mobilized.

## 2.5 | Definitions

### 2.5.1 | Major adverse events

Major adverse events (MAE) were assessed as the composite of death, and repeated revascularization of the target vessel by PTA or surgical operation during the hospital stay and at 6-month follow-up.



**FIGURE 1** Slender transradial angioplasty of the critical left subclavian artery stenosis. After the identification of a critical stenosis at the origin of the left subclavian artery using a 5 Fr Simons 2 catheter advanced from right distal radial access (A), the lesion was treated using a balloon-expandable stent advanced retrogradely through a 6 Fr slender sheath inserted in the left distal radial artery (B). The adequate stent placement was guided by bilateral imaging to avoid unnecessary protrusion into the aorta (C)

## 2.5.2 | Vascular complications

*Definition of vascular complications:* Major vascular complication was defined as diminished or lost arterial pulse or the presence of any pseudoaneurysm or arteriovenous fistula during the clinical follow-up. Major bleeding was defined as a drop in the hemoglobin level of  $> 3$  gm/dl, as well as any bleeding requiring blood transfusions. Major hematomas were defined  $\geq 5$  cm in diameter. Minor vascular complications were defined as hematomas requiring no further treatment, measuring  $\leq 5$  cm in diameter over the femoral puncture site.

## 2.5.3 | Success

*Technical success* was defined as percutaneous transluminal angioplasty (PTA) resulting in less than 30% residual stenosis with sufficient antegrade flow.

## 2.6 | Quantitative angiography and measurements

The vessel diameters and the degree of stenosis were determined by a computerized quantitative analysis system (Advantage Workstation 4.6, General Electric, Chicago, IL) before and after angioplasty.

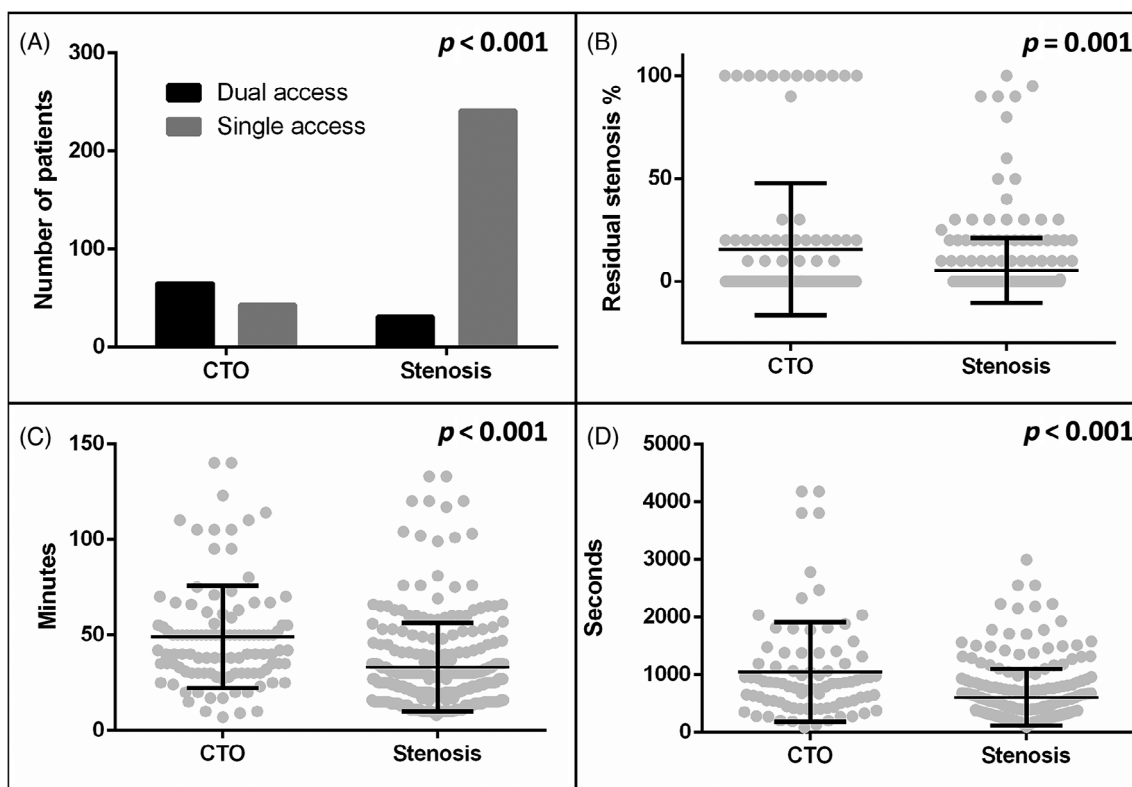
## 2.7 | Statistical analysis

Statistical analysis was performed using the commercially available Graph Pad Prism 8.0 software (USA). Continuous variables were expressed as the median with minimum–maximum range. Categorical variables were tabulated as percentages. The different patient cohorts were compared using either the Mann–Whitney  $U$  test or  $\chi^2$  test.  $p$  values lower than 0.05 were considered significant.

## 3 | RESULTS

### 3.1 | Demographic and clinical data

Three hundred eighty patients were included in our analysis, 272 in the stenotic group and 108 in the occlusion cohort. The baseline demographics of the two patient cohorts were largely similar, we noted a female predominance 63.97% versus 60.19% in both groups, 91.54% versus 85.19% had hypertension, 22.06% versus 22.22% had diabetes while 41.54% versus 36.11% underwent previous coronary revascularization. The median age of the patients treated for stenosis was significantly higher compared to the occlusion cohort: 68.5 (min: 31.0, max: 90.0) years versus 64.0 (min: 38.0, max: 86.0) years  $p = 0.0015$ . The most often affected vessel in our series was the left subclavian artery, which was involved in 65.07% (177/272) of the stenotic and 76.85% (83/108) of the occlusion cases (Table 1).

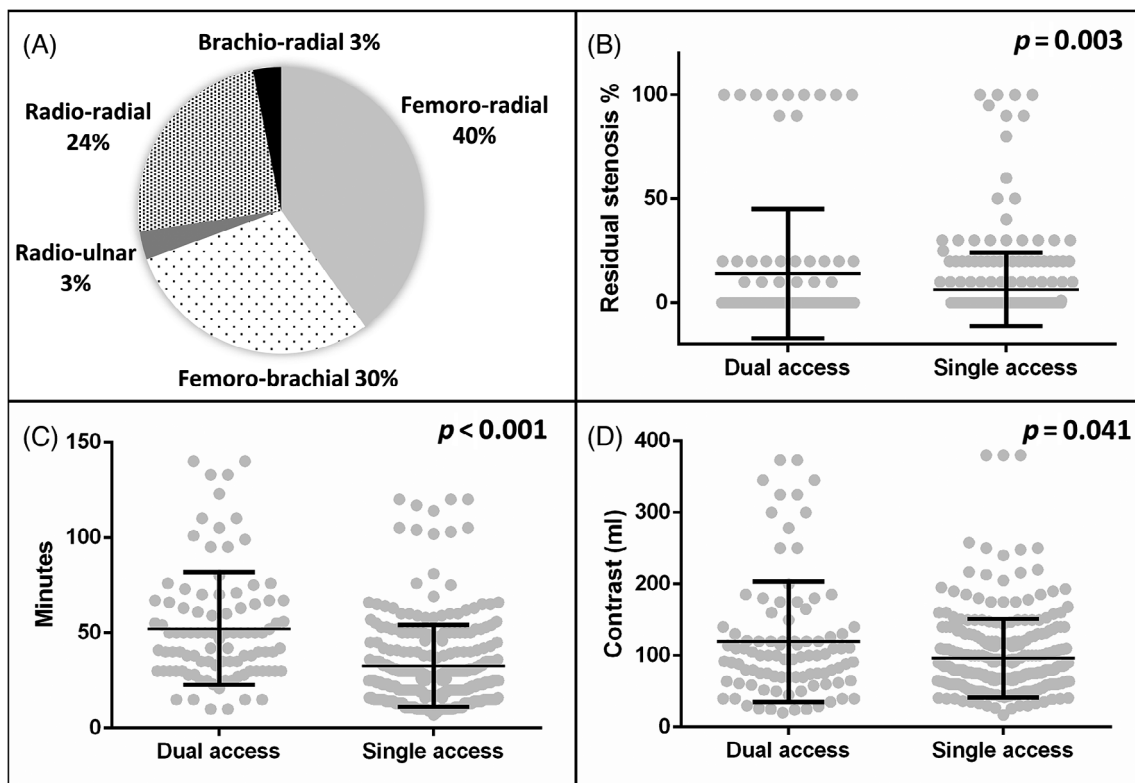


**FIGURE 2** Procedural data of CTO interventions: Despite the more frequent use of dual access while treating CTO lesions (A), the residual stenosis post-intervention was higher in this patient group (B). The greater complexity of the CTO procedures is reflected in the significantly increased procedural length (C) and fluoroscopy times (D). Bars represent mean and standard deviation

**TABLE 2** Procedural data of all proximal upper limb artery (PULA) PTA cases

	PULA stenosis <i>n</i> = 272/380; 71.58%	PULA occlusion <i>n</i> = 108/380; 28.42%	<i>p</i>
Access site			
Single radial artery	<b>22.79% (62/272)</b>	<b>12.04% (13/108)</b>	<b>0.0216</b>
Single ulnar artery	1.47% (4/272)	0% (0/108)	0.5811
Single brachial artery	6.99% (19/272)	7.41% (8/108)	0.8289
Single femoral artery	<b>57.35% (156/272)</b>	<b>20.37% (22/108)</b>	<b>0.0001</b>
Use of dual access	<b>11.40% (31/272)</b>	<b>60.19% (65/108)</b>	<b>0.0001</b>
Residual stenosis post intervention	<b>5.30% (0.00; 100.00)</b>	<b>15.65% (0.00; 100)</b>	<b>0.0009</b>
Successful revascularization (residual stenosis <30%)	<b>93.75% (255/272)</b>	<b>86.11% (93/108)</b>	<b>0.0230</b>
Stent implantation	74.26% (202/272)	79.63% (86/108)	0.2910
Procedure time (min)	<b>27 (8; 133)</b>	<b>46 (7; 140)</b>	<b>0.0001</b>
Fluoroscopy time (s)	<b>422.5 (92; 2993)</b>	<b>848 (86; 4176)</b>	<b>0.0001</b>
Contrast use (ml)	80 (15; 380)	97 (10; 325)	0.1781
Hospitalization length (days)	2 (1; 29)	2 (1; 15)	0.8422
All vascular complications	10.29% (28/272)	13.89% (15/108)	0.3692
Hematoma	7.35% (20/272)	9.26% (10/108)	0.7778
Pseudoaneurysm	2.94% (8/272)	0.95% (1/108)	0.4550
Radial occlusion	3.31% (9/272)	7.41% (8/108)	0.0990
Major vascular complications	5.88% (16/272)	7.41% (8/108)	0.6409
Main adverse events at 6 months	6.99% (19/272)	4.63% (5/108)	0.4882

Note: Bold values are considered significant.



**FIGURE 3** Dual-access interventions in treating PULA lesions: Pie chart shows the distribution of various access site combinations in dual-access cases. (A) Dual access was used in technically challenging cases, requiring more procedure time (C), and higher contrast use (D). The final residual stenosis in the dual-access interventions remained higher. (B) Bars represent mean and standard deviation. PULA, proximal upper limb artery

### 3.2 | Procedural and outcome data

The comparative analysis of the procedural data of the stenotic and occlusive disease cohorts highlights the higher complexity of the revascularization procedures in the latter group. Despite the higher median procedure length of 27 min (min: 8, max: 133) versus 46 (min: 7, max: 140)  $p = 0.0001$  and fluoroscopy times of 422.5 s (min: 92, max: 2993) versus 848 s (min: 86, max: 4176)  $p = 0.0001$  the procedural success rate was significantly lower 86.11% (93/108) versus 93.75% (255/272)  $p = 0.0230$  in the occlusive cohort. While stent implantation was performed in a similar proportion of patients treated for occlusions: 79.63% (86/108) versus 74.26% (202/272)  $p = 0.2910$ , the post-intervention residual stenosis of the treated vessels was significantly higher in this group 15.65% (0.00; 100) versus 5.30% (0.00; 100.00)  $p = 0.0009$  (Figure 2). Dual access was used in a significantly higher proportion of the interventions targeting occlusive lesions 60.19% (65/108) versus 11.40% (31/272)  $p = 0.0001$ , but importantly no difference was detected in the rate of overall vascular complications 10.29% (15/108) versus 13.89% (28/272)  $p = 0.3692$ , in the length of hospitalization: 2 days (min: 1, max: 15) versus 2 days (min: 1, max: 29)  $p = 0.8422$  or in the 6 months MAE rate 4.63% (5/108) versus 6.99% (19/272)  $p = 0.4882$  between the two cohorts (Table 2).

### 3.3 | Safety and efficacy of dual access

The use of dual access increases procedural complexity and requires the use of additional resources compared to the use of a single-access site. Dual access indeed significantly increased procedural and fluoroscopy times both during the treatment of occlusive and the stenotic lesions, and it also increase the contrast material use: 100 ml (min: 20, max: 373) versus 80 ml (min: 17, max: 380)  $p = 0.0411$  (Figure 3). However, the rate of vascular complications was not increased using dual access, while its application allowed the achievement of high reperfusion rates, comparable to those achieved in simpler lesions treated from singular access (Table 3).

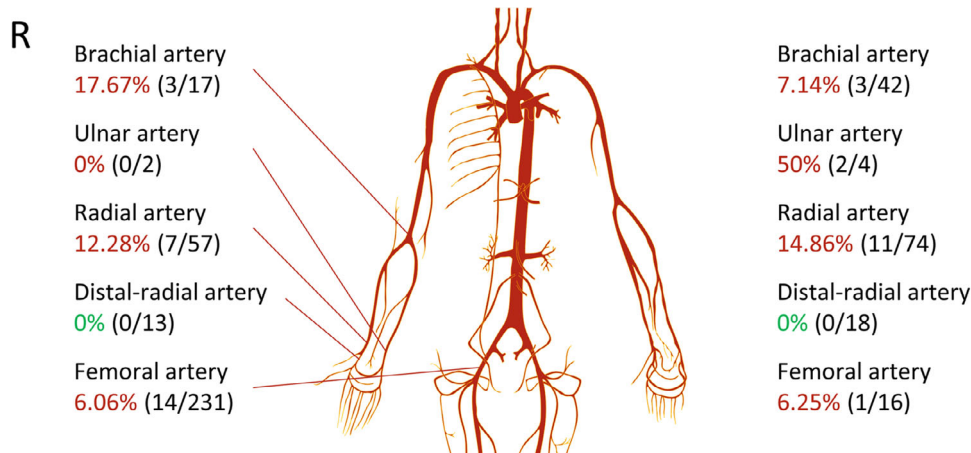
### 3.4 | Safety of various puncture sites during the treatment of PULA lesions

Providing the adequate access for endovascular interventions of the upper limb arterial lesions is exceedingly challenging due to the frequently generalized PAD involving other vascular territories and the difficulty of puncturing the upper extremity arteries distal to the occluded segment. We have documented a relatively high vascular complication rate in the PULA PAD population: in the patient who underwent radial artery puncture without the use of vascular

**TABLE 3** Procedural data of single versus dual-access interventions ( $n = 380$ )

	Dual access ( $n = 96$ )	Single access ( $n = 284$ )	$p$
Residual stenosis post intervention	<b>13.96% (0.00; 100.00)</b>	<b>6.31% (0.00; 100)</b>	<b>0.0032</b>
Successful revascularization (residual stenosis <30%)	88.54% (85/96)	92.61% (263/284)	0.2097
Procedure time (min)	<b>48.5 (10; 140)</b>	<b>27.5 (7; 120)</b>	<b>0.0001</b>
Fluoroscopy time (s)	<b>864 (168; 3805)</b>	<b>441.5 (86; 4176)</b>	<b>0.0001</b>
Contrast use (ml)	<b>100 (20; 373)</b>	<b>80 (17; 380)</b>	<b>0.0411</b>
All vascular complications	16.67% (16/96)	9.51% (27/284)	0.0633
Major vascular complications	9.38% (9/96)	5.28% (15/284)	0.1536
Main adverse event at 6 months	3.13% (3/96)	7.39% (21/284)	0.2223

Note: Bold values are considered significant.



**FIGURE 4** The overall vascular complication rate at various access sites. Distal radial artery is highlighted in green, as the puncture site with the lowest complication rate [Color figure can be viewed at [wileyonlinelibrary.com](http://wileyonlinelibrary.com)]

ultrasound (VUS) guidance we found an access-related complication rate of 14.86% (11/74) on the left and 12.28% (7/57) on the right side. Importantly the use of the distal radial approach, with the application of VUS guidance and dedicated slender sheaths resulted in a significantly lower complication rate compared to conventional radial puncture 0% (0/31) versus 13.6% (18/131)  $p = 0.0253$  (Figure 4).

## 4 | DISCUSSION

We report the outcome data of 380 consecutive cases of symptomatic proximal upper limb artery PAD treated by endovascular interventions in three high-volume centers, with 91.57% of good procedural outcome and 93.68% MAE free survival rate at 6 months follow up. Our results are statistically nondifferent from the data published in the largest available meta-analysis including 544 patients treated by endovascular therapy, regarding the safety and efficacy of the procedures.<sup>6</sup>

In our series, the revascularization of total occlusions was not associated with increased procedural risk, although the procedural length and fluoroscopy times were higher as the consequence of the greater complexity of the interventions. While the procedural success rate was significantly lower in the occlusive group compared to the stenotic cohort, it still exceeded 86%, therefore most of the patients could benefit from these interventions. Of note, we found a lower average age in the patient group treated for occlusion, which was probably the consequence of selection biases.

The cumulative rate of vascular complications was 11.32%, with 6.31% of the patients requiring further medical or surgical treatment. This rate of vascular complications is somewhat higher compared to the published data vascular interventions in other peripheral regions,<sup>8</sup> which may be explained by the frequent concomitant involvement of the lower extremity arteries used as a puncture site, and the difficulty of puncturing the upper extremity vessels distal to the occluded segment. Nevertheless, the use of dual access was proven safe in the selected complex cases, and it did not increase the rate of vascular complications significantly, compared to the single-access approach.

We have independently analyzed the vascular complication rate associated with each puncture site to identify the source of the excess vascular complications. Cannulation of the femoral artery is still regarded as the gold standard for peripheral arterial interventions, and in our series, the detected complication rate of 6.1% was statistically non-different from the previously published data.<sup>8</sup> The use of radial artery is less frequent in peripheral arterial interventions, and in our previous feasibility study on the use of radial access for iliac artery interventions, we noted a vascular complication rate of 5.1%,<sup>9</sup> which is significantly lower compared to the 13.7% detected in our current series. The RADCAR randomized study, comparing the safety and efficacy of radial and femoral approach in the treatment of significant carotid stenosis, reported an overall complication rate of 8.6% associated with radial artery puncture,<sup>10</sup> which is still lower than our current findings. We have separately analyzed the safety of distal radial access, and this access site was found to be significantly safer compared to the conventional radial

approach: we did not detect any complications in this small patient cohort. While these safety figures are comparable to the data published on the safety of distal radial access during carotid interventions,<sup>11</sup> the routine use of VUS guidance have certainly contributed to this good result.<sup>12</sup> Based on our current finding, we concluded that the use of VUS guidance is advisable for the safe puncture of all arteries distal to the PULA lesions, including ulnar and brachial access, to prevent the excess vascular complications. The potentially superior safety profile of distal radial access must be further evaluated in future randomized studies.

## 5 | SUMMARY AND CONCLUSION

We recognize that the retrospective design, the limited number of studied subjects especially in the distal radial group, and the lack of randomization between the treatment strategies (dual vs. single access) are all important limitations of our study. The large overall number of the included patients, and the high follow up rate in the PULA registry however enables us to confirm, that the percutaneous revascularization of proximal upper limb arteries is a safe and effective technic, and dual access can be also safely applied to increase treatment efficacy in selected patients.

### CONFLICT OF INTEREST

The authors have no conflict of interest to declare.

### DATA AVAILABILITY STATEMENT

The data that support the findings of this study are available on request from the corresponding author. The data are not publicly available due to privacy or ethical restrictions.

### ORCID

Sándor Nardai  <https://orcid.org/0000-0001-9282-4477>

Sasko Kedev  <https://orcid.org/0000-0003-4844-6434>

Zoltán Ruzsa  <https://orcid.org/0000-0002-2474-5723>

### REFERENCES

- Jahic E, Avdagic H, Iveljic I, Krdzalic A. Percutaneous transluminal angioplasty of subclavian artery lesions. *Med Arch*. 2019;73:28-31.
- Olsen CO, Duntton RF, Maggs PR, Lahey SJ. Review of coronary-subclavian steal following internal mammary artery-coronary artery bypass surgery. *Ann Thorac Surg*. 1988;46:675-678.
- Aboyans V, Ricco JB, Bartelink MEL, et al. Editor's choice - 2017 ESC guidelines on the diagnosis and treatment of peripheral arterial diseases, in collaboration with the European Society for Vascular Surgery (ESVS). *Eur J Vasc Endovasc Surg*. 2018;55:305-368.
- Klitfod L, Jensen LP. Treatment of chronic upper limb ischaemia is safe and results are good. *Dan Med J*. 2014;61:A4859.
- Daniel VT, Madenci AL, Nguyen LL, et al. Contemporary comparison of supra-aortic trunk surgical reconstructions for occlusive disease. *J Vasc Surg*. 2014;59:1577-1582.
- Chatterjee S, Nerella N, Chakravarty S, Shani J. Angioplasty alone versus angioplasty and stenting for subclavian artery stenosis—a systematic review and meta-analysis. *Am J Ther*. 2013;20:520-523.
- van de Weijer MA, Vonken EJ, de Vries JP, Moll FL, Vos JA, de Borst GJ. Technical and clinical success and long-term durability of

- endovascular treatment for atherosclerotic aortic arch branch origin obstruction: evaluation of 144 procedures. *Eur J Vasc Endovasc Surg.* 2015;50:13-20.
8. Balzer JO, Thalhammer A, Khan V, Zangos S, Vogl TJ, Lehnert T. Angioplasty of the pelvic and femoral arteries in PAOD: results and review of the literature. *Eur J Radiol.* 2010;75:48-56.
  9. Ruzsa Z, Tóth K, Nemes B, et al. Transradial and transulnar access for iliac artery interventions using sheathless guiding systems: a feasibility study. *Catheter Cardiovasc Interv.* 2016;88:923-931.
  10. Ruzsa Z, Nemes B, Pintér L, et al. A randomised comparison of transradial and transfemoral approach for carotid artery stenting: RADCAR (RADial access for CARotid artery stenting) study. *EuroIntervention.* 2014;10:381-391.
  11. Nardai S, Végh E, Óriás V, et al. Feasibility of distal radial access for carotid interventions: the RADCAR-DISTAL pilot study. *EuroIntervention.* 2020;15:1288-1290.
  12. Hadjivassiliou A, Kiemeneij F, Nathan S, Klass D. Ultrasound-guided access to the distal radial artery at the anatomical snuffbox for catheter-based vascular interventions: a technical guide. *EuroIntervention.* 2021;16:1342-1348.

**How to cite this article:** Nardai S, Zafirovska B, Pataki Á, Nemes B, Tóth J, Deák M, et al. Finding the optimal access for proximal upper limb artery (PULA) interventions: Lessons learned from the PULA multicenter registry. *Catheter Cardiovasc Interv.* 2021;98:1375–82. <https://doi.org/10.1002/ccd.29967>