Pancreatology 20 (2020) 1656–1660

Contents lists available at ScienceDirect

Pancreatology

journal homepage: www.elsevier.com/locate/pan

Original Article

Recurrent acute pancreatitis induced by 5-ASA and azathioprine in ulcerative colitis

Péter Jenő Hegyi [a], Zsolt Szakács [a, b], Nándor Faluhelyi [c], Balázs Csaba Németh [d], Judit Bajor [e], Péter Hegyi [a, d, *], on behalf of the Hungarian Pancreatic Study Group

[a] Institute for Translational Medicine, Medical School, University of Pécs, Pécs, Hungary
[b] Szentágothai Research Center, University of Pécs, Pécs, Hungary
[c] Department of Diagnostic Imaging, University of Pécs, Pécs, Hungary
[d] Centre for Translational Medicine, First Department of Medicine, Faculty of Medicine, University of Szeged, Szeged, Hungary
[e] Division of Gastroenterology, First Department of Medicine, Medical School, University of Pécs, Pécs, Hungary

ARTICLE INFO

Article history:
Received 30 April 2020
Received in revised form
4 October 2020
Accepted 5 October 2020
Available online 10 October 2020

Keywords:
Drug-induced acute pancreatitis
Mesalazine
Azathioprine
Inflammatory bowel disease
Re-challenge

ABSTRACT

Drug-induced acute pancreatitis (DIAP) is an often-neglected entity where the disorder is the consequence of the toxic effects of various agents applied to treat potentially life-threatening conditions, such as inflammatory bowel disease. Here, we present the case of a male patient with ulcerative colitis with a history of two episodes of recurrent acute pancreatitis. After excluding other potential causes, we suspected DIAP since the patient received 5-aminosalycilate (5-ASA) prior to the first episode and, one year later, azathioprine (AZA) prior to the second episode. The causative effect of AZA was confirmed by performing a re-challenge with a reduced dose. While both episodes of DIAP had a mild disease course, they were associated with acute relapse of ulcerative colitis. Last seen, the patient was asymptomatic. With this case, we would like to highlight the importance and diagnostic difficulties of DIAP in the background of recurrent cases when common etiological factors of acute pancreatitis are excluded.

1. Introduction

Acute pancreatitis (AP) is a leading cause of acute hospitalization for gastrointestinal disorders with an incidence varying between 10 and 100/100,000 inhabitants across countries [1]. Approximately 15–20% of patients with AP develop a severe disease course which has a mortality of 15% [2]. Biliary pathologies, alcohol consumption and hyperlipidaemia are in history in more than >70% of the cases while the rest is usually coined as idiopathic [2]. However, detailed investigations often raise concerns about the adverse effects of drugs.

In general, drug-induced AP (DIAP) is considered a rare entity, accounting for approximately 2–5% of AP episodes worldwide [3,4]. AZA and 5-ASA, both are part of the basic therapy of ulcerative colitis (UC) [5], have frequently been reported to be associated with the development of DIAP. Our recent systematic review revealed 36 case reports regarding 5-ASA-triggered AP in the relevant literature [3]. In a meta-analysis performed by the Cochrane Collaboration, three cases of AP were reported from seven randomized controlled studies including 115 patients treated with AZA [6]. Recurrent DIAP triggered by either the same or different drugs is rare [7]. In these cases, patients are at risk for multiple reasons: 1) AP has its own risk of adverse outcomes, 2) withdrawing the agent suspected in the background of DIAP may lead to a burst in disease activity of UC, and 3) introducing a new treatment has its own risks as well while the pool of treatment options reduces. With both types of basic therapy (5-ASA and AZA) one of the most feared adverse reaction is DIAP [8].

In this paper, we report a case with two episodes of DIAP triggered by 5-ASA and AZA in UC.

2. Case presentation

A 31-year old non-compliant patient with left-sided UC (diagnosed in 2018, as shown by the timeline in Fig. 1A) currently treated with AZA (1 × 150 mg/day orally), presented to the emergency unit.

Abbreviations: **AP**, acute pancreatitis; **AZA**, azathioprine; **DIAP**, drug-induced acute pancreatitis; **IBD**, inflammatory bowel disease; **5-ASA**, 5-aminosalicylic acid; **TIP**, thiopurine-induced acute pancreatitis; **UC**, ulcerative colitis.

* Corresponding author. H-7624, Pécs, Ifjúság út 12, Hungary.
E-mail addresses: hegyi.peter@pte.hu, p.hegyi@tn-centre.org (P. Hegyi).

https://doi.org/10.1016/j.pan.2020.10.026
1424-3903/

He had a previous episode of mild DIAP1 triggered by 5-ASA in 2018 (the Naranjo score was 7; for CT scan, see Fig. 1A). Currently, he complained of a 3-day history of intermittent colic epigastric abdominal pain with nausea, vomiting, and bloody diarrhoea (15–20 times a day). The patient was diagnosed with an acute flare-up of UC and suspected recurrent AP, which was confirmed by serum lipase and amylase activity more than three times greater than the upper limit of normal (402 and 776 U/L, respectively) and by characteristic findings on transabdominal ultrasonography and contrast-enhanced computed tomography (CECT).

The patient was admitted to the inpatient unit of the Division of Translational Medicine, First Department of Medicine, Medical School, University of Pécs (Pécs, Hungary). On admission, the patient had stable cardiopulmonary status with normal hemoglobin level, the Bedside Index for Severity in Acute Pancreatitis (BISAP) score was rated 2. Based on complex clinical assessment, the patient did not require intensive care [9]. We started aggressive intravenous fluid replacement (10–15 mL/body kg in the first hour, followed by 3000 ml in the first 24 h) and inserted a thin nasogastric tube (10 C h). In order to clarify the etiology of AP, alcoholic and biliary origins were excluded.

Genetic testing of pancreatitis-associated genes was performed by Sanger sequencing. We did not find any risk alleles for pancreatitis in the investigated genomic regions (all exons of *PRSS1, SPINK1, CTRC, CPA1* genes, and exons 4 and 11 in the *CFTR* gene). AZA treatment was assumed to be the cause of AP (DIAP2, Naranjo score: 10, which is considered a definitive adverse reaction) [8]. Upon conservative treatment, his status significantly improved and became asymptomatic on the fourth day after admission. Fig. 2 shows the changes in biochemical markers during disease course, Fig. 1B and C shows two cross-sectional slices from the abdominal CT scan, demonstrating the radiological features of AP.

We offered a re-challenge with AZA providing strong evidence about the causative role of the drug since the patient preferred to continue this treatment [8]. For safety reasons, we reduced the daily dose from 150 to 50 mg orally. Approximately 6 h after re-administration, the patient developed abdominal pain (8 of 10 on a visual analogue score), nausea, vomiting, and re-elevation of pancreatic enzymes (Fig. 2). Based on the findings (2 out of 3 criteria of AP), we assessed the challenge as positive for AP (DIAP3). Fluid replacement and immediate enteral feeding were restarted. After three days, his clinical condition significantly improved along with the laboratory markers so that oral feeding was restarted (with a carbohydrate-rich test diet). Since the patient tolerated the food well, we introduced the regular diet within three days. After recovery, the severity of AP was rated as mild according to the Atlanta 2012 criteria [10].

Parallel to the management of AP and after negative stool culturing, we initiated oral metronidazole (3 × 500 mg) and oral methylprednisolone (1 × 48 mg/day) therapy due to the acute flare-up of UC, resulting in a significant improvement in his condition and a reduction of stool frequency to 4–5 voids per day.

On discharge, the continuation of metronidazole and tapering of methylprednisolone were recommended with a medical check-up appointment 1 month later. Further use of AZA and 5-ASA was contraindicated, and monthly medical check-ups were arranged. The inflammatory bowel disease-team (IBD) considered a switch to biological therapy. Last seen 1 year later, he was asymptomatic.

3. Discussion

Here we reported a case of a mild recurrent DIAP triggered by 5-ASA in the first (DIAP1) and AZA in the second episode (DIAP2 and DIAP3) in a young patient with UC. Following the recommendation of the CARE guideline [11], we performed a systematic search for cases of recurrent DIAP triggered by two different IBD drugs in three medical databases (MEDLINE via PubMed, EMBASE and Scopus; details of the search and selection are summarized in Supplementary Appendix 1). After careful selection, four case reports were identified (Table 1) [7,12–14].



Panel A: **Timeline of the case**
Figure 1B *is the CT scan of the 5-ASA induced and* ***Figure 1C*** *is the CT scan of the AZA induced AP.*
Panel B: Contrast-enhanced abdominal CT scan (pancreatic phase). The whole pancreas is enlarged (white arrow indicates the head of the pancreas) and inhomogeneous. There is a peripancreatic infiltration, but no fluid, and no extra pancreatic findings (apart from the features of the known ulcerative colitis); CTSI:2.
Panel C: Contrast-enhanced abdominal CT scan (pancreatic phase). The whole pancreas is enlarged (white arrow indicates the head of the pancreas), there is a slight peripancreatic infiltration, but no visible inhomogeneity or fluid, and no extra pancreatic findings (apart from the features of the known ulcerative colitis); CTSI: 2.
5-ASA: 5-aminosalicylic acid; ***AP:*** acute pancreatitis; ***AZA:*** azathioprine; ***CT:*** computed tomography; ***CTSI:*** computed tomography severity index; ***DIAP:*** drug-induced acute pancreatitis

Fig. 1. Timeline of the case and radiology findings.

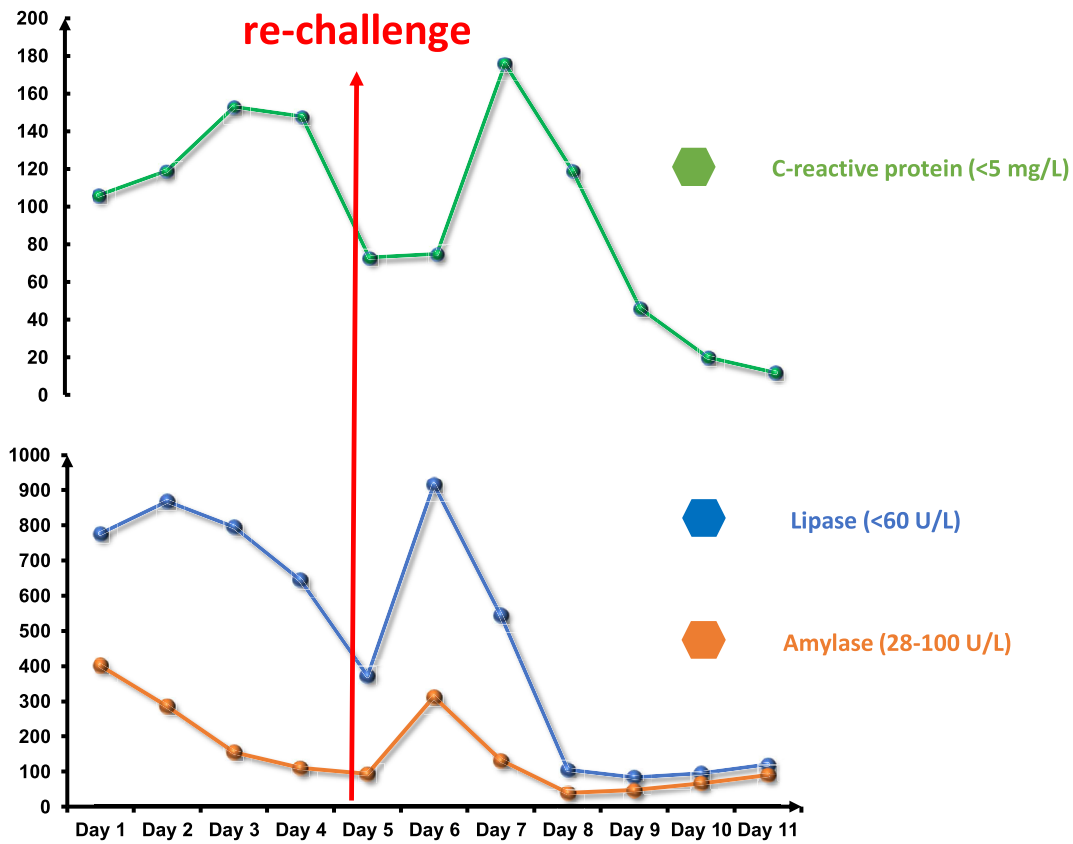

Fig. 2. Laboratory parameters during the azathioprine-induced acute pancreatitis. Time period was between May 07, 2019 and 07/15/2019.

All patients with IBD developed at least two episodes of DIAP due to 5-ASA and AZA, except one reporting four episodes due to AZA, 5-ASA, methotrexate, and infliximab [7]. Patients were young with age ranging from 19 to 47 years. In general, DIAP cases are younger than AP from other etiologies (supported by our data from the Hungarian AP Registry) [27]. Unfortunately, these reports were not detailed enough to establish the disease course of DIAP, except in one article [12], which describes a similar case where 1-year 5-ASA treatment was followed by an episode of AZA triggered mild DIAP. Considering the timing of the development of DIAP, AP developed within 6 months after the administration of the drug (Table 1).

Both of our cases ended up in recovery; however, DIAP seems more severe than that of the AP of other etiology (severe cases accounted for 19.56 vs. 5.63%, respectively; and mortality accounted for 7.66 vs. 2.25%, respectively) [27].

It is important to note that the articles did not use the drug response probability scale developed by Naranjo et al. so we cannot estimate how strong the cause-effect relationship is. In our paper, the Naranjo score was 10 for DIAP2-3, suggesting a definitive role of the drug as the trigger of AP. Most evidence on DIAP is based on anecdotal reports; our knowledge of its true epidemiology is

Table 1
Characteristics of the studies reporting on recurrent drug-induced acute pancreatitis.

Author	Country	Gender	Age (year)	Type of IBD	Cause of DIAP1	Cause of DIAP2
Frossard, J.L. et al., 2010 [7][x]	Switzerland	male	47	ulcerative colitis	3-week mesalazine	10-day azathioprine
Eland, I.A. et al., 1999 [13]	The Netherlands	female	26	not reported	16-day mesalazine: 3 g/day	4-month azathioprine
Toubanakis, Ch. et al., 2003 [12]	Greece	male	19	ulcerative colitis	1-year mesalazine: 2.4 g/day, reduced to 1.2 g/day	7-day azathioprine: 50 mg/day
Glintborg, B. 2000 [14]	Danmark	unknown[a]	unknown[a]	Crohn's disease	mesalazine	azathioprine
Hegyi, J.P. et al., 2020 (the recent publication)	Hungary	male	31	ulcerative colitis	5-week mesalazine: 4 g/day	1-month azathioprine: 150 mg/day

[x] There were two additional DIAPs later after 3-month methotrexate and 3-week infliximab therapy **DIAP:** *drug-induced acute pancreatitis* **IBD:** *inflammatory bowel disease.*
[a] We failed to access the paper; data were retrieved from the abstract only.

limited. Since we rely on the reported frequencies, we cannot judge if there is a tendency for reporting positive or negative findings (in other words, publication bias may be considerable). The role of pharmacovigilance networks as well as AP registries with representative samples may provide more reliable data on the true incidence of DIAP.

While the causative role of AZA was well-supported by the Naranjo score in our case, we must note that the patient received budesonide treatment together with AZA, raising the potential role of budesonide in the development of DIAP2. This is, however, very unlikely because the patient had been treated with budesonide for 6 years between 2012 and 2018 (as indicated in Fig. 1).

DIAP 2 was proven by re-challenge whereas in the case of DIAP1, the possibility of autoimmune pancreatitis (AIP) may arise. However, the pancreas morphology based on CT scan did not match the characteristic traits of AIP. Note that we did not measure IgG4, being sensitive for type 1 but proven insensitive for type 2 AIP. Type 1 AIP could have been definitively confirmed by pancreatic biopsy; however, given the mild course of the disease, further diagnostic workup would not have influenced the therapeutic decisions [15].

DIAP has a continuously increasing incidence from 0.1 to 2% to higher than 5% [16]. More than 500 drugs have been reported to be associated with AP, including thiopurine antimetabolites (e.g., AZA and mercaptopurine, which cases are often termed as thiopurine-induced acute pancreatitis (TIP)) [12,15]. In general, DIAP is classified on a spectrum between class I and IV depending on the number of cases reported and on the results of re-challenge. For instance, AZA and mercaptopurine belong to Class I drugs and are the most likely to induce AP [12,16–18].

The group of purine antimetabolite drugs contains AZA, 6-mercaptopurine (6-MP), and 6-thioguanine [19]. AZA is a prodrug that is metabolized to 6-MP and by glutathione *S*-transferase. 6-MP is transported into cells by the solute carrier and is metabolized via a series of steps to the 6-thioguanine nucleotides. These metabolites cause immunosuppression into DNA and RNA and by blockade of Vav-mediated Rac1 activation, which suppresses Rac1 and thereby T-cell survival and T cell–APC conjugation [20].

The molecular and cellular pathomechanisms underlying TIP are currently unknown [21]; nevertheless, the literature distinguishes theories based on mechanisms mediated via [1] cellular toxicity [2], toxic metabolites, and [3] immunological responses. (ad 1) Thiopurine *S*-methyltransferase (TMPT) is particularly important in the metabolism of AZA [21,22]. In people with reduced TPMT activity, both AZA and mercaptopurine break down slowly, and the active substance 6-thioguanine accumulates, reaches toxic levels, and causes adverse reactions. In patients with zero TPMT activities, the risk of severe bone marrow depression is almost 100% [20–22]. In theory, this mechanism can lead to cellular toxicity in the pancreatic parenchyma as well. (ad 2) Findings based on exocrine pancreatic cells grown from human induced pluripotent stem cells (iPSC) in vitro support that thiopurine biotransformation can induce oxidative stress [23]. (ad 3) iPSC-based models are particularly important in testing the adaptive immunity hypothesis, which proposes that AZA-related lymphocytes activation occurs in pancreatic cells. The involvement of the innate immune system by the activation of macrophages due to lipopolysaccharides was implicated as well; however, evidence for these theories is still awaited [21,24,25].

The mechanism of action of aminosalicylic acid is extensively studied [26]. The active substance of all amino-salicylates is 5-ASA. This has an anti-inflammatory effect in the intestinal mucosa and, although the exact mechanism of action remains unclear, several potential mechanisms are known (e.g., suppression of the release of anti-inflammatory mediators, such as adhesion molecules, chemotactic peptides, tumor necrosis factor-α, interleukin-1, or leukotrienes, thereby protecting the mucosa from the toxic effects of substances released during inflammation) [28,29]. However, the mechanisms by which 5-ASA leads to AP are currently unknown.

The strength of our case report is its novelty (only five recurrent DIAP cases were reported with different IBD drugs yet). Our case is well-documented with a strong cause-effect relationship between AP and drug as indicated by the positive re-challenge and the Naranjo score. We did not measure the AZA level; however, the re-challenge (with a lower dose) helps overcome this deficiency. Since the patient was non-compliant with the treatment of IBD, we do not know if the relapse was due to missing drug doses or the drug was ineffective; neither do know yet if the activity of IBD might contribute to the development of AP.

4. Conclusion

The risk of DIAP, especially that of the recurrent DIAP, is increased in IBD compared to the general population. Two episodes in the same patient from different IBD medications are extremely rarely reported as seen after the literature search. Our case calls attention to the fact that different IBD medications can cause DIAP in the same patient leading to drug intolerance and requiring multiple switches to other therapies. These patients are not only exposed to the potential harm of the adverse reaction (here: DIAP) but also they are at risk of relapse during switching.

Author contributions

Study conception and design: PH, PJH. Acquisition of data: PJH, ZS, NF, BCN. Analysis and interpretation of data: PJH, ZS, JB, BCN. Writing, review and/or revision of the manuscript: PJH, ZS, BCN, PH. Administrative, technical, or material support: PJH. Study supervision: PH.

Financial support

Study costs are covered by an Economic Development and Innovation Operative Programme Grant (GINOP 2.3.2-15-2016-00048) and by a Human Resources Development Operational Programme Grant (EFOP-3.6.2-16-2017-0006) and by a Hungarian National Research, Development and Innovation Fund (FK 124632 to BCN). Sponsors had no role in the design, data collection, analysis, interpretation, and preparations of the manuscript.

Declaration of competing interest

None to declare.

Appendix A. Supplementary data

Supplementary data to this article can be found online at https://doi.org/10.1016/j.pan.2020.10.026.

References

[1] Parniczky A, Kui B, Szentesi A, Balazs A, Szucs A, Mosztbacher D, et al. Prospective, multicentre, nationwide clinical data from 600 cases of acute pancreatitis. PLoS One 2016;11(10):1–19.
[2] Leppäniemi A, Tolonen M, Tarasconi A, Segovia-Lohse H, Gamberini E, Kirkpatrick WA, et al. WSES guidelines for the management of severe acute pancreatitis. World J Emerg Surg 2019;14(27):1–20. 2019.
[3] Meczker A, Mikó A, Gede N, Szentesi A, Párniczky A, Gódi Sz, et al. Retrospective matched-cohort analysis of acute pancreatitis induced by 5-aminosalicylic acid–derived drugs. Pancreas 2019;48(4):488–95.
[4] Vinklerova I, Prochazka M, Prochazka V, Urbanek K. Incidence, severity, and etiology of drug-induced acute pancreatitis. Dig Dis Sci 2010;55:2977–81.
[5] Harbord M, Eliakim R, Bettenworth D, Karmiris K, Katsanos K, Kopylov U, et al. Third European evidence-based consensus on diagnosis and management of

ulcerative colitis. Part 2: current management. J Crohns Colitis 2017;11(7):769–84.
[6] Timmer A, Patton PH, Chande N, Mcdonald WDJ, Mcdonald JK. Azathioprine and 6-mercaptopurine for maintenance of remission in ulcerative colitis. Cochrane Database Syst Rev 2016;18(5):1–39.
[7] Frossard JL, Felley C, Michetti P. Recurrent acute pancreatitis and therapy for ulcerative colitis. Case Rep Gastroenterol 2010;4(3):304–6.
[8] Naranjo CA, Busto U, Sellers EM, Sandor P, Ruiz I, Roberts EA, et al. A method for estimating the probability of adverse drug reactions. Clin Pharmacol Ther 1981;30(2):239–45.
[9] Wu BU, Johannes RS, Sun X, Tabak Y, Conwell DL, Banks PA, et al. The early prediction of mortality in acute pancreatitis: a large population-based study. Gut 2008;57(12):1698–703.
[10] Banks PA, Bollen TL, Dervenis Ch, Gooszen HG, Johnson Cd, Sarr MG, et al. Classification of acute pancreatitis—2012: revision of the Atlanta classification and definitions by international consensus. Gut 2013;62(1):102–11.
[11] Gagnier J, Kienle G, Altman G, Moher D, Sox H, Riley D, et al. The CARE guidelines: consensus-based clinical case reporting guideline development. J Med Case Rep 2013;2(5):38–43.
[12] Toubanakis Ch, Batziou E, Sipsas N, Galanopoluos G, Tzivras M, Archimandritis A. Acute pancreatitis after long-term therapy with mesalazine, and hyperamylasaemia associated with azathioprine in a patient with ulcerative colitis. Eur J Gastroenterol Hepatol 2003;15(8):933–4.
[13] Eland IA, van Puijenbroek EP, Sturkenboom MJ, Wilson JH, Stricker BH. Drug-associated acute pancreatitis: twenty-one years of spontaneous reporting in The Netherlands. Am J Gastroenterol 1999;94(9):2417–22.
[14] Glintborg B. Pancreatitis in a patient with Crohn disease treated with mesalazine and azathioprine. Ugeskr Laeger 2000;162(34):4553–4.
[15] Shimosegawa T, Chari ST, Frulloni L, Kamisawa T, Kawa S, Mino-Kenudson M, et al. International consensus diagnostic criteria for autoimmune pancreatitis: guidelines of the International Association of Pancreatology. Pancreas 2011;40(3):352–8.
[16] Andersen V, Sonne J, Andersen M. Spontaneous reports on drug-induced pancreatitis in Denmark from 1968 to 1999. Eur J Clin Pharmacol 2001;57:517–21.
[17] Badalov N, Baradarian R, Iswara K, Li J, Steinberg W, Tenner S. Drug-induced acute pancreatitis; an evidence-based review. Clin Gastroenterol Hepatol 2007;5(6):648–61.
[18] Lankisch PG, Droge M, Gottesleben F. Drug induced acute pancreatitis, incidence, and severity. Gut 1995;37(4):565–7.
[19] Ledder O, Lemberg AD, Day SA. Thiopurine-induced pancreatitis in inflammatory bowel diseases. Expet Rev Gastroenterol Hepatol 2015;9(4):399–403.
[20] Roberts LR, Barclay LM. Update on thiopurine pharmacogenetics in inflammatory bowel disease. Pharmacogenomics 2015;16(8):891–903.
[21] Stocco G, Lanzi G, Yue F, Giliani S, Sasaki K, Tommasini A, et al. Patients' induced pluripotent stem cells to model drug induced adverse events: a role in predicting thiopurine induced pancreatitis? Curr Drug Metabol 2016;17:91–8.
[22] Asadov Ch, Aliyeva G, Mustafayeva K. Thiopurine S-methyltransferase as a pharmacogenetic biomarker: significance of testing and review of major methods. Cardiovasc Hematol Agents Med Chem 2017;15(1):23–30.
[23] Liese AM, Siddiqi MQ, Siegel JH, Denny T, Spolarics Z. Augmented TNF-alpha and IL-10 production by primed human monocytes following interaction with oxidatively modified autologous erythrocytes. J Leukoc Biol 2001;70(2):289–96.
[24] Reese JA, Li X, Hauben M, Aster R, Bougie D, Curtis B, et al. Identifying drugs that cause acute thrombocytopenia, an analysis using 3 distinct methods. Blood 2010;116(12):2127–33.
[25] Tiede I, Fritz G, Strand S, Poppe D, Dvorsky R, Strand D, et al. CD28-dependent Rac1 activation is the molecular target of azathioprine in primary human CD4+ T lymphocytes. J Clin Invest 2003;111(8):1133–45.
[26] Meczker A, Mikó A, Hegyi P. 5-ASA induces mild acute pancreatitis. Case report and review of the literature. J Gastrointestin Liver Dis 2018;27(2):189–94.
[27] Meczker A, Hanak L, Parniczky A, Szentesi A, Eross B, Hegyi P. Analysis of 1060 cases of drug-induced acute pancreatitis. Gastroenterology DOI: 10.1053/j.gastro.2020.07.016.
[28] Suneela D, Gaurav V, Himanshu R. Design and development of novel azo prodrugs using various permutations and combinations of 5- and 4-aminosalicylic acids for inflammatory bowel disease: a colon-targeted approach. Inflamm Allergy - Drug Targets 2013;12(5):328–40.
[29] Arai Y, Arihiro S, Ide D, Odagi I, Itagaki M, Komoike M, et al. Acute pancreatitis due to pH-dependent mesalazine that occurred in the course of ulcerative colitis. Case Rep Gastroenterol 2011;5(3):610–6.