Histopathology

Histopathology 2021, **78**, 106–124. DOI: 10.1111/his.14275

The pathology of gastric and duodenal polyps: current concepts

Bence Kővári,[1,2] Baek H Kim[2,3] & Gregory Y Lauwers[2]

[1]*Department of Pathology, University of Szeged and Albert Szent-Györgyi Health Center, Szeged, Hungary,* [2]*Department of Pathology, H. Lee Moffitt Cancer Center and Research Institute and Departments of Pathology and Oncologic Sciences, University of South Florida, Tampa, FL, USA, and* [3]*Department of Pathology, Korea University Guro Hospital, Seoul, Korea*

Date of submission 6 July 2020
Accepted for publication 1 October 2020

Kovari B, Kim B H & Lauwers G Y.
(2021) *Histopathology* **78**, 106–124. https://doi.org/10.1111/his.14275

The pathology of gastric and duodenal polyps: current concepts

The liberal use of upper endoscopy has led to an increased detection of gastric and duodenal polyps, which are identified in as many as 6 and 4.6% of patient examinations, respectively. Gastroduodenal polyps are a heterogeneous group of lesions that can be neoplastic or non-neoplastic (e.g. hyperplastic or heterotopical). Most polyps present characteristic topographical features, as well as endoscopic appearance and size. Evaluation of the surrounding mucosa is essential in assessing the underlying pathology (e.g. *Helicobacter pylori*, autoimmune gastritis or inherited polyposis syndromes). Phylogenetically, gastric and duodenal polyps can be classified according to the epithelial compartment from which they derive. Polyps that arise from the surface epithelium can either be of foveolar or intestinal type, and they can develop from either the native mucosa or the metaplastic epithelium (gastric intestinal metaplasia or duodenal foveolar metaplasia). Other polyps develop from the deeper glandular component, such as pyloric/oxyntic gland derived subtypes. In this review we focus upon epithelial polyps, with an emphasis on the most common and clinically relevant lesions, and present recently described entities.

Keywords: adenoma, duodenal polyp, gastric epithelial dysplasia, gastric polyp, intra-epithelial neoplasia, polyposis syndrome

Introduction

Like the other segments of the gastrointestinal (GI) tract, gastroduodenal polyps are a heterogeneous group of lesions that can be either epithelial or non-epithelial and either neoplastic or non-neoplastic (e.g. hyperplastic or heterotopic). The liberal use of upper endoscopy has led to an increased detection of polyps, and gastric and duodenal polyps are identified in as many as 6 and 4.6% of patients, respectively.[1,2] In most cases, these findings are incidental. GI polyps, especially those that are neoplastic, have clinical implications: they may require endoscopic surveillance protocols because of their malignant potential or, if they are manifestations of inheritable syndromes, they may prompt the screening of other organs and of family members.[3] In this review, we describe the broad variety of gastric and duodenal polyps to help guide daily diagnostic practice. We focus on epithelial polyps, with an emphasis on the most common and clinically relevant lesions, and describe several recently identified entities.

Most polyps have characteristic topographical features as well as endoscopic appearance, size and associated pathologies (e.g. *Helicobacter pylori*, autoimmune gastritis or inherited polyposis syndromes).[1,4,5] To precisely evaluate most underlying diseases, it is

Addresses for correspondence: B Kővári, Department of Pathology, University of Szeged and Albert Szent-Györgyi Health Center, Szeged, Hungary. e-mail: kovari.bence.p@gmail.com or Gregory Y Lauwers Department of Pathology, H. Lee Moffitt Cancer Center and Research Institute, Tampa, Florida, USA. e-mail: Gregory.Lauwers@moffitt.org

© 2020 The Authors. *Histopathology* published by John Wiley & Sons Ltd.
This is an open access article under the terms of the Creative Commons Attribution License, which permits use, distribution and reproduction in any medium, provided the original work is properly cited.

essential to assess the mucosa surrounding the lesions.[3,4,6] It should also be pointed out that if a patient is diagnosed with any type of gastric polyp, the probability of their being diagnosed with a subsequent polyp (of any type) increases.[5]

Phylogenetically, gastric and duodenal polyps can be classified according to the epithelial compartment from which they derive. Those arising from the surface epithelium, from the native mucosa or from the metaplastic epithelium (gastric intestinal metaplasia or duodenal foveolar metaplasia) can be either of foveolar or intestinal type. Other polyps develop from the deep glandular component, such as pyloric/oxyntic gland-derived subtypes (Figure 1).

Gastric polyps

The prevalence of different subtypes of gastric polyps varies depending on geographic location and predisposing factors, such as *Helicobacter pylori* infection and autoimmune gastritis. Furthermore, the frequency of the occurrence of specific subtypes has changed over the last two decades. The incidence of fundic gland polyps (FGPs) has increased substantially with the widespread use of proton pump inhibitors (PPIs). Conversely, following the decreasing rate of *H. pylori* infection, hyperplastic polyps have become less frequently observed in North America.[1,4,5,7] One study showed that the proportion of hyperplastic polyps decreased from 48.5 to 20.8%, whereas the proportion of FGPs increased from 8.8 to 66.1.[7] In a recent study of more than 700 000 North American patients who underwent an upper endoscopy, it was found that 7.7% of these patients were diagnosed with FGPs, 1.8% with hyperplastic polyps, 0.1% with gastric adenomas and 0.06% with type I neuroendocrine tumours (NETs).[5] More broadly, in the adult population more than 90% of all gastric polyps are comprised of FGPs (47–77%) and hyperplastic polyps (17–55%).[1,4,8,9] All subtypes of adenomas (i.e. intestinal, foveolar, pyloric and oxyntic gland variants) represent only 1–10% of these cases.[1,8–10] Of these subtypes, intestinal-type adenomas (56%) and foveolar-type adenomas (41%) are the most common;[11] the prevalence of pyloric gland adenomas (PGAs) and oxyntic gland adenomas (OGAs) is not well established. PGAs were reported to comprise 2.7% of all gastric polyps, but this series did not account for FGPs.[12]

Surface epithelium-derived polyps

HYPERPLASTIC POLYPS

Hyperplastic polyps are the second most common type of gastric polyps, and are most frequently present in patients during the sixth and seventh decades of life. They are the most commonly diagnosed polyps among children, representing 42% of all paediatric gastric polyps. A slight female predominance is not universally recognised.[5] Hyperplastic polyps are commonly associated with underlying gastritis, and they develop frequently in a background of intestinal metaplasia (37%), *H. pylori* gastritis (25%), chemical/reactive gastropathy (21%) and autoimmune gastritis (12%). Associations with gastric antral vascular ectasia (GAVE) and cytomegalovirus gastritis have been reported.[5,13]

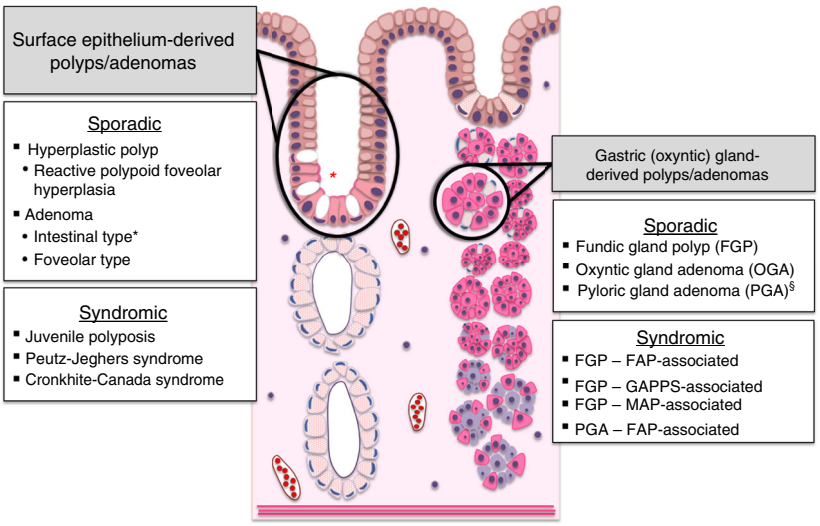

Figure 1. Classification of gastric polyps according to the mucosal compartment of origin. *Preceded by intestinal metaplasia. §May be preceded by pseudopyloric metaplasia or, according to some authors, may represent a 'glandular adenoma' resulting from mucus neck cell differentiation of oxyntic glands.

© 2020 The Authors. *Histopathology* published by John Wiley & Sons Ltd, *Histopathology*, **78**, 106–124.

Hyperplastic polyps are typically solitary and antral predominant (60%). Multiple polyps are present in 20% of cases, and the term 'hyperplastic polyposis' has been used for cases with > 50 polyps. Hyperplastic polyps are mainly broad-based and have a smooth, lobulated contour. Most cases are < 20 mm but can grow up to 120 mm in size. The risk of neoplastic transformation is increased for lesions > 25 mm. Large lesions usually become eroded. Hyperplastic polyps are composed of irregular, elongated and tortuous pits with outpouchings, cystic dilations and papillary configurations (Figure 2A). The foveolar epithelium displays a characteristic apical neutral mucin cap, which can be highlighted with negative Alcian blue/periodic acid-Schiff (AB-PAS) reactions. The epithelium is also immunoreactive for mucin core protein (MUC) 5AC, but lacks expression of intestinal markers such as MUC2, CDX2 and CD10 (Table 1). The foveolar cells can develop overt hypertrophic features, with the formation of clustered pseudogoblet cells or even pseudosignet-ring cells – especially in damaged areas. Pseudogoblet cells are shown to be filled with slightly pinkish mucin on haematoxylin and eosin (H&E)-stained slides (as opposed to the blueish hue of true goblet cells) (Figure 2F). *Helicobacter pylori* infection is present in 6–20% of hyperplastic polyps,[5,14] and polyps may regress after antibiotic therapy.[15] The lamina propria is characteristically oedematous, with variable numbers of lymphocytes, plasma cells and eosinophils. An eroded surface attracts a marked granulocytic infiltrate and is associated with mucin-depleted regenerative epithelium, with nuclear hyperchromasia and enlarged nucleoli that can mimic dysplasia. Some hyperplastic polyps can exhibit thick-walled blood vessels and prominent smooth muscle bundles that radiate from the deep muscularis mucosae, owing to a mucosal prolapse phenomenon (Figure 2B); these cases are commonly observed in the antropyloric region and are more frequently sessile than the classic variant.[14] Intestinal metaplasia (4–16%) and (rarely) dysplasia (4%) can be detected. Dysplastic foci may exhibit both foveolar end intestinal phenotypes,[16] the histological features of which are detailed in the adenoma section in the present article. It is worth noting that, in some series, dysplasia is more often diagnosed in the surrounding flat mucosa than in the polyp proper.[8] The reported rate of malignant transformation shows considerable differences from 0.8 to 10% of cases (Table 2).[17,18] Most hyperplastic

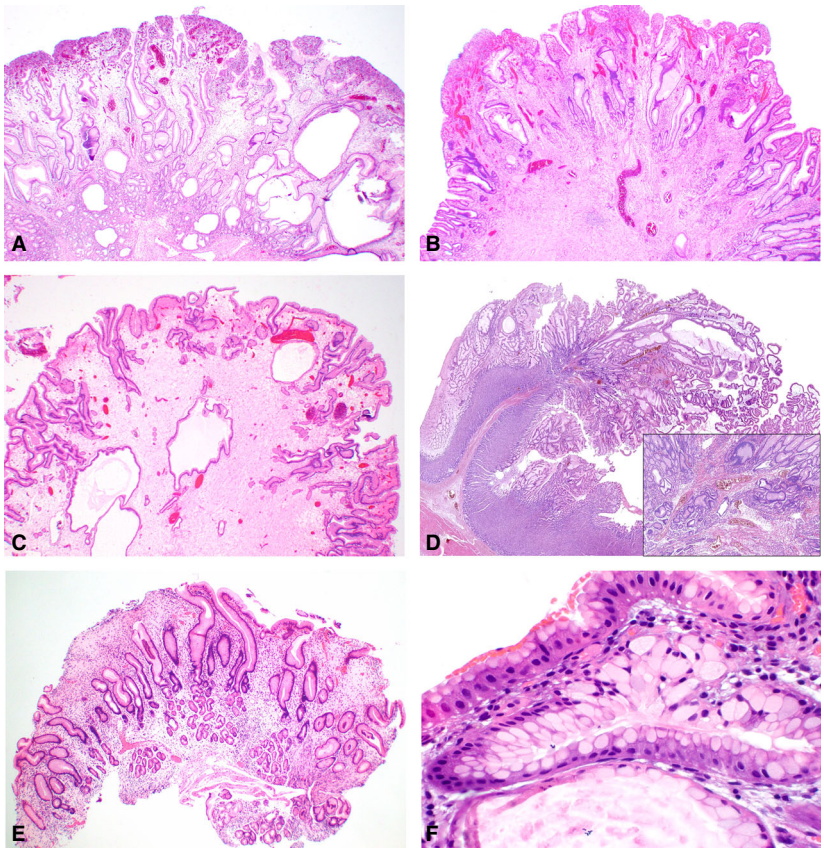

Figure 2. Gastric hyperplastic polyps: subtypes and differential diagnoses. A, The classic hyperplastic polyp, while (B) shows a lesion with prominent blood vessels and radiating smooth muscle bundles probably indicative of mucosal prolapse phenomenon. B, A juvenile polyp, notoriously difficult to differentiate in superficial biopsy material. Peutz–Jeghers polyps (D) can be distinguished from hyperplastic polyps by the recognition of smooth muscle nesting or arborising (insert). However, this unique feature is uncommon. Cronkhite–Canada syndrome diffusely involves the gastric mucosa, with more polypoid areas reminiscent of inflammatory or juvenile polyps (E). F, 'Pseudogoblet' cells, a common cytological change in foveolar hyperplasia, that should not be mistaken for true goblet cells.

Table 1. Endoscopic, histologic features and characteristic molecular alterations of gastric and duodenal polyp types

Gastric polyps	Background mucosal alterations	Ancillary studies	Molecular alterations	Differential diagnosis
Surface epithelium-derived				
Hyperplastic polyp	*Helicobacter pylori* gastritis Autoimmune gastritis Reactive gastropathy	PAS: positive (neutral) mucin cap MUC5AC+++	Large/dysplastic polyps: *TP53*, *APC* or *CTNNB1*, *KRAS* or *BRAF*	Foveolar adenoma Reactive polypoid foveolar hyperplasia Gastritis cystica polyposa Peutz–Jeghers polyp Juvenile polyp
Intestinal adenoma	Chronic atrophic gastritis	AB: positive goblet cells PAS-AB: positive brush border CDX2, CD10 and MUC2+++	*APC*, *KRAS*, *ERBB3*, and *TP53*	Reactive atypia in intestinal metaplasia Other types of adenomas (especially foveolar) Adenocarcinoma
Foveolar adenoma	Disputed association with chronic atrophic gastritis	PAS: positive (neutral) mucin cap MUC5AC+++ MUC6 scattered	*APC*, *KRAS*, *ERBB3* and *TP53*	Reactive atypia in proliferative foveolar epithelium (e.g. hyperplastic polyp) Other types of adenomas (especially intestinal and pyloric gland adenoma) Adenocarcinoma
Gastric (oxyntic) gland-derived				
Fundic gland polyp	Unremarkable	–	Non-syndromic: *CTNNB1* (10–90%) FAP-related: *APC* (50%)	Oxyntic gland adenoma
Pyloric gland adenoma	Autoimmune gastritis	PAS: no mucin cap MUC6+++ MUC5AC+	Non-syndromic: *GNAS* (63–83%), and *KRAS* (41–67%) FAP-associated: *APC*	Foveolar adenoma Other adenomas (especially oxyntic gland adenoma)
Oxyntic gland adenoma	Unremarkable	PAS: no mucin cap MUC6+++ H/K+–ATPase: parietal cells Pepsinogen-I: chief cells	*CTNNB1*, *APC* and *GNAS*	FGP Other adenomas (especially pyloric gland adenoma) Adenocarcinoma of fundic gland type
Duodenal polyps				
Surface epithelium-derived				
Intestinal adenoma	Unremarkable	AB: positive goblet cells PAS-AB: positive brush border CDX2, CD10 and MUC2+++	*APC* and *KRAS*	Reactive atypia Other adenomas (especially foveolar) Adenocarcinoma

© 2020 The Authors. *Histopathology* published by John Wiley & Sons Ltd, *Histopathology*, **78**, 106–124.

Table 1. *(Continued)*

Gastric polyps	Background mucosal alterations	Ancillary studies	Molecular alterations	Differential diagnosis
Foveolar adenoma	Foveolar metaplasia/ gastric heterotopia	PAS: positive (neutral) mucin cap MUC5AC+++ MUC6 scattered	Unknown	Reactive atypia in proliferative foveolar epithelium (e.g. hyperplastic polyp) Other adenomas (especially intestinal and pyloric gland adenoma) Adenocarcinoma
'Gastric/Brunner gland-derived'				
Pyloric gland adenoma	Gastric heterotopia/ Brunner gland proliferative lesions	PAS: no mucin cap MUC6+++ MUC5AC+	*GNAS* and *KRAS*	Reactive atypia in proliferative Brunner gland lesions Other adenomas (especially intestinal and pyloric gland adenoma) Adenocarcinoma

AB, alcian blue; FAP, familial adenomatous polyposis; FGP, fundic gland polyp; MUC, mucin core protein; PAS, periodic acid–Schiff.

polyps harbouring dysplasia or adenocarcinoma are more than 20 mm in size.[17,19]

To date, most studies have reported an absence of pathogenic mutations in small non-dysplastic hyperplastic polyps, which implies a truly non-neoplastic and reparative/hyperplastic nature. However, genetic alterations have been identified in large hyperplastic polyps, especially in those associated with dysplasia or adenocarcinoma (Table 1).[20,21] Detected immunohistochemical and molecular abnormalities include loss of O^6-methylguanine-DNA methyl-transferase (MGMT) expression, *APC* or *CTNNB1* (beta-catenin) mutations, and less frequently *KRAS* or *BRAF* alterations.[22] Dysplastic hyperplastic polyps also frequently harbour *TP53* mutations, and p53 immunohistochemistry has been used as an ancillary technique for the differential diagnosis of reactive atypia versus dysplasia.[23] The differential diagnosis of hyperplastic polyps includes regenerative foveolar exophytic growth, such as reactive polypoid foveolar hyperplasia, which is frequently associated with reactive gastropathy and detected in the antropyloric region, adjacent to erosions or ulcers. Reactive polypoid foveolar hyperplasia is usually sessile and smaller than hyperplastic polyps.

Another lesion to rule out is gastritis cystica glandularis/profunda, which develops in patients with previous gastrectomy or stomas and is characterised by cystically dilated glands herniated into the submucosa and muscularis propria. Furthermore, hamartomatous polyps show considerable morphological overlap with hyperplastic polyps and can be virtually indistinguishable (Table 3). Some subtle histological features can be suggestive of the diagnosis; however, it is frequently impossible to identify these features in superficial biopsies and in the absence of proper clinical information.

Juvenile polyps present with large cystically dilated glands and an overtly oedematous stroma that is rich in neutrophil granulocytes (Figure 2C), whereas Peutz–Jeghers polyps may contain, in rare cases, the characteristic arbourising smooth muscle bundles (Figure 2D). However, in some examples, desmin immunohistochemistry can demonstrate a nesting pattern/ lobulated arrangement. Ménétrier disease and Cronkhite–Canada syndrome may also need to be ruled out. The most important differentiating feature of these conditions is their diffuse mucosal involvement rather than the formation of distinct polyps. Ménétrier disease shows glandular atrophy of the oxyntic mucosa and lacks significant inflammation. Mucosal polypoid areas in Cronkhite–Canada syndrome can resemble inflammatory or juvenile polyps, with a mixed inflammatory infiltrate that is rich in eosinophils in the lamina propria and the glandular epithelium as well as crypt abscesses (Figure 2E).[24] In Cowden disease, the peculiar diverse stromal attributes may assist in reaching an accurate diagnosis.[24] Finally, low-grade foveolar adenomas can be particularly difficult to diagnose because the dysplastic changes can be subtle and misdiagnosed as hyperplastic polyps.

The management of hyperplastic polyps is determined by the size of the lesions and whether dysplasia is detected (Table 2). Endoscopic resection is advised for polyps that harbour biopsy-proven dysplasia (usually> 10 mm), have pedunculated

morphology and are symptomatic. Antibiotic therapy and re-endoscopy have been suggested for patients with *H. pylori* gastritis, although large polyps (> 30 mm) should be resected. The background mucosa should also be evaluated for atrophic gastritis and intestinal metaplasia. Subsequent endoscopic surveillance for gastric neoplasia is recommended, depending on the stage of preneoplastic changes.[3]

SURFACE EPITHELIUM-DERIVED ADENOMAS (FOVEOLAR AND INTESTINAL ADENOMAS)

In contrast to gastric epithelial dysplasias, which are endoscopically flat, gastric adenomas are exophytic/polypoid dysplastic epithelial growths that bulge into the lumen. Gastric adenomas are rarely detected in otherwise normal mucosa but usually develop on the background of mucosal injury. Adenomas represent direct precursors of adenocarcinomas and indicate a higher risk of adenocarcinoma elsewhere in the stomach. Two histological types of adenomas are recognised. Intestinal-type adenoma represents 56% of cases and can be regarded as the conventional form, morphologically similar to conventional colonic adenomas. Foveolar-type adenoma (or type II dysplasia) represents 41% of the cases. Gastric foveolar dysplasia, which develops in FGPs of patients with familial adenomatous polyposis (FAP), is a biologically distinct entity with regard to prevalence, progression and treatment. It is discussed in the FGP section of the present article.

Gastric adenomas are usually diagnosed incidentally. Their incidence increases with age (peak = 70s–80s), with a male predominance (2:1 male to female ratio). In a US cohort study, Abraham *et al.* reported chronic gastritis, intestinal metaplasia, gastric atrophy, autoimmune gastritis and *H. pylori* infection to be associated with the intestinal phenotype, and the foveolar phenotype to arise in normal gastric mucosa.[11] Conversely, the Korean series of Park *et al.* showed no difference between either histological type in the mucosal background.[25] Gastric enterochromaffin-like cell NETs, another complication of autoimmune gastritis, are frequently (odds ratio = 19) diagnosed in patients with adenomas.[5]

Most gastric adenomas are localised in the antrum and present as solitary lesions (82%).[11] Although they can be multiple, true adenomatous polyposis of the stomach has never been reported. Adenomas range in size from a few millimetres to several centimetres and may be sessile or pedunculated. Although the risk of malignancy increases with size

Table 2. Clinical management of sporadic gastric and non-ampullary duodenal polyps

	Gastric							Duodenal		
	Hyperplastic polyp			Adenoma				Adenoma		
	Without dysplasia	With dysplasia	Dysplastic FGP*	With LGD	With HGD	PGA	OGA	With LGD**	With HGD	PGA
Risk of progression to adenocarcinoma	0.8–10%		4%	0.6% annual	6% annual	12–47%	Unknown	4.7%	55%	10.5–66%
Recommendations	EMR for> 10 mm or symptomatic. No follow-up	EMR with annual follow-up	Resection with annual follow-up	< 10 mm: EMR > 10 mm: ESD Follow-up: annual		Not currently established Refer to adenomas		< 10 mm: cold snare polypectomy > 10 mm: EMR with annual follow-up	EMR with annual follow-up	Not currently established; Refer to adenomas

AC, adenocarcinoma; EMR, endoscopic mucosal resection; ESD, endoscopic submucosal dissection; FAP, familial adenomatous polyposis; FGP, fundic gland polyp; GAPPS, gastric adenocarcinoma and proximal polyposis of the stomach; HGD, high-grade dysplasia; LGD, low-grade dysplasia; OGA, oxyntic gland adenoma; PGA, pyloric gland adenoma.
*The risk of progression of sporadic FGP with LGD is ~1 versus 25–45% for FAP-associated FGP and probably even higher in the setting of GAPPS.
**the risk of progression of adenoma with LGD to HGD is 21%.

Table 3. Genetic background, gastroduodenal manifestations and clinical management of GI polyposis syndromes

	Gene/ inheritance	Inheritance	Type of polyps	GI cancer risk	Other manifestations/clinical features	Management
FAP & AFAP	*APC*	AD	Stomach: FGPs, fundic gland polyposis syndrome, PGAs Duodenum: intestinal adenomas	Stomach: 1–2% Duodenum/ampulla: 4–12% Colon: FAP 100%; AFAP 70%	Colonic polyposis (FAP> 100, AFAP < 100 polyps) Extra GI tumours: thyroid, pancreas, liver, CNS, bone & soft tissue	EGD surveillance starting at age 25 with interval according to duodenal Spigelman score*
GAPPS	*APC* (1B promoter)	AD	Stomach: FGPs	Undetermined	None at this time	Currently no guidelines; prophylactic gastrectomy and endoscopic surveillance
MAP	*MUTHY*	AR	Stomach: FGPs Adenomas Duodenum: adenomas	Gastric:1% Duodenum: 4% Colon: 19–43%	Colonic polyposis (< 100) Lynch syndrome-like (without polyps)	EGD surveillance starts at age 35 with intervals According to duodenal Spigelman score*
Peutz–Jeghers syndrome	*STK11*	AD	Hamartomatous polyps with smooth muscle bundles	Stomach: 29% Small bowel: 13% Pancreas: 11–36% Colon: 15–57%	Hyperpigmented mucocutaneous macules	EGD and MRI/capsule enteroscopy surveillance start at age 8 with 1–3 years interval
Juvenile polyposis syndrome	*BMPR1A*, *SMAD4*	AD	Hamartomatous polyps with prominent stromal oedema and cystically dilated glands PGAs (rarely)	Stomach/small bowel/pancreas: 21% Colon: 39–68%	NA	EGD surveillance starts at age 18–25 (*SMAD4*) and (*BMPR1A*, respectively) with 1–3 years interval
Cronkhite–Canada syndrome	Non-inherited	–	Inflammatory polyps with oedematous lamina propria and also diffuse hyperplastic foveolar changes involving the non-polypoid mucosa	Stomach: 21% Colon: 41%	Abnormal skin pigmentation and nail dystrophy	EGD surveillance recommended with no specifications available
PTEN Hamartoma Tumour (Cowden) syndrome	*PTEN*	AD	Hamartomatous- polyps with stromal changes Ganglioneuromatosis	Colon: 9–16%	Trichilemmoma, acral keratosis Oesophageal glycogenic acanthosis Macrocephaly and intellectual disability Breast and thyroid tumours	EGD surveillance starts at age 35–40 with 2–5 years interval

AD, autosomal dominant; AFAP, attenuated familial adenomatous polyposis; AR, autosomal recessive; EGD, oesophagogastroduodenoscopy; FAP, familial adenomatous polyposis; FGP, fundic gland polyp; GAPPS, gastric adenocarcinoma and proximal polyposis of the stomach; MAP, MUTYH-associated polyposis; MRI, magnetic resonance imaging; NA, not available; PGA, pyloric gland adenoma; PTEN, phosphatase and tensin homologue.
*Based on the number and size of polyps, histological architecture and severity of dysplasia endoscopic surveillance interval varies from 6 months to 4 years.

(> 20 mm), smaller adenomas can also harbour invasive adenocarcinoma.[19] The recently described raspberry-like endoscopic variant of adenoma that develops in a non-atrophic, *H. pylori*-negative mucosa has been proposed as a distinct presentation of foveolar adenoma. Due to their morphological similarities with hyperplastic polyps and their usually low degree of atypia, hyperplastic polyp-like lesions arising in otherwise healthy mucosa should be thoroughly evaluated to exclude a low-grade foveolar adenoma.[26]

Gastric intestinal and foveolar adenoma can usually be diagnosed and subtyped using H&E slides (Table 1). Intestinal adenomas are fundamentally indistinguishable from colonic adenomas. They are characterised by pseudostratified columnar epithelium, elongated, pencil-shaped and overlapping nuclei and clumped chromatin. A variable number of interspersed goblet cells (Figure 3) can be observed. Paneth cells, absorptive cells with a brush border and even neuroendocrine cells are commonly detected.[25] Most polyps have a tubular growth pattern, but tubulovillous or villous architecture can also be observed. Like hyperplastic polyps, foveolar adenomas are composed of columnar or cuboidal foveolar epithelium with an apical neutral mucin cap (Figure 4). Although the diagnosis of adenoma requires unequivocal neoplastic features, low-grade polyps can be challenging to distinguish from hyperplastic/regenerative foveolar epithelium (with their small round-to-oval cells and basally orientated nuclei) without considerable stratification. Foveolar adenomas characteristically express MUC5AC and variably MUC6, whereas intestinal-type adenomas are positive for MUC2, CD10 and CDX2. In addition, many polyps with indeterminate or hybrid features are recognisable. On H&E stains, some cases devoid of characteristic cytoplasmic mucin production (reminiscent of either goblet cells or foveolar cells) may be classified as indeterminate (3.3%).[11] Hybrid lesions with expression of both intestinal and gastric markers are detectable via immunohistochemistry.[25] However, routine subtyping is not recommended due to a lack of proven clinical relevance.

Both histological subtypes of gastric adenoma harbour alterations in the *APC*, *KRAS*, *ERBB3* and *TP53* genes and may also show mismatch repair (MMR) gene inactivation (Table 1).[27] No significant difference in the frequency of specific molecular alterations has been detected between the two phenotypical variants.[28] Interestingly, several studies have demonstrated that *APC*-mutated gastric dysplasia may be considered a more indolent tumour, which rarely progresses to adenocarcinoma, whereas dysplasia with a TP53 mutation could represent a more aggressive subtype.[29,30] Whether p53 immunohistochemistry can be used as a predictive biomarker of progression has not been investigated, and whether intestinal and foveolar-type adenomas behave differently is contested (Table 2). Whereas Abraham *et al.* suggested that the intestinal phenotype is more frequently associated with high-grade dysplasia and malignant transformation,[11] Park *et al.* reported that foveolar lesions are frequently detected with high-grade morphology.[25] Nevertheless, these two studies used different definitions (H&E versus immunohistochemistry) and were based on two different populations (North American and South Korean). A Portuguese study evaluating non-polypoid gastric dysplasias also concluded that the foveolar phenotype is the biologically more aggressive subtype of the two.[31]

Gastric adenomas should be resected endoscopically when technically possible. Endoscopic mucosal resection (EMR) is usually preferred for the removal of smaller lesions. In contrast, endoscopic submucosal dissection is advisable for larger (> 15 mm) or broad-based polyps to achieve negative margins and because of the higher risk of invasive neoplasia. Endoscopic surveillance should be performed 6–12 months after excision and annually thereafter. An assessment of the background mucosa should be performed to identify synchronous neoplasia, gastric atrophy or intestinal metaplasia.[3]

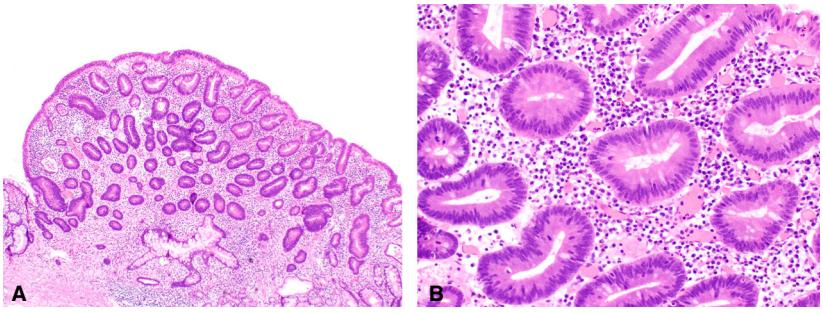

Figure 3. Gastric intestinal adenoma. This lesion is morphologically similar to conventional colonic adenomas.

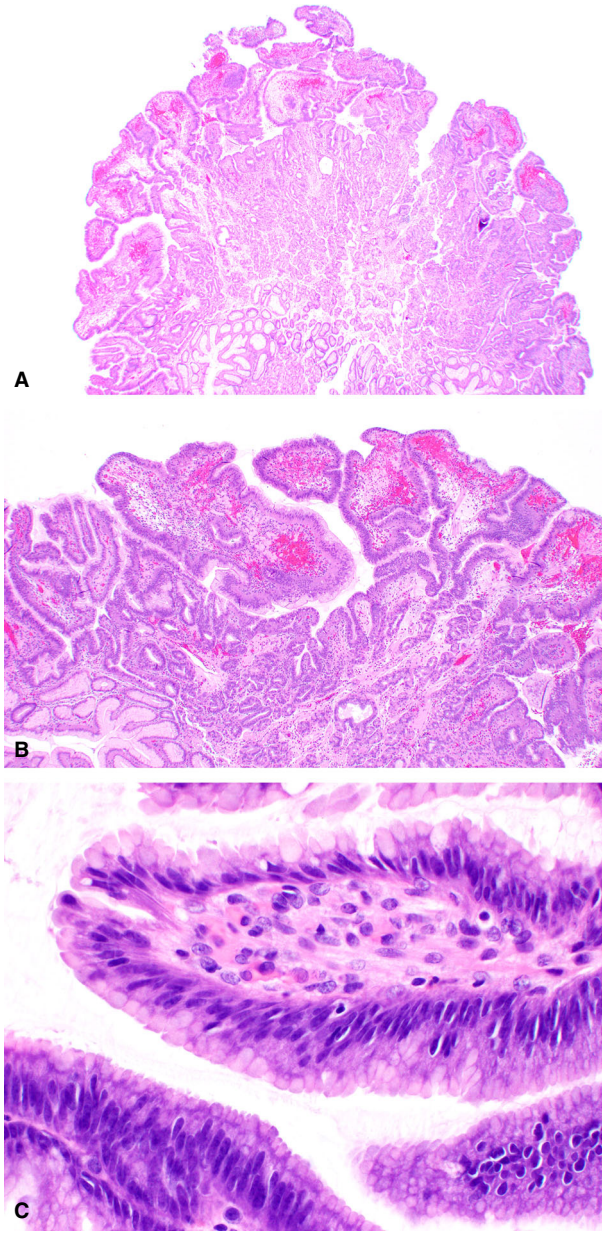

Figure 4. Gastric foveolar adenoma. This broad-base (A), villiform (B) dysplastic lesion is lined by tall clear foveolar cells with distinct mucin cap (C).

Gastric (oxyntic) gland-derived polyps/adenomas

The category of gastric (oxyntic) gland-derived polyps/adenomas incorporates FGPs as well as rarer lesions, such as PGAs and OGAs. Given their shared *GNAS* mutations,[32–34] PGAs and OGAs are thought to represent diverse manifestations along a single spectrum of lesions, with the ability to differentiate between the various cell types of the oxyntic gland. Accordingly, gastric glandular adenomas with predominantly parietal and chief cell differentiation are equivalent to OGAs, whereas tumours predominantly composed of mucous neck cells are analogous to PGAs.[32] This observation is also supported by the occurrence of hybrid lesions with mixed cell types and the unique location of these polyps.

Fundic gland polyps

FGPs develop in various clinical settings: as a consequence of PPI therapy; sporadically; in hereditary polyposis syndromes (Table 3), such as FAP,[35] gastric adenocarcinoma proximal polyposis of the stomach (GAPPS)[36] and rarely MUTYH-associated polyposis (MAP);[37] and possibly in patients with Zollinger–Ellison syndrome. Because of the growing use of PPI, the incidence of FGP has increased substantially in the last two decades, although geographical heterogeneity exists due to the variable prevalence of PPI therapy and *H. pylori* infection (which can inhibit the formation of FGP). Non-syndromic polyps are most frequently diagnosed at 40–60 years of age, with a female predominance. In the syndromic setting, FGPs usually develop at a younger age (20–40 years), without a gender predilection. Rarely are FGPs seen in paediatric patients, a diagnosis that should prompt evaluation for syndromic association. FGPs are less commonly detected in the setting of gastritis, *H. pylori* infection, intestinal metaplasia or atrophy than in normal controls. The knowledge of ongoing PPI therapy, or positive family history for FAP, GAPPS or MAP may support the diagnosis.[5]

FGPs present as small (1–7 mm), round, translucent polyps that have a smooth surface. They arise exclusively in the oxyntic mucosa, surrounded by an endoscopically otherwise-normal mucosa. Sporadic cases typically appear as a solitary polyp; however, up to 25% of non-syndromic patients may develop multiple (usually 2–15) FGPs. In the syndromic setting, 40–80% of patients with FAP and most patients with GAPPS are detected with more than 100 polyps. Microscopically, FGPs show cystically dilated fundic glands that are lined predominantly with parietal cells and, variably, chief cells or foveolar/mucous neck cells (Table 1). The FGPs of patients on PPI therapy tend to develop markedly dilated fundic gland cysts, foveolar cell hyperplasia and parietal cells with cytoplasmic blebs projecting into the lumen, which creates a hobnail morphology (Figure 5A).[38] Parietal cell hyperplasia/hypertrophy is also common in the

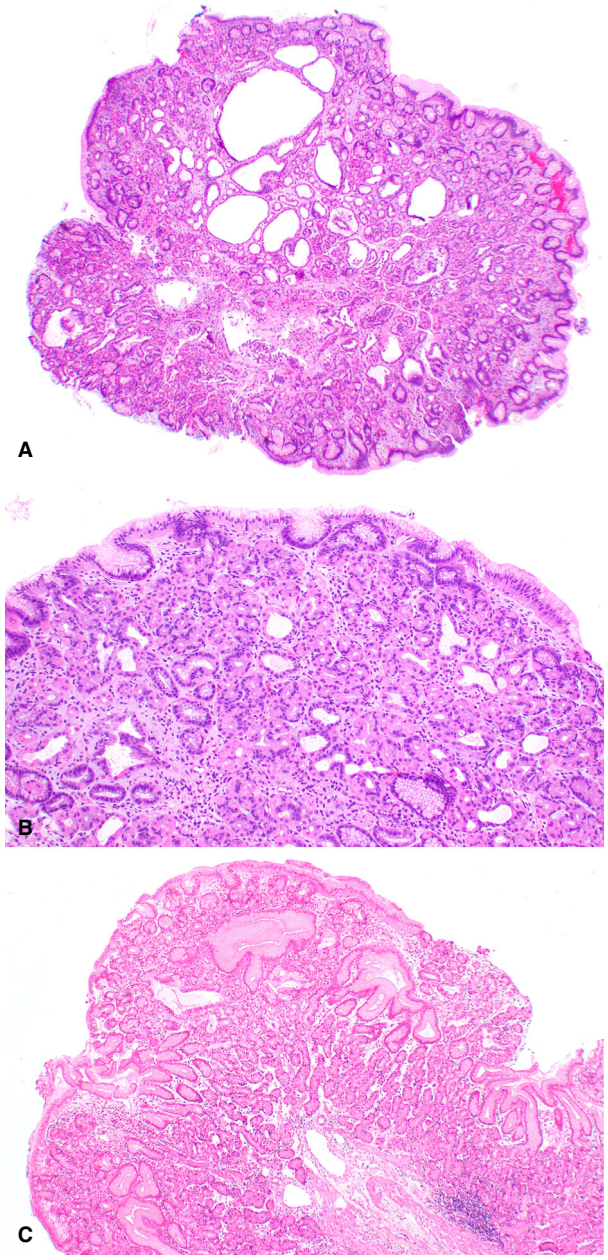

Figure 5. Fundic gland polyp (FGP). Histological variability of FGPs in relation to the clinical association. Note the difference between (A), the typical proton pump inhibitor (PPI)-associated FGP, in comparison to (B) a smaller familial adenomatous polyposis (FAP)-associated FGP and (C) larger gastric adenocarcinoma proximal polyposis of the stomach (GAPPS)-associated polyp.

background mucosa of patients on PPI therapy. Inheritable polyposis-related polyps present different attributes (Figure 5B,C).[39] FAP-related FGPs are usually smaller and more frequently display small microcysts that are almost solely lined by fundic epithelium without significant parietal cell hyperplasia. The surface is usually devoid of foveolar hyperplasia. GAPPS-associated FGPs are large, with prominent microcysts lined with predominantly foveolar-type epithelium and inverted foveolar hyperplasia or hyperproliferative aberrant pits. Parietal cell hyperplasia is an uncommon feature. Dysplastic transformation is rare in non-syndromic cases (1%).[40] Alternatively, in syndromic FGPs, there is a 25–46% frequency of dysplastic transformation, usually of foveolar type.[41] The progression rate from low- to high-grade dysplasia or adenocarcinoma is low (4% in 6-year mean follow-up) in FAP-related cases[41] but higher among patient with GAPPS (Table 2).[36]

FGPs have been classically regarded as hamartomatous lesions. Recently, based on the detection of varying genetic alterations (Table 1), it was reported that most FGPs are clonal lesions. Sporadic FGPs harbour activating *CTNNB1* (β-catenin) mutations in 10–90% of cases,[38,42] and FAP-related dysplastic FGPs show somatic *APC* gene alterations in 50% of cases.[35] GAPPS families have been identified to have point mutations in the *promoter 1B* of *APC* gene,[36] whereas patients with MAP are affected by bi-allelic mutations in the *MUTYH* gene encoding DNA repair (base excision pathway) protein.[37] Whether sporadic FGPs should be considered neoplastic rather than hamartomatous lesions is still debated as a matter of how neoplasia should be defined. Regardless of this nosological conundrum, dysplastic changes are extremely rare in sporadic FGPs, and progression to adenocarcinoma has never been reported. In our opinion, the presence of genetic alterations supports a true clonal origin, and the lack of cytological atypia and very low potential to progress into malignancy do not contradict the possibility of a neoplastic nature, given that this absence is accepted for other well-differentiated neoplasms (e.g. uterine leiomyomas).

In the absence of atypical features, such as large size (> 10 mm), antral location or ulceration, removal is not required. Targeted biopsies can be considered when excision is not possible. PPI-associated cases should be reviewed for the indication of the PPI therapy and appropriateness of the dosage; furthermore, alternative treatments should be considered. Surveillance endoscopy is not needed in non-syndromic cases. As mentioned earlier, the possibility of syndromic FGPs should be considered when treating young patients (aged < 40 years) and in cases with a large number of polyps (> 20) and a suspicion of dysplastic changes (atypical surface or vascular pattern). The presence of simultaneous duodenal adenomas should raise the possibility of FAP or MAP. Dysplastic

FGPs should be endoscopically resected and patients subjected to annual follow-up.[3]

Pyloric gland adenoma

PGAs most frequently present in the stomach,[12,43,44] although they can also develop in the oesophagus,[45] duodenum,[12,46] rectum,[47] gallbladder[12,48] and bile ducts.[12] Gastric PGAs mainly develop in three clinicopathological settings: the chronic atrophic gastritis-associated setting (particularly autoimmune gastritis), the hereditary cancer predisposition syndrome-associated setting (Table 3) and, sporadically, in the normal mucosal background. Presumably, due to the high proportion of autoimmune gastritis, PGAs primarily occur in females (52%), and the mean age at diagnosis is in the seventh decade. Syndromic cases occur at a younger age.[49,50] The association with adenocarcinoma initially noted in 12–30% of cases has not been confirmed by recent series.[12,51] PGA is only one among various types of polyps more commonly detected in the setting of autoimmune gastritis, along with hyperplastic polyps and NETs.[12,49,51] PGAs have also been detected in patients with FAP, Lynch syndrome and juvenile polyposis syndrome (JPS).[32,44,49,50,52–54] Nevertheless, in more than a third of these cases, no underlying gastric disease has been identified.[12,49]

Gastric PGAs are most often detected in the oxyntic mucosa, with a mean size of 20 mm. Low-grade PGAs are composed of tightly packed, uniform tubules lined by a monolayer of cuboidal to low columnar cells with pale eosinophilic cytoplasm as well as basal, round nuclei and open chromatin (Figure 6, Table 1).[12,43,44,49,51,55] The cells show a characteristic ground-glass appearance and, unlike foveolar cells, do not have a well-formed apical mucin cap. The stroma is usually scant. High-grade lesions display a more complex architecture, often of cribriform appearance, and worrisome cytological features, including a higher nucleus to cytoplasm ratio, hyperchromasia, loss of nuclear polarity and prominent nucleoli.[51] Due to decreased mucin production the cytoplasm can be more eosinophilic. Immunohistochemically, the hallmark of pyloric gland differentiation is MUC6 expression, although positivity for the primarily foveolar marker MUC5AC is frequently detected at least focally.[43,44,51,55] Recently, three patterns have been recognised: 'mixed type' (the most common, with variable proportions of MUC6 and MUC5AC labelling), 'pure pyloric type' (characterised by diffuse MUC6 staining but with MUC5AC still expressed in the superficially overlying foveolar epithelium) and a rare 'predominant foveolar-type' (with diffuse MUC5AC expression

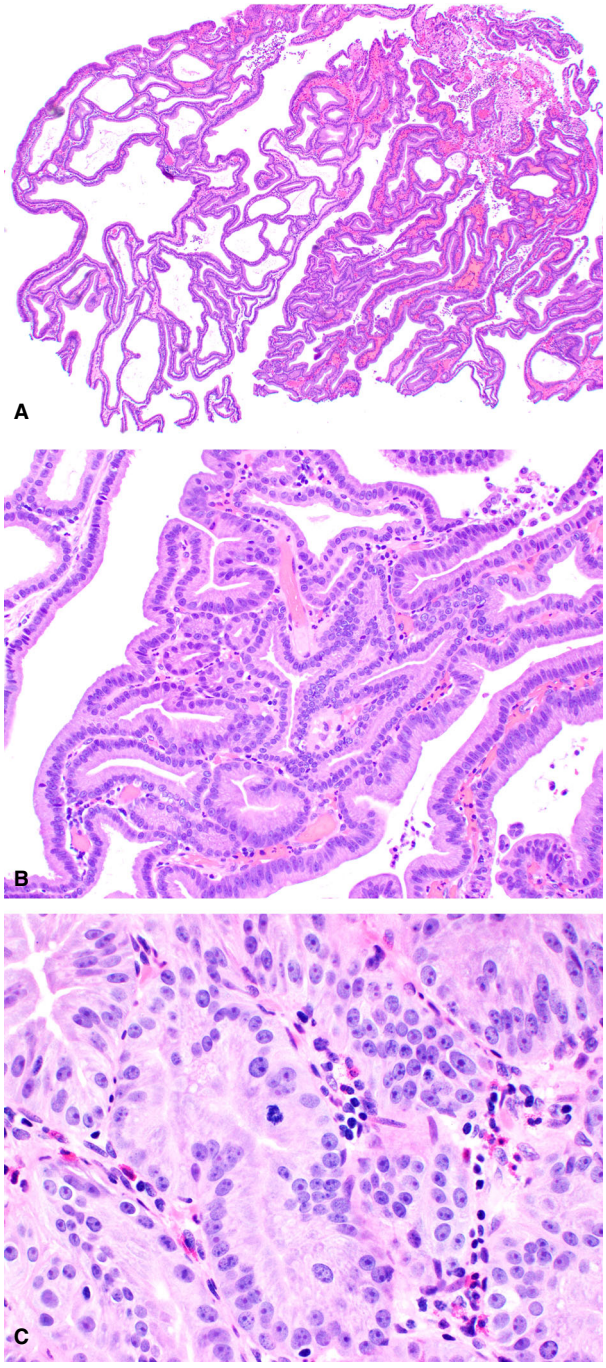

Figure 6. Pyloric gland adenoma. A and B, Typical low- and medium-power view of a low-grade tubulovillous pyloric gland adenoma (PGA). C, High-power view of another example of PGA with high-grade nuclear features.

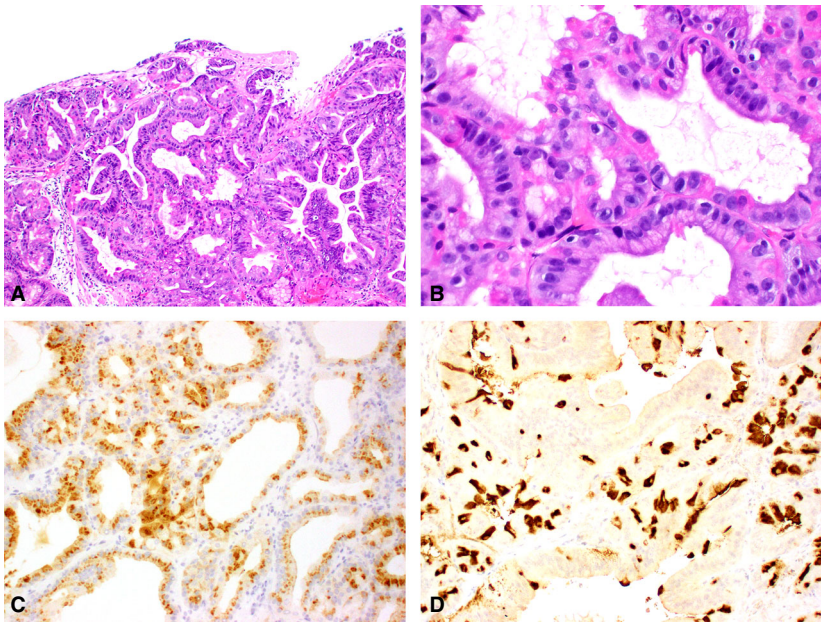

Figure 7. Oxyntic gland adenoma. This composite illustrates the morphological features (A,B), whereas (C) and (D), respectively, show pepsinogen-I immunoreactivity of chief cells (C) and H+/K+-ATPase immunostaining of parietal cells.

and MUC6 positivity limited to the basal portion of the glands).[49]

The most prevalent molecular alterations detected are the activating mutation of *GNAS* (63–83%) and *KRAS* (41–67%);[33,52] p53 overexpression and nuclear β-catenin expression can also be observed.[33,56] FAP-associated and sporadic PGAs have generally similar genetic alterations, although the frequency of *APC* mutations is higher in FAP-associated cases (100 versus 44%).[52] Deficient MMR protein expression can be detected in PGAs of patients with Lynch syndrome but not in sporadic cases (Table 1).[50] No specific guidelines have been proposed regarding the management of PGAs. However, we suggest following the general guidelines established for the treatment of typical gastric adenomas.

Oxyntic gland adenoma

Oxyntic gland adenoma has only recently been recognised. Characteristically, OGA differentiates towards chief cells, parietal cells and mucus neck cells, thereby recapitulating the normal cellular components of oxyntic glands. Given the clinical conundrum of their behaviour, alternative terms for oxyntic gland neoplasm have been proposed to denote the whole spectrum of tumours with oxyntic gland differentiation, including gastric adenocarcinomas of fundic gland type.[34] The mean age of patients with OGA is 66 years, with a male predominance (male to female ratio = 3:1). Endoscopically, most OGA lesions are identified in the gastric body and fundus. They are usually elevated, with a reported size ranging from 3 to 40 mm.[34]

Microscopically, OGAs can display a chief cell-predominant pattern, an admixture of chief and parietal cells resembling normal fundic glands, and a predominant mucous neck cell and foveolar differentiation pattern.[34,57,58] The latter subtype is usually observed in larger lesions, which could represent a more aggressive variant.[34] Architecturally, OGAs are composed of tightly packed tubules and trabeculae. Nuclear atypia is usually mild to moderate (Figure 7A,B). Mitotic figures are rare. In contrast, high-grade OGAs are characterised by complex anastomosing glands and more pronounced cytonuclear atypia (Table 1). Careful assessment of the submucosa is essential, because herniation through the muscularis mucosae is relatively common and should not be construed as evidence of invasion. Based on the favourable outcome of oxyntic gland neoplasms with such submucosal involvement, Singhi *et al.* suggested that this finding might represent prolapse-type epithelial misplacement, and they proposed to reclassify gastric adenocarcinomas of fundic gland type as OGAs.[59] Nevertheless, studies with Japanese cohorts have shown cases of oxyntic gland neoplasms with massive submucosal extension, lymphovascular invasion and lymph node metastasis as well as possible predictive factors of malignant behaviour, such as the degree of nuclear atypia and mucus neck cell differentiation (Table 2).[34] Although the diagnosis of OGA should primarily rely upon the result of H&E stains, the chief

cell and parietal cell components can be highlighted with pepsinogen-I and H+/K+-ATPase immunostaining, respectively (Figure 7C,D). Similar to PGAs, MUC6 can be diffusely expressed (Table 1),[60] and the Ki-67 labelling index is usually low. To date, studies are limited; however, in 50% of lesions observed in these reports, mutations of various genes involved in the Wnt/β-catenin signalling pathway, such as *CTNNB1*, *AXINs*, *APC* or *GNAS*, have been detected.[61,62] No specific guidelines have been established for the management of OGA. However, size, degree of atypia and invasion should be the guiding principles for advising endoscopic therapy.

Duodenal polyps

Duodenal polyps are commonly defined on the basis of their location – either in the duodenal bulb, ampullary/peri-ampullary region or distal duodenum. Some lesions are almost exclusively diagnosed in the ampullary/peri-ampullary region (e.g. tumours of pancreatobiliary differentiation, gangliocytic paragangliomas and somatostatin-expressing neuroendocrine tumours) and form a distinct group. However, these lesions are not discussed in this review.

Most duodenal polyps are non-neoplastic. Instead, they represent regenerative/hyperplastic nodules of foveolar epithelium or Brunner gland proliferations (38%). Other less common polyps include heterotopic (6%) and neoplastic lesions (11%).[63] Adenomas of intestinal-type are the most common (89%), followed by adenomatous lesions that present a gastric phenotype: PGAs (8%) and foveolar-type adenomas (3%).[64]

Non-neoplastic polyps

Non-neoplastic duodenal polyps, most of which represent regenerative inflammatory (pseudo) polyps, are predominantly localised in the bulb (80%).[63] The majority are associated with duodenitis, especially in the setting of peptic injury, and are less commonly associated with inflammatory bowel disease or rare conditions such as primary immunodeficiencies.[65] Histologically, non-neoplastic duodenal polyps may resemble gastric hyperplastic polyps and frequently show metaplastic foveolar epithelium with active inflammation and/or erosion, reactive epithelial changes, seamless transition with the surrounding epithelium and surface maturation (Figure 8A,B). They may also simply be composed of granulation tissue. It is worth underscoring that some of these polyps are neoplastic. Some hyperplastic polyps harbour KRAS and BRAF mutations and tend to show serrated features, similar to their microvesicular colonic counterparts.[66] The same authors did not rule

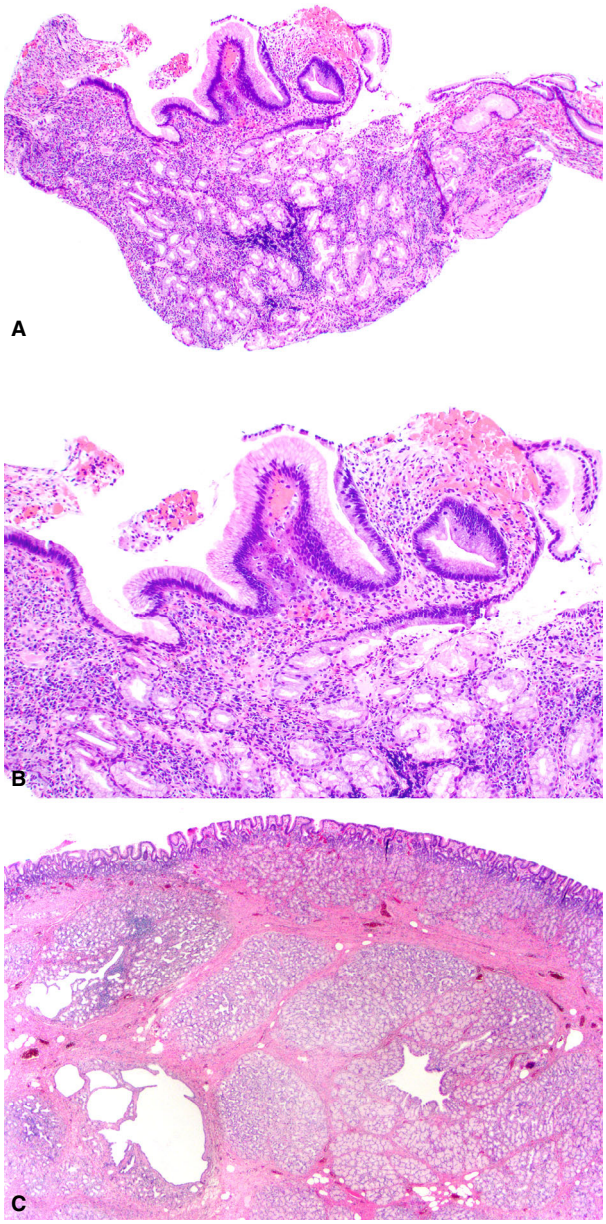

Figure 8. Non-neoplastic duodenal polyps. Polypoid exuberant regenerative foveolar hyperplasia (A). The absence of unequivocally neoplastic atypia, the active inflammation and/or erosion, reactive epithelial changes with a seamless transition to the surrounding epithelium and surface maturation differentiate this lesion from a foveolar adenoma (B). Brunner's gland proliferative lesions (C*) should be differentiated from pyloric gland adenomas (PGAs). A distinctive feature is the retained lobular architecture, highlighted by the presence of fibrous and smooth muscle septae (*courtesy of Dr A. Srivastava, Brigham and Women's Hospital, Boston, MA, USA).

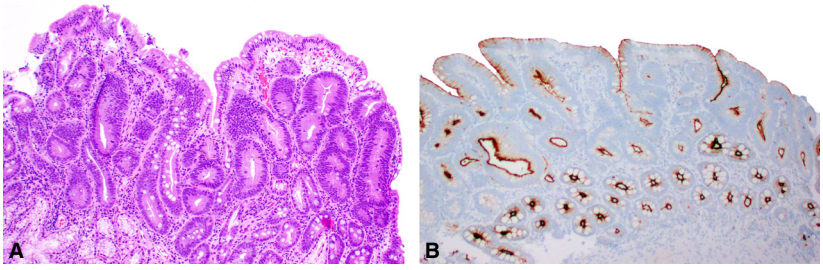

Figure 9. Duodenal intestinal adenoma. This adenoma is similar to conventional colonic adenomas (A), with CD10 immunostaining highlighting the brush border (B).

out that duodenal hyperplastic polyps with KRAS mutation may represent precursor lesions of duodenal traditional serrated adenomas.[66] Polypoid heterotopic gastric mucosa is another frequent type of duodenal polyps. As opposed to the peptic injury-induced foveolar metaplasia, lesions of this type also contain clusters of oxyntic glands under the surface of the foveolar epithelium. Duodenal gastric heterotopia has been shown to be associated with FGPs and PPI therapy, but to have an inverse association with *H. pylori* infection. It has been postulated that microscopic heterotopic oxyntic mucosal islands become polypoid in response to PPI therapy-induced hyperplasia/hypertrophy.[67] A further similarity with gastric FGPs is the detection of somatic *CTNNB1* (β-catenin) gene mutations, which implies the possibility of a neoplastic condition. Conversely, such molecular alterations are absent in peptic injury-related foveolar metaplasia.[68] Deeply located Brunner glands may also show various degrees of regenerative proliferation and reactive atypia and form Brunner gland hyperplasia/hamartoma.[69] This diagnostic category is not well defined, and the use of 'Brunner gland proliferative lesions' as a generic term has been encouraged.[70] Notably, gastric heterotopia and Brunner gland proliferative lesions have both been advanced as possible precursor lesions of duodenal PGAs.[51] The presence of fibrous and smooth muscle septae and intermingled adipose tissue, which highlights the retained lobular architecture, can help to distinguish Brunner gland proliferative lesions from PGAs (Figure 8C).[71]

Surface epithelium-derived adenomas (foveolar and intestinal adenomas)

The duodenum (particularly the second portion) is predisposed to the development of small intestinal adenomas.[63] The mean age of patients at diagnosis is 65 years, with a slight male predilection. In contrast to gastric adenomas, which are predominantly non-syndromic in nature, a relatively high proportion (approximately 60%) of non-ampullary duodenal adenomas are associated with FAP or MAP (Table 3). Non-syndromic non-ampullary adenomas are found in only 0.3–0.5% of gastroduodenoscopies. Most duodenal adenomas present endoscopically as sessile rather than pedunculated lesions.[72]

Histologically, most adenomas are of intestinal type, but foveolar-type adenomas can also develop (Table 1). Intestinal adenomas are essentially identical to colonic adenomas, with predominantly tubular but sometimes tubulovillous or villous architecture. They are formed of pseudostratified absorptive cells that are intermingled with goblet and Paneth cells (Figure 9). There are no histological features by which FAP- and MAP-related cases can be distinguished. Foveolar adenomas show tall columnar epithelium that resembles gastric foveolar cells and has a characteristic apical mucin cap (Figure 10). These adenomas usually display a tubulovillous architecture.[64,73] Based on limited data, it has been found that foveolar adenomas could have a higher tendency to harbour high-grade dysplasia.[64] These lesions uniformly express MUC5AC, with scattered MUC6-positive cells, whereas intestinal adenomas can be labelled with CDX2, CD10 and MUC2.[64,73,74] *APC* and *KRAS* alterations are frequently identified in both non-syndromic and FAP-related intestinal adenomas (Table 1). DNA MMR abnormalities, *TP53* and *BRAF* mutations are infrequent.[75] The risk of neoplastic progression appears to be related to the size and grade of dysplasia with low-grade lesions and those < 20 mm in size presenting a low risk of progression to adenocarcinoma (4.7%). Conversely, biopsy-proven high-grade lesions are frequently (approximately 55%) found to contain adenocarcinoma after endoscopic resection (Table 2).[76] Cold-snare polypectomy is recommended for the excision of small sporadic non-ampullary duodenal adenomas (< 10 mm). Due to the higher association with high-grade dysplasia or adenocarcinoma, larger (> 10 mm) lesions can be effectively removed by EMR. Endoscopic submucosal dissection is not recommended because of the relatively thin and vascular nature of the duodenal wall, which has a relatively high risk of perforation (up to 30%).[77]

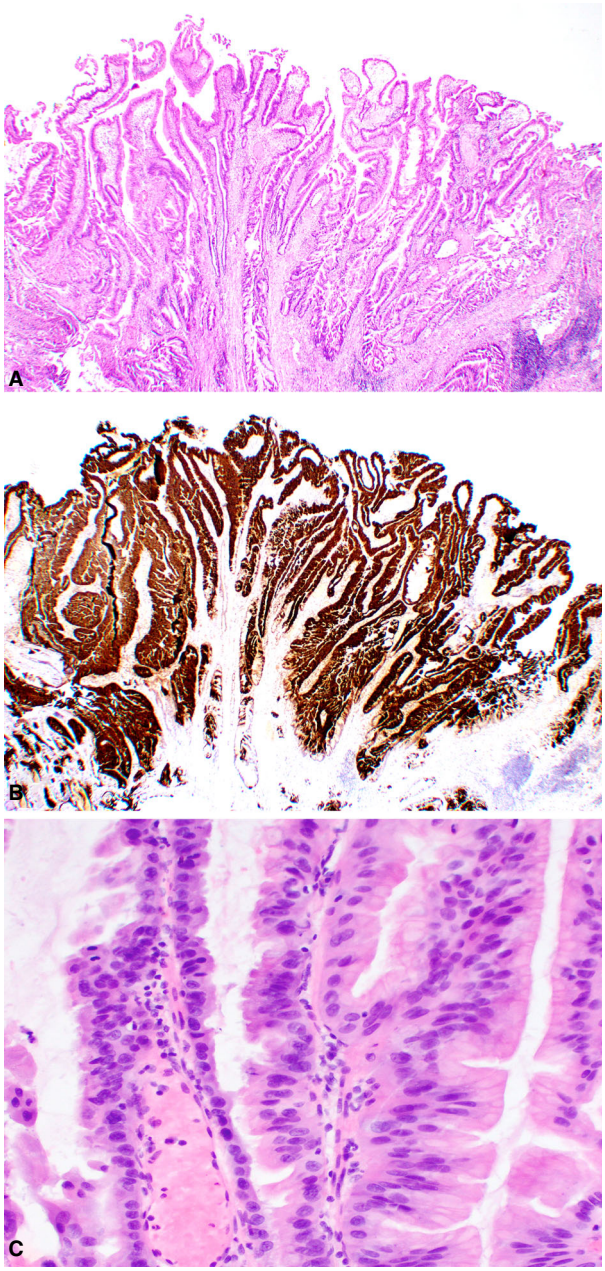

Figure 10. Duodenal foveolar adenoma. This villiform dysplastic lesion (A) is characteristically decorated by diffuse mucin core protein (MUC)5AC immunoreactivity (B) and lined by tall clear foveolar cells with distinct mucin cap (C).

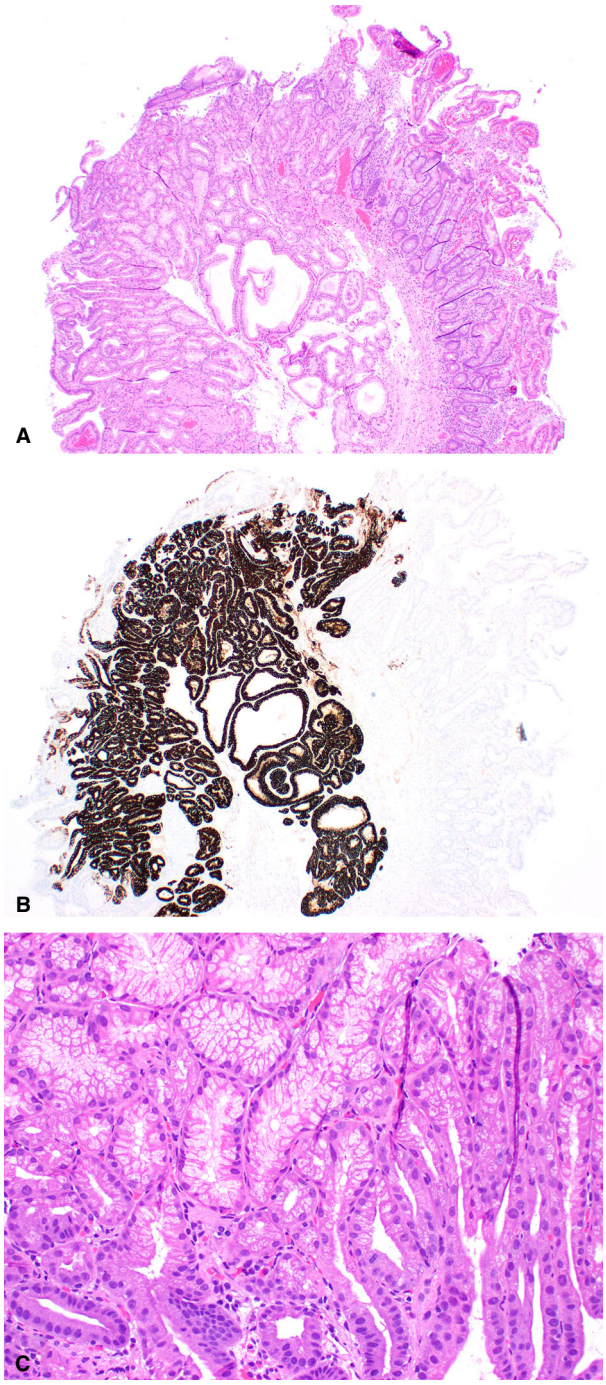

Figure 11. Duodenal pyloric gland adenoma. The polyp is composed of packed clear to eosinophilic tubular glands (A) and highlighted by mucin core protein (MUC)6 immunoreactivity (B). C, Characteristic high-magnification morphology.

Duodenal adenomas with pyloric gland phenotype

The pathogenesis of duodenal PGAs is unknown. The hypothesis that they arise either from heterotopic gastric mucosa or regenerative Brunner glands is the most convincing to date.[51] The diagnostic category of Brunner gland adenoma remains controversial and is not well described. In fact, most published cases of Brunner gland adenoma probably represent examples

of PGAs. In the opinion of many authors, to be consistent with the gastric nomenclature it is preferable to use the term 'PGA' rather than 'Brunner gland adenoma'.[70]

Duodenal PGAs are morphologically similar to gastric PGAs. Most are endoscopically polypoid, but flat lesions have been reported.[12,51] They are commonly located in the proximal duodenum. Microscopically, they are composed of tightly packed tubules that are lined by a monolayer of cuboidal cells and have granular-eosinophilic to ground-glass cytoplasm and lack an apical mucin cap (Figure 11, Table 1).[12,51] High-grade lesions contain complex or cribriform glands, with an increased nucleus:cytoplasm ratio, prominent nucleoli, pleomorphism and loss of cell polarity.[51] PGAs show diffuse and strong MUC6 and MUC5AC labelling, in contrast to the negative MUC6 staining in foveolar lesions.[64,74,78]

Reactive Brunner gland proliferative lesions (e.g. Brunner gland hamartoma/hyperplasia) can be differentiated from PGAs primarily by their retained lobular architecture. Although low-grade PGAs also show relatively uniform cytology, Brunner gland proliferative lesions lack the at least minimally enlarged nuclei of PGAs with their open chromatin and small nucleoli.[71]

Like their gastric counterparts, duodenal PGAs frequently harbour mutations in *GNAS* and *KRAS*,[33,78] which were also recently detected in duodenal gastric heterotopia (Table 1).[79] Interestingly, in contrast to gastric PGAs, the duodenal equivalents are uncommonly detected in a syndromic setting (e.g. in FAP, JPS or Lynch syndrome).[32,50,52–54,78] Because of the rarity of these lesions and the lack of large-scale series with regard to their natural history and prognosis, no therapeutic recommendations have been published. Alarming rates of progression to invasive carcinoma (10.5–66%) have been reported in a few small series,[12,51,64] and the likelihood of identifying either high-grade dysplasia or invasion increases with size (Table 2).[73] Recently, a low rate of recurrence has been reported after endoscopic removal.[80]

Upper GI polyps associated with tumour predisposition syndromes

Upper GI polyps can develop in association with several tumour predisposition syndromes and display morphological features similar to those of their non-syndromic counterparts (Table 3).[81] However, some GI polyps may present specific dysplastic and phenotypical characteristics. Furthermore, syndromic patients have different risks of progression, which determine specific surveillance protocols (Table 3).[82,83] Tumour predisposition syndromes usually involve both the stomach and the duodenum and may also have colonic and/or oesophageal manifestations. In some cases, the gastroduodenal manifestations are less dramatic and clinically less aggressive than extragastroduodenal ones (e.g. colonic manifestations of FAP); therefore, the recognition and diagnosis of these conditions can be challenging using upper GI biopsies alone. Nevertheless, attempting to establish the correct diagnosis is important because hidden synchronous or metachronous lesions can be identified, allowing for the adequate treatment of these patients. Finally, it is important to bear in mind that some familial gastric cancer syndromes (e.g. hereditary diffuse gastric cancer and Lynch syndrome) are not associated with polyps. These syndromes are beyond the scope of the present review.

Acknowledgements

Editorial assistance was provided by the Moffitt Cancer Center's Scientific Editing Department by Dr Paul Fletcher & Daley Drucker. No compensation was given beyond their regular salaries. University of Szeged Open Access Fund, Grant number: 5029.

Conflicts of interest

The authors have no conflicts of interest to declare.

Data availability statement

Data sharing not applicable to this article as no datasets were generated or analysed during the current study.

References

1. Carmack SW, Genta RM, Schuler CM, Saboorian MH. The current spectrum of gastric polyps: a 1-year national study of over 120,000 patients. *Am. J. Gastroenterol.* 2009; **104**; 1524–1532.
2. Jepsen JM, Persson M, Jakobsen NO *et al.* Prospective study of prevalence and endoscopic and histopathologic characteristics of duodenal polyps in patients submitted to upper endoscopy. *Scand. J. Gastroenterol.* 1994; **29**; 483–487.
3. Banks M, Graham D, Jansen M *et al.* British Society of Gastroenterology guidelines on the diagnosis and management of patients at risk of gastric adenocarcinoma. *Gut* 2019; **68**; 1545–1575.
4. Stolte M, Sticht T, Eidt S, Ebert D, Finkenzeller G. Frequency, location, and age and sex distribution of various types of gastric polyp. *Endoscopy* 1994; **26**; 659–665.
5. Sonnenberg A, Genta RM. Prevalence of benign gastric polyps in a large pathology database. *Dig. Liver Dis.* 2015; **47**; 164–169.
6. Hassan TMM, Al-Najjar SI, Al-Zahrani IH, Alanazi FIB, Alotibi MG. Helicobacter pylori chronic gastritis updated Sydney

grading in relation to endoscopic findings and *H. pylori* IgG antibody: diagnostic methods. *J. Microsc. Ultrastruct.* 2016; **4**; 167–174.
7. Cao H, Wang B, Zhang Z, Zhang H, Qu R. Distribution trends of gastric polyps: an endoscopy database analysis of 24 121 northern Chinese patients. *J. Gastroenterol. Hepatol.* 2012; **27**; 1175–1180.
8. Laxén F, Sipponen P, Ihamäki T, Hakkiluoto A, Dortscheva Z. Gastric polyps; their morphological and endoscopical characteristics and relation to gastric carcinoma. *Acta Pathol. Microbiol. Immunol. Scand. A.* 1982; **90**; 221–228.
9. Papa A, Cammarota G, Tursi A *et al*. Histologic types and surveillance of gastric polyps: a seven year clinico-pathological study. *Hepatogastroenterology* 1998; **45**; 579–582.
10. Archimandritis A, Spiliadis C, Tzivras M *et al*. Gastric epithelial polyps: a retrospective endoscopic study of 12974 symptomatic patients. *Ital. J. Gastroenterol.* 1996; **28**; 387–390.
11. Abraham SC, Montgomery EA, Singh VK, Yardley JH, Wu TT. Gastric adenomas: intestinal-type and gastric-type adenomas differ in the risk of adenocarcinoma and presence of background mucosal pathology. *Am. J. Surg. Pathol.* 2002; **26**; 1276–1285.
12. Vieth M, Kushima R, Borchard F, Stolte M. Pyloric gland adenoma: a clinico-pathological analysis of 90 cases. *Virchows Arch.* 2003; **442**; 317–321.
13. Dirschmid K, Platz-Baudin C, Stolte M. Why is the hyperplastic polyp a marker for the precancerous condition of the gastric mucosa? *Virchows Arch.* 2006; **448**; 80–84.
14. Gonzalez-Obeso E, Fujita H, Deshpande V *et al*. Gastric hyperplastic polyps: a heterogeneous clinicopathologic group including a distinct subset best categorized as mucosal prolapse polyp. *Am. J. Surg. Pathol.* 2011; **35**; 670–677.
15. Ji F, Wang ZW, Ning JW, Wang QY, Chen JY, Li YM. Effect of drug treatment on hyperplastic gastric polyps infected with *Helicobacter pylori*: a randomized, controlled trial. *World J. Gastroenterol.* 2006; **12**; 1770–1773.
16. Hattori T. Morphological range of hyperplastic polyps and carcinomas arising in hyperplastic polyps of the stomach. *J. Clin. Pathol.* 1985; **38**; 622–630.
17. Forté E, Petit B, Walter T *et al*. Risk of neoplastic change in large gastric hyperplastic polyps and recurrence after endoscopic resection. *Endoscopy* 2020; **52**; 444–453.
18. Imura J, Hayashi S, Ichikawa K *et al*. Malignant transformation of hyperplastic gastric polyps: an immunohistochemical and pathological study of the changes of neoplastic phenotype. *Oncol. Lett.* 2014; **7**; 1459–1463.
19. Antonioli DA. Precursors of gastric carcinoma: a critical review with a brief description of early (curable) gastric cancer. *Hum. Pathol.* 1994; **25**; 994–1005.
20. Takayama Y, Ono Y, Mizukami Y *et al*. Comparative genome-wide analysis of gastric adenocarcinomas with hyperplastic polyp components. *Virchows Arch.* 2019; **475**; 383–389.
21. Salomao M, Luna AM, Sepulveda JL, Sepulveda AR. Mutational analysis by next generation sequencing of gastric type dysplasia occurring in hyperplastic polyps of the stomach: mutations in gastric hyperplastic polyps. *Exp. Mol. Pathol.* 2015; **99**; 468–473.
22. Saab J, Estrella JS, Chen YT *et al*. Immunohistochemical and molecular features of gastric hyperplastic polyps. *Adv. Cytol. Pathol.* 2017; **2**; 25–31.
23. Lauwers GY, Wahl SJ, Melamed J, Rojas-Corona RR. p53 expression in precancerous gastric lesions: an immunohistochemical study of PAb1801 monoclonal antibody on adenomatous and hyperplastic gastric polyps. *Am. J. Gastroenterol.* 1993; **88**; 1916–1919.
24. Rich A, Toro TZ, Tanksley J *et al*. Distinguishing Ménétrier's disease from its mimics. *Gut* 2010; **59**; 1617–1624.
25. Park DY, Srivastava A, Kim GH *et al*. Adenomatous and foveolar gastric dysplasia: distinct patterns of mucin expression and background intestinal metaplasia. *Am. J. Surg. Pathol.* 2008; **32**; 524–533.
26. Shibagaki K, Fukuyama C, Mikami H *et al*. Gastric foveolar-type adenomas endoscopically showing a raspberry-like appearance in the *Helicobacter pylori* -uninfected stomach. *Endosc. Int. Open* 2019; **7**; E784–E791.
27. Fleisher AS, Esteller M, Tamura G *et al*. Hypermethylation of the hMLH1 gene promoter is associated with microsatellite instability in early human gastric neoplasia. *Oncogene* 2001; **20**; 329–335.
28. Abraham SC, Park SJ, Lee JH, Mugartegui L, Wu TT. Genetic alterations in gastric adenomas of intestinal and foveolar phenotypes. *Mod. Pathol.* 2003; **16**; 786–795.
29. Rokutan H, Abe H, Nakamura H *et al*. Initial and crucial genetic events in intestinal-type gastric intramucosal neoplasia. *J. Pathol.* 2019; **247**; 494–504.
30. Lee JH, Abraham SC, Kim HS *et al*. Inverse relationship between APC gene mutation in gastric adenomas and development of adenocarcinoma. *Am. J. Pathol.* 2002; **161**; 611–618.
31. Valente P, Garrido M, Gullo I *et al*. Epithelial dysplasia of the stomach with gastric immunophenotype shows features of biological aggressiveness. *Gastric Cancer* 2015; **18**; 720–728.
32. Hackeng WM, Montgomery EA, Giardiello FM *et al*. Morphology and genetics of pyloric gland adenomas in familial adenomatous polyposis. *Histopathology* 2017; **70**; 549–557.
33. Matsubara A, Sekine S, Kushima R *et al*. Frequent GNAS and KRAS mutations in pyloric gland adenoma of the stomach and duodenum. *J. Pathol.* 2013; **229**; 579–587.
34. Ushiku T, Kunita A, Kuroda R *et al*. Oxyntic gland neoplasm of the stomach: expanding the spectrum and proposal of terminology. *Mod. Pathol.* 2020; **33**; 206–216.
35. Abraham SC, Nobukawa B, Giardiello FM, Hamilton SR, Wu TT. Fundic gland polyps in familial adenomatous polyposis: neoplasms with frequent somatic adenomatous polyposis coli gene alterations. *Am. J. Pathol.* 2000; **157**; 747–754.
36. de Boer WB, Ee H, Kumarasinghe MP. Neoplastic lesions of gastric adenocarcinoma and proximal polyposis syndrome (GAPPS) are gastric phenotype. *Am. J. Surg. Pathol.* 2018; **42**; 1–8.
37. Vogt S, Jones N, Christian D *et al*. Expanded extracolonic tumor spectrum in MUTYH-associated polyposis. *Gastroenterology* 2009; **137**; 1976–1985.e1–10.
38. Fukuda M, Ishigaki H, Sugimoto M *et al*. Histological analysis of fundic gland polyps secondary to PPI therapy. *Histopathology* 2019; **75**; 537–545.
39. Naili RE, Pereira D, Kushima R *et al*. Multicenter retrospective evaluation of fundic gland polyps of various etiologies. *Mod. Pathol.* 2019; **32**(Suppl. 2); 624.
40. Wu TT, Kornacki S, Rashid A, Yardley JH, Hamilton SR. Dysplasia and dysregulation of proliferation in foveolar and surface epithelia of fundic gland polyps from patients with familial adenomatous polyposis. *Am. J. Surg. Pathol.* 1998; **22**; 293–298.
41. Arnason T, Liang WY, Alfaro E *et al*. Morphology and natural history of familial adenomatous polyposis-associated dysplastic fundic gland polyps. *Histopathology* 2014; **65**; 353–362.
42. Abraham SC, Nobukawa B, Giardiello FM, Hamilton SR, Wu TT. Sporadic fundic gland polyps: common gastric polyps

arising through activating mutations in the beta-catenin gene. *Am. J. Pathol.* 2001; **158**; 1005–1010.
43. Pezhouh MK, Park JY. Gastric pyloric gland adenoma. *Arch. Pathol. Lab. Med.* 2015; **139**; 823–826.
44. Vieth M, Montgomery EA. Some observations on pyloric gland adenoma: an uncommon and long ignored entity!. *J. Clin. Pathol.* 2014; **67**; 883–890.
45. Kushima R, Vieth M, Mukaisho K *et al.* Pyloric gland adenoma arising in Barrett's esophagus with mucin immunohistochemical and molecular cytogenetic evaluation. *Virchows Arch.* 2005; **446**; 537–541.
46. Kushima R, Rüthlein HJ, Stolte M, Bamba M, Hattori T, Borchard F. 'Pyloric gland-type adenoma' arising in heterotopic gastric mucosa of the duodenum, with dysplastic progression of the gastric type. *Virchows Arch.* 1999; **435**; 452–457.
47. Mannan AASR, Vieth M, Khararjian A *et al.* The outlet patch: gastric heterotopia of the colorectum and anus. *Histopathology* 2018; **73**; 220–229.
48. Kushima R, Remmele W, Stolte M, Borchard F. Pyloric gland type adenoma of the gallbladder with squamoid spindle cell metaplasia. *Pathol. Res. Pract.* 1996; **192**; 963–971.
49. Choi WT, Brown I, Ushiku T *et al.* Gastric pyloric gland adenoma: a multicentre clinicopathological study of 67 cases. *Histopathology* 2018; **72**; 1007–1014.
50. Lee SE, Kang SY, Cho J *et al.* Pyloric gland adenoma in Lynch syndrome. *Am. J. Surg. Pathol.* 2014; **38**; 784–792.
51. Chen ZM, Scudiere JR, Abraham SC, Montgomery E. Pyloric gland adenoma: an entity distinct from gastric foveolar type adenoma. *Am. J. Surg. Pathol.* 2009; **33**; 186–193.
52. Hashimoto T, Ogawa R, Matsubara A *et al.* Familial adenomatous polyposis-associated and sporadic pyloric gland adenomas of the upper gastrointestinal tract share common genetic features. *Histopathology* 2015; **67**; 689–698.
53. Wood LD, Salaria SN, Cruise MW, Giardiello FM, Montgomery EA. Upper GI tract lesions in familial adenomatous polyposis (FAP): enrichment of pyloric gland adenomas and other gastric and duodenal neoplasms. *Am. J. Surg. Pathol.* 2014; **38**; 389–393.
54. Ma C, Giardiello FM, Montgomery EA. Upper tract juvenile polyps in juvenile polyposis patients: dysplasia and malignancy are associated with foveolar, intestinal, and pyloric differentiation. *Am. J. Surg. Pathol.* 2014; **38**; 1618–1626.
55. Kushima R, Vieth M, Borchard F, Stolte M, Mukaisho K, Hattori T. Gastric-type well-differentiated adenocarcinoma and pyloric gland adenoma of the stomach. *Gastric Cancer* 2006; **9**; 177–184.
56. Kushima R, Müller W, Stolte M, Borchard F. Differential p53 protein expression in stomach adenomas of gastric and intestinal phenotypes: possible sequences of p53 alteration in stomach carcinogenesis. *Virchows Arch.* 1996; **428**; 223–227.
57. Takahashi K, Fujiya M, Ichihara S, Moriichi K, Okumura T. Inverted gastric adenocarcinoma of fundic gland mucosa type colliding with well differentiated adenocarcinoma: a case report. *Medicine* 2017; **96**; e7080.
58. Uchida A, Ozawa M, Ueda Y *et al.* Gastric adenocarcinoma of fundic gland mucosa type localized in the submucosa: a case report. *Medicine* 2018; **97**; e12341.
59. Singhi AD, Lazenby AJ, Montgomery EA. Gastric adenocarcinoma with chief cell differentiation: a proposal for reclassification as oxyntic gland polyp/adenoma. *Am. J. Surg. Pathol.* 2012; **36**; 1030–1035.
60. Ueyama H, Matsumoto K, Nagahara A, Hayashi T, Yao T, Watanabe S. Gastric adenocarcinoma of the fundic gland type (chief cell predominant type). *Endoscopy* 2014; **46**; 153–157.
61. Hidaka Y, Mitomi H, Saito T *et al.* Alteration in the Wnt/β-catenin signaling pathway in gastric neoplasias of fundic gland (chief cell predominant) type. *Hum Pathol.* 2013; **44**; 2438–2448.
62. Nomura R, Saito T, Mitomi H *et al.* GNAS mutation as an alternative mechanism of activation of the Wnt/β-catenin signaling pathway in gastric adenocarcinoma of the fundic gland type. *Hum. Pathol.* 2014; **45**; 2488–2496.
63. Jung SH, Chung WC, Kim EJ *et al.* Evaluation of non-ampullary duodenal polyps: comparison of non-neoplastic and neoplastic lesions. *World J. Gastroenterol.* 2010; **16**; 5474–5480.
64. Mitsuishi T, Hamatani S, Hirooka S *et al.* Clinicopathological characteristics of duodenal epithelial neoplasms: focus on tumors with a gastric mucin phenotype (pyloric gland-type tumors). *PLoS ONE* 2017; **12**; 0174985.
65. Remmele W, Hartmann W, von der Laden U *et al.* Three other types of duodenal polyps: mucosal cysts, focal foveolar hyperplasia, and hyperplastic polyp originating from islands of gastric mucosa. *Dig. Dis. Sci.* 1989; **34**; 1468–1472.
66. Rosty C, Buchanan DD, Walters RJ *et al.* Hyperplastic polyp of the duodenum: a report of 9 cases with immunohistochemical and molecular findings. *Hum. Pathol.* 2011; **42**; 1953–1959.
67. Conlon N, Logan E, Veerappan S, McKiernan S, O'Briain S. Duodenal gastric heterotopia: further evidence of an association with fundic gland polyps. *Hum. Pathol.* 2013; **44**; 636–642.
68. Nakagawa M, Kitazawa R, Kondo T *et al.* Duodenal gastric heterotopia, sporadic or fundic gland polyp-associated, frequently carries β-catenin mutation. *Virchows Arch.* 2014; **465**; 253–256.
69. Terada T. Pathologic observations of the duodenum in 615 consecutive duodenal specimens: I. Benign lesions. *Int. J. Clin. Exp. Pathol.* 2012; **5**; 46–51.
70. Odze RD, Goldblum JR. *Surgical pathology of the GI tract, liver, biliary tract, and pancreas*. 3rd ed. Philadelphia, PA: Saunders, 2014; 582.
71. Kim K, Jang SJ, Song HJ, Yu E. Clinicopathologic characteristics and mucin expression in Brunner's gland proliferating lesions. *Dig. Dis. Sci.* 2013; **58**; 194–201.
72. Lim CH, Cho YS. Nonampullary duodenal adenoma: Current understanding of its diagnosis, pathogenesis, and clinical management. *World J. Gastroenterol.* 2016; **22**; 853–861.
73. Hijikata K, Nemoto T, Igarashi Y, Shibuya K. Extra-ampullary duodenal adenoma: a clinicopathological study. *Histopathology* 2017; **71**; 200–207.
74. Fujisawa T, Horimatsu T, Sakaguchi K *et al.* Duodenal adenoma of gastric foveolar phenotype in the second portion of the duodenum. *Dig. Endosc.* 2006; **18**; 62–66.
75. Wagner PL, Chen YT, Yantiss RK. Immunohistochemical and molecular features of sporadic and FAP-associated duodenal adenomas of the ampullary and nonampullary mucosa. *Am. J. Surg. Pathol.* 2008; **32**; 1388–1395.
76. Okada K, Fujisaki J, Kasuga A *et al.* Sporadic nonampullary duodenal adenoma in the natural history of duodenal cancer: a study of follow-up surveillance. *Am. J. Gastroenterol.* 2011; **106**; 357–364.
77. Ma MX, Bourke MJ. Management of duodenal polyps. *Best Pract. Res. Clin. Gastroenterol.* 2017; **31**; 389–399.
78. Hida R, Yamamoto H, Hirahashi M *et al.* Duodenal neoplasms of gastric phenotype: an immunohistochemical and genetic study with a practical approach to the classification. *Am. J. Surg. Pathol.* 2017; **41**; 343–353.
79. Matsubara A, Ogawa R, Suzuki H *et al.* Activating GNAS and KRAS mutations in gastric foveolar metaplasia, gastric

heterotopia, and adenocarcinoma of the duodenum. *Br J. Cancer* 2015; **112**; 1398–1404.
80. Miller GC, Kumarasinghe MP, Borowsky J *et al*. Clinicopathological features of pyloric gland adenomas of the duodenum: a multicentre study of 57 cases. *Histopathology* 2020; **76**; 404–410.
81. Setia N, Clark JW, Duda DG *et al*. Familial gastric cancers. *Oncologist* 2015; **20**; 1365–1377.
82. van Leerdam ME, Roos VH, van Hooft JE *et al*. Endoscopic management of polyposis syndromes: European Society of Gastrointestinal Endoscopy (ESGE) Guideline. *Endoscopy* 2019; **51**; 877–895.
83. Samadder NJ, Baffy N, Giridhar KV, Couch FJ, Riegert-Johnson D. Hereditary cancer syndromes – a primer on diagnosis and management, part 2. Gastrointestinal cancer syndromes. *Mayo Clin. Proc.* 2019; **94**; 1099–1116.