

## Juvenile pemphigus foliaceus

M.MEHRAVARAN, M.MORVAY, K.MOLNÁR, J.OLÁH, I.KOROM, S.HUSZ AND A.DOBOZY

Department of Dermatology, Albert Szent-Györgyi Medical University, H-6701 Szeged, Korányi fasor 6, PO Box 480, Szeged, Hungary

Accepted for publication 7 April 1998

### Summary

A 7-year-old girl with generalized erythematous, scaling plaques and vesiculobullous lesions on the extremities was diagnosed as having pemphigus foliaceus. Lesional direct immunofluorescence revealed intercellular IgG, IgA and C3 deposition. The patient's serum gave positive reactions against one epitope of desmoglein 3 and the epitope of desmoglein 1 in enzyme-linked immunosorbent assays, but the blood sample for indirect immunofluorescence did not display any circulating antibodies. The patient was successfully treated systemically with prednisolone and dapsone. Currently, she is taking dapsone, 12.5 mg daily. She has been free of lesions for the last 3 years.

Pemphigus, a life-threatening autoimmune blistering disorder that involves the skin and mucous membranes, can be divided into two major subgroups: pemphigus vulgaris (PV) and pemphigus foliaceus (PF).<sup>1,2</sup> PF, a superficial variant of pemphigus, is extremely rare in children and mostly occurs in the middle-aged and elderly.<sup>3,4</sup> The clinical findings in childhood PF involve gradually spreading eczematized scaly plaques starting on the face and upper extremities, with the possible development of bullae and superficial crusts.<sup>5</sup> Early diagnosis and prompt treatment are based on the clinical, histological and immunopathological changes.

### Case report

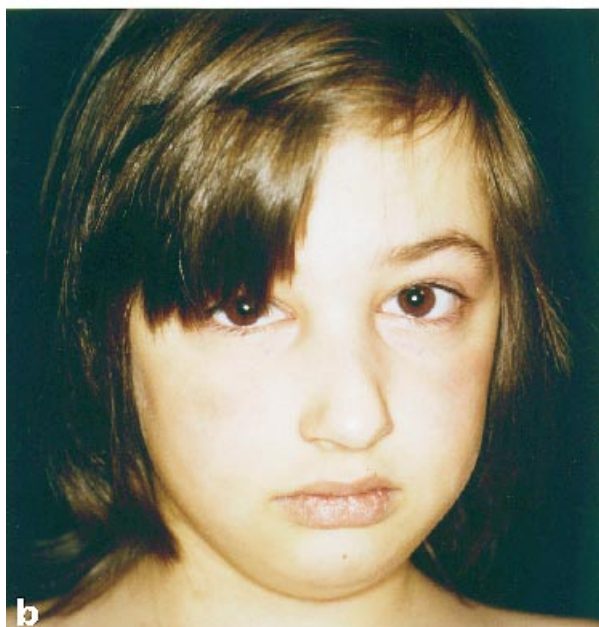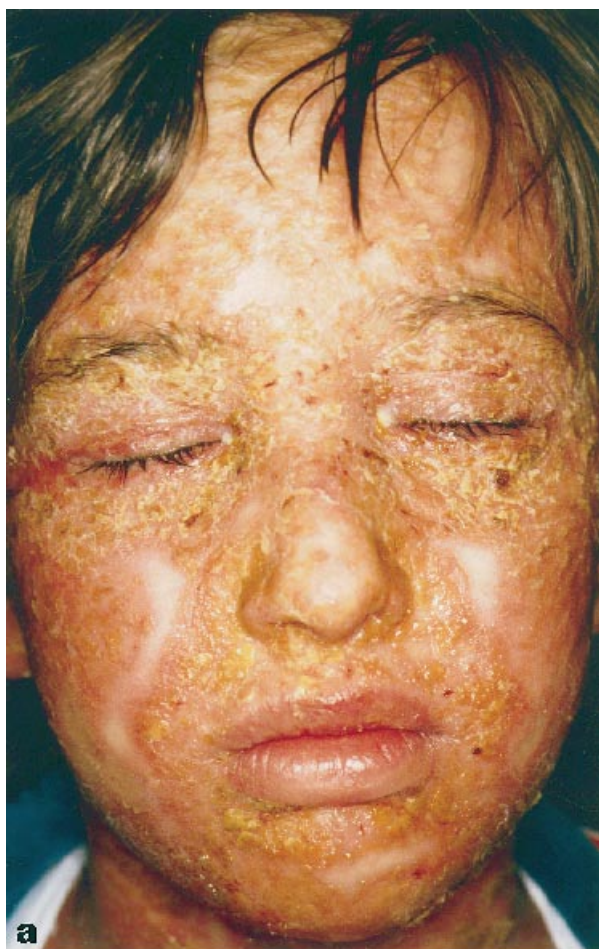A 7-year-old girl presented with a 3-month history of generalized, painful, small blisters and superinfected erosions covered with thick, yellowish crusts. For months, there had been a history of red, squamous plaques on the scalp, which were treated as psoriasis with local corticosteroids; the lesions healed slowly. The patient was weak and in a poor condition. Physical examination revealed extensive, generalized erythema, with superficial erosions covered with thick yellow crusts, mainly on the face (Fig. 1a), trunk (Fig. 2) and extremities. Scattered intact superficial blisters were present on the extremities, with a positive Nikolsky's sign. The oral mucosa was spared. Bilateral cervical and axillary lymphadenopathy was also noted.

Laboratory investigations revealed the following abnormalities: leucocytosis with a white blood cell count of  $20.7 (10^9/L)$  (normal  $4.6-10.2$ ), an aspartate aminotransferase level of  $74 U/L$  (normal  $<40 U/L$ ) and an alanine aminotransferase level of  $83 U/L$  (normal  $<40 U/L$ ). Skin and pharyngeal swabs for bacterial cultures were positive for *Staphylococcus aureus* and *Streptococcus pyogenes*.

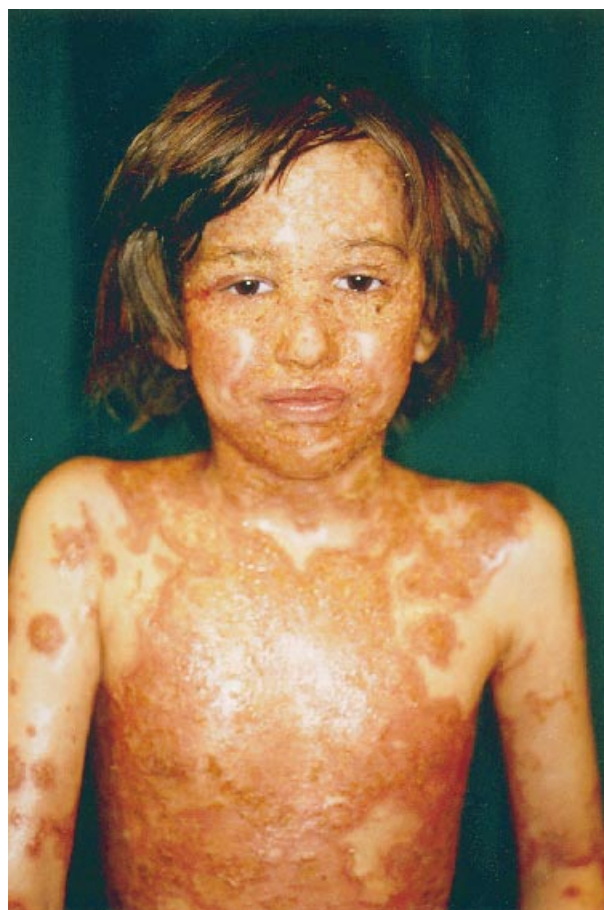A perilesional biopsy for histology demonstrated a subcorneal blister with acantholytic cells without any inflammatory cells in the cleft (Fig. 3). Direct immunofluorescence studies of frozen skin tissue showed positive intercellular staining for IgG, IgA and C3 within the epidermis. The circulating antidesmoglein 1 (anti-Dsg1) and anti-Dsg3 antibodies were examined by means of enzyme-linked immunosorbent assays (ELISAs), using synthetic, antigenic peptides. Antigenic epitopes for desmogleins 1 and 3 were chosen using PeptideStructure software. The antigenic epitope for desmoglein 1 consists of 14 amino acids. It is part of the extracellular (EII) domain located between two  $Ca^{2+}$  binding sequences. The antigenic epitope for Dsg3 consists of 13 amino acids. It is located in the extracellular (EI) domain and is part of the Bos1 sequence.<sup>6</sup>

Antigenic peptides were dissolved in phosphate-buffered saline (PBS), pH 7.4, in  $0.1 \mu g/100 \mu L$  concentration. Microplate wells were filled with  $100 \mu L$  and allowed to coat overnight at  $4^\circ C$ . Plates were washed twice with distilled water, and the remaining binding sites were blocked with 1% bovine serum albumin (BSA) in PBS for 1.5 h at  $37^\circ C$ . Plates were washed again three times with PBS-Tween (PBS containing 0.5%

Correspondence: Dr M.Mehravaran  
E-mail: ME@derma.szote.u-szeged.hu



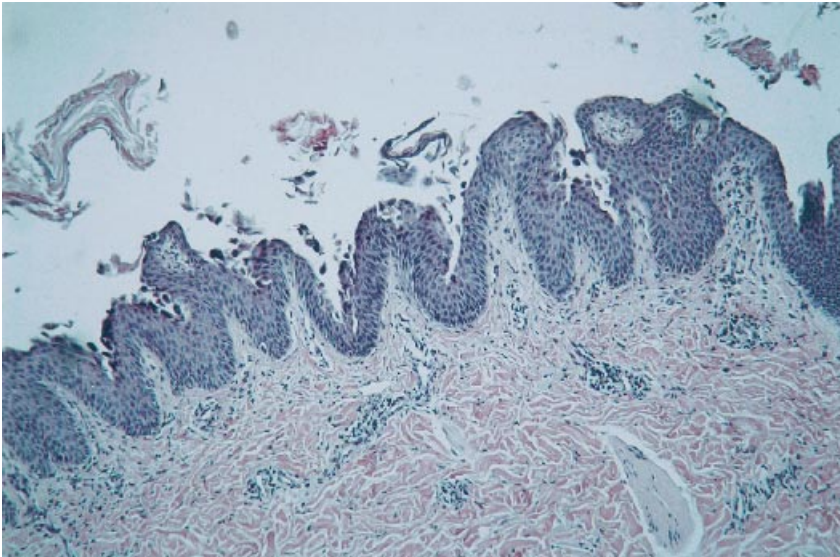
**Figure 1.** (a) Seborrhoeic-like, erythematous, scaling lesions are seen on the face. (b) Complete recovery with mild hyperpigmentation on the cheek.



**Figure 2.** Diffuse, exfoliative, crusted, eroded plaques are evident on the trunk.

Tween-20), and 100  $\mu\text{L}$  of the 200 times diluted serum samples was added per well, incubated for 1 h at 37°C and washed extensively with PBS-Tween. Aliquots of 100  $\mu\text{L}$  of peroxidase-conjugated antihuman IgG, diluted 1:5000 in PBS-Tween, were then added to each well and incubated for 1 h at 37°C. Subsequently, the plates were washed again with PBS-Tween and then 100  $\mu\text{L}$  of substrate solution [17 mg of ortho-phenylene diamine (OPD) dissolved in 50 mL of phosphate-citric acid buffer, pH 5, and 20  $\mu\text{L}$  of  $\text{H}_2\text{O}_2$ ] was added to each well and the colour allowed to develop for 10 min at room temperature in the dark. The reaction was stopped by adding 50  $\mu\text{L}$  of 4 N  $\text{H}_2\text{SO}_4$  to each well. Plates were read on an ELISA reader at 492 nm.

In ELISA investigations, serum samples were tested in triplicate, and the mean results were taken. Ten healthy control sera were used in each microplate. Autoantibody positivity was accepted when special ELISA optical density was higher than the mean value of controls increased by two standard deviations. The patient's



**Figure 3.** Acantholysis is present in the granular layer, with basophilic acantholytic cells inside the cleft (haematoxylin and eosin, original magnification,  $\times 100$ ).

serum gave positive reactions against one epitope of Dsg3 and the epitope of Dsg1. Blood samples for indirect immunofluorescence studies demonstrated no circulating antibodies. The patient's circulating anti-epidermal antibodies were also examined by the Western blot technique to detect Dsg1 or Dsg3, but there was no positive reaction.

A diagnosis of PF was made and treatment was commenced with 50 mg/day prednisolone. This treatment resulted in only a slow remission, and we therefore combined the corticosteroid with 12.5 mg of dapsone twice a day. In a few days, there was a satisfactory fast resolution of the blistering and a rapid improvement in the condition occurred. The dose of prednisolone was subsequently tapered slowly to half the initial dose. One month was sufficient for almost complete recovery (Fig. 1b), and blood investigations returned to normal. The patient was discharged while receiving 25 mg of prednisolone every second day, and 12.5 mg of dapsone twice daily. This treatment has been tapered so that she is now receiving 12.5 mg of dapsone a day. She has had no further lesions over the last 3 years.

## Discussion

PF, a less severe variant of pemphigus, is a rare disease, especially in the first 14 years; it affects both sexes equally<sup>5,7-10</sup> Despite its rarity, however, it is more frequent in Brazil<sup>11</sup> and India.<sup>12</sup> Adult PF has been reported to be associated with other autoimmune disorders<sup>13,14</sup> and drugs,<sup>15</sup> but Graves' disease is the only condition reported to coexist with childhood PF.<sup>9</sup>

The clinical manifestations of adult and juvenile PF are similar. The onset is often slow, with crusting, yellowish, scaling lesions starting on the face and scalp, as in our case,<sup>8</sup> which can mimic impetigo and seborrhoeic dermatitis; unlike PV, the oral mucosa is rarely involved.<sup>5,7</sup> Histologically, PF is characterized by acantholysis high in the epidermis, either subcorneally or in the stratum granulosum.<sup>16</sup> These superficial changes are similar in PF and pemphigus erythematosus (PE) but, clinically, PE may simulate lupus erythematosus.<sup>17,18</sup> Our case demonstrated the typical histology of PF, with acantholysis in the upper epidermis. PF in general gives identical immunofluorescence (IF) changes to PV. Staining of the PF lesions for direct IF shows the intercellular deposition of IgG, C3 and, rarely, IgA,<sup>19</sup> as detected in our case. Serum from PF patients for indirect IF studies shows IgG staining of the keratinocyte cell surface in the upper epidermis.<sup>2</sup>

The pathogenesis of blister formation in pemphigus is related to the detection of autoantibody formation against PF antigen Dsg1 (160 kDa) and the PV antigen Dsg3 (130 kDa).<sup>20</sup> Immunoblot analysis in PF patients revealed circulating autoantibodies against Dsg1 antigen; despite its potential positivity, the reaction was negative in two-thirds of the patients.<sup>21</sup> These antigenic determinations including Dsg1 and Dsg3 are important in differentiation from other autoimmune blistering diseases such as PV<sup>2</sup> or PE, which are not usually determined in PE.<sup>18</sup> Therefore, detection of the characteristic anti-epidermal and anti-Dsg antibodies can support the diagnosis. In our case, investigation of the serum circulating antibodies using the Western blot

technique did not detect any positive reaction but, based on more recent studies with ELISA,<sup>22,23</sup> we also routinely examined the circulating anti-Dsg1 and anti-Dsg3 antibodies by means of ELISA using synthetic, antigenic peptides.<sup>24</sup> The patient's serum gave positive reactions against one epitope of Dsg3 and the epitope of Dsg1. We used these antigenic epitopes in more than 30 cases, and 68% of the sera from patients with pemphigus gave a specific reaction with these epitopes using the ELISA technique.

PF, the less severe form of pemphigus, may be treated simply with topical steroids or low-dose corticosteroids;<sup>7</sup> the more generalized form of PF has been treated with high-dose corticosteroids.<sup>9,25</sup> However, Basset *et al.*<sup>26</sup> reported satisfactory results with dapsone as initial therapy. We also achieved fast remission when we added dapsone to low-dose corticosteroids. We believe that PF is rare in childhood and has a good prognosis. As Basset *et al.*<sup>26</sup> reported, we also achieved a good result with dapsone therapy. In our case, the lesions disappeared in response to a combination of dapsone and low-dose corticosteroids.

## References

- 1 Korman N. Pemphigus. *J Am Acad Dermatol* 1988; **18**: 1219–38.
- 2 Kawana S, Hashimoto T, Nishikawa T *et al* Changes in clinical features, histological findings, and antigen profiles with development of pemphigus foliaceus from pemphigus vulgaris. *Arch Dermatol* 1994; **130**: 1534–8.
- 3 Ahmed AR, Salem M. Juvenile pemphigus. *J Am Acad Dermatol* 1983; **8**: 799–807.
- 4 Sodiafy M, Vollum D. Pemphigus vulgaris in adolescence. *Clin Exp Dermatol* 1979; **4**: 205–9.
- 5 Goodyear MH, Abrahamson LE, Harper IJ. Childhood pemphigus foliaceus. *Clin Exp Dermatol* 1991; **16**: 229–30.
- 6 Bhol K, Natarajan K, Nagarwalla N *et al* Correlation of peptide specificity and IgG subclass with pathogenic and nonpathogenic autoantibodies in pemphigus vulgaris: a model for autoimmunity. *Proc Natl Acad Sci USA* 1995; **92**: 5239–43.
- 7 Sotiriou L, Herszenon S, Jordan RE. Childhood pemphigus foliaceus: report of case. *Arch Dermatol* 1980; **116**: 679–80.
- 8 Perry HO, Brunsting LA. Pemphigus foliaceus: further observations. *Arch Dermatol* 1965; **91**: 10–23.
- 9 Levine L, Bernstein EJ, Soltani K *et al* Coexisting childhood pemphigus foliaceus and Graves' disease. *Arch Dermatol* 1982; **118**: 602–4.
- 10 Jones SK, Schwab HP, Norris DA. Childhood pemphigus foliaceus: case report and review of the literature. *Pediatr Dermatol* 1986; **3**: 459–63.
- 11 Empinotti JC, Diaz LA, Martins CR *et al* Endemic pemphigus foliaceus in Western Parana, Brazil. *Br J Dermatol* 1990; **123**: 431–7.
- 12 Wojnarowska F, Bhogal B, Black MM *et al* The immunofluorescence finding in Indian pemphigus. *Br J Dermatol* 1985; **112**: 503–8.
- 13 Imamura S, Takigawa M, Ikai K *et al* Pemphigus foliaceus, myesthenia gravis, thyoma, and red cell aplasia. *Clin Exp Dermatol* 1978; **3**: 285–91.
- 14 Falk ES. Pemphigus foliaceus in a patient with rheumatoid arthritis and Sjögren's syndrome. A case report. *Dermatologica* 1979; **158**: 348–54.
- 15 Penas FP, Buezo FG, Carvajal I *et al* d-Penicillamine-induced pemphigus foliaceus without antibodies to desmoglein-I in patient with mixed connective tissue disease. *J Am Acad Dermatol* 1997; **37**: 121–3.
- 16 Wilgram GF, Caufield JB, Madgic EB. An electron microscopic study of acantholysis and in pemphigus foliaceus: with the especial note of peculiar intracytoplasmic bodies. *J Invest Dermatol* 1964; **43**: 287–99.
- 17 Chorzelski T, Jablonska S, Blaszczyk M. Immunopathological investigations in the Senear–Usher syndrome (coexistence of pemphigus and lupus erythematosus). *Br J Dermatol* 1968; **80**: 211–17.
- 18 Lyde BC, Cox ES, Cruz DP. Pemphigus erythematosus in a five-year-old child. *J Am Acad Dermatol* 1994; **31**: 906–9.
- 19 Beutner EH, Chorzelski TP, Wilson RM *et al* IgA pemphigus foliaceus. *J Am Acad Dermatol* 1989; **20**: 89–97.
- 20 Amagai M. Adhesion molecules. I. Keratinocyte–keratinocyte interactions; cadherins and pemphigus. *J Invest Dermatol* 1995; **104**: 146–52.
- 21 Emery DJ, Diaz LA, Fairley JA *et al* Pemphigus foliaceus and pemphigus vulgaris autoantibodies react with the extracellular domain of desmoglein-1. *J Invest Dermatol* 1995; **104**: 323–8.
- 22 Hernandez C, Amagai M, Chan LS. Pemphigus foliaceus: preferential binding of IgG1 and C3 at the upper epidermis. *Br J Dermatol* 1997; **136**: 249–52.
- 23 Ishii K, Amagai M, Hall RP *et al* Characterization of autoantibodies in pemphigus using antigen-specific enzyme-linked immunosorbent assays with baculovirus-expressed recombinant desmogleins. *J Immunol* 1997; **159**: 2010–17.
- 24 Husz S, Kiss M, Marczinovits I *et al* Detection of bullous pemphigoid antibodies by means of synthetic peptides as antigenic epitopes. *Acta Microbiol Immunol Hung* 1996; **43**: 339–43.
- 25 Schroeter A, Sams WM Jr, Jordan RE. Immunofluorescence studies of pemphigus foliaceus in a child. *Arch Dermatol* 1969; **100**: 736–40.
- 26 Basset N, Gillot B, Bruno M *et al* Dapsone as initial treatment in superficial pemphigus. *Arch Dermatol* 1987; **123**: 783–5.