



# Correlations between left ventricular rotational mechanics and parasympathetic autonomic function – results from the three-dimensional speckle-tracking echocardiographic MAGYAR-Healthy Study

Attila Nemes<sup>1</sup>, Anita Kalapos<sup>1</sup>, Péter Domsik<sup>1</sup>, Andrea Orosz<sup>2</sup>, Csaba Lengyel<sup>1</sup>

<sup>1</sup>Department of Medicine, Medical Faculty, Albert Szent-Györgyi Clinical Centre, University of Szeged, Szeged, Hungary; <sup>2</sup>Department of Pharmacology and Pharmacotherapy, Medical Faculty, Albert Szent-Györgyi Clinical Centre, University of Szeged, Szeged, Hungary

*Correspondence to:* Prof. Dr. Attila Nemes MD, PhD, DSc, FESC. Department of Medicine, Medical Faculty, University of Szeged, Semeleweis street 8, P.O. Box 427, H-6725 Szeged, Hungary. Email: nemes.attila@med.u-szeged.hu.

**Abstract:** Left ventricular (LV) twist is calculated from the net difference of counterclockwise apical and clockwise basal rotation during systole. The current study was designed to evaluate correlations between autonomic function and LV rotational mechanics in healthy subjects. The present study comprised 18 healthy subjects (mean age: 36±12 years, 12 men). Three-dimensional speckle tracking echocardiography (3DSTE) could be used for non-invasive evaluation of LV rotation and twist. Autonomic function was assessed by means of 5 standard cardiovascular reflex tests. During 3DSTE, basal LV rotation proved to be  $-3.24\pm 2.02$  degree, while apical LV rotation was  $9.08\pm 3.04$  degree, therefore LV twist was  $11.70\pm 6.80$  degree. Valsalva test showed significant correlations with LV basal ( $r=0.529$ ,  $P=0.019$ ) and apical rotations ( $r=-0.534$ ,  $P=0.022$ ), and LV twist ( $r=-0.467$ ,  $P=0.044$ ). Heart rate response to deep breathing significantly correlated with LV twist, as well ( $r=-0.452$ ,  $P=0.052$ ). The other tests had no any relationship with rotational characteristics. Correlations exist between parasympathetic autonomic function and 3DSTE-derived LV rotation and twist in healthy subjects.

**Keywords:** Correlation; autonomic; speckle-tracking; three-dimensional; echocardiography; twist; rotation

Submitted Apr 07, 2020. Accepted for publication Oct 22, 2020.

doi: 10.21037/qims-20-544

View this article at: <http://dx.doi.org/10.21037/qims-20-544>

## Introduction

Left ventricular (LV) base of the healthy heart rotates clockwise, while LV apex rotates counterclockwise in systole representing a “towel-wringing” motion called as LV twist (1,2). The LV twist is the result of the movement of double, orthogonally oriented helical structure of myocardial fibers (2). Despite the fact that several physiological variables could affect LV rotational mechanics, little is known about the effect of autonomic function (1,2). Three-dimensional (3D) speckle-tracking echocardiography (3DSTE) has been introduced for non-invasive bedside

evaluation of LV rotational mechanics, and seems to be an optimal tool for clinical studies (3-5). The current study was designed to evaluate correlations between the result of Ewing’s 5 standard cardiovascular reflex tests characterizing autonomic function and 3DSTE-derived LV rotational parameters in healthy volunteers.

## Patients and methods

### *Patient population*

The present study comprised 18 healthy subjects in sinus

rhythm (mean age:  $36 \pm 12$  years, 12 men). All cases had undergone two-dimensional (2D) Doppler echocardiography, 3DSTE and the 5 cardiovascular reflex tests. None of the healthy subjects had any known symptoms, factors or disease, which could have affected our results. A study has been organized in our department for the evaluation of the usefulness, diagnostic and prognostic value of 3DSTE-derived parameters named MAGYAR-Healthy Study (Motion Analysis of the heart and Great vessels bY three-dimensionAl speckle-tRacking echocardiography in Healthy subjects) ('magyar' means 'Hungarian' in Hungarian language). The study complied with the Declaration of Helsinki. Informed consent was obtained from each subject and the study was approved by the institutional review board at the University of Szeged, Hungary.

### *Two-dimensional echocardiography*

Conventional echocardiography was performed using a Toshiba Artida™ echocardiographic system (Toshiba Medical Systems, Tochigi, Japan) attached to a PST-30SBP (1–5 MHz) phased-array transducer. Routine echocardiographic parameters were evaluated by M-mode and 2D Doppler echocardiography captured in parasternal and apical views according to the clinical guidelines (6).

### *Three-dimensional speckle-tracking echocardiography*

3DSTE studies were performed with the same Toshiba Artida™ echocardiography equipment (Toshiba, Tokyo, Japan) with a 1–4 MHz matrix phased-array PST-25SX transducer (5). Following 3D data collections within a single breath-hold from an apical window, the stored echocardiographic data were exported to a separate workstation for off-line analysis, where chamber quantification was performed using 3D Wall Motion Tracking software version 2.7 (Toshiba Medical Systems). Following definition of mitral annular edges and apex in apical two- (AP2CH) and four-chamber (AP4CH) views, endocardial border of the LV cavity was automatically detected by the software in 3D. Curves were generated by the software for quantification of 3DSTE-derived global peak apical and basal LV rotations and LV twist (*Figure 1*).

### *Autonomic function*

Autonomic function was assessed by means of 5

standard cardiovascular reflex tests (7). Mainly featuring parasympathetic function, heart rate response to deep breathing (normal value:  $\geq 15$  bpm, abnormal value:  $\leq 10$  bpm), Valsalva ratio (normal value:  $\geq 1.21$ , abnormal value:  $\leq 1.10$ ) and 30/15 ratio (normal value:  $\geq 1.03$ , abnormal value:  $\leq 1.00$ ) were determined, while sustained handgrip test (normal value:  $\leq 10$  mmHg, abnormal value:  $\geq 30$  mmHg) and systolic blood pressure response to standing (normal value:  $\geq 16$  mmHg, abnormal value:  $\leq 10$  mmHg) were used for predominantly reflecting sympathetic function (borderline values are between normal and abnormal values). The results of each of the 5 tests were scored as 0 (normal), 1 (borderline), or 2 (abnormal), and a final autonomic neuropathy score (ANS) was calculated (range, 0–10) to express the severity of the overall autonomic disorder.

### *Statistical analysis*

All data are reported as mean  $\pm$  SD. A value of  $P < 0.05$  was considered to be statistically significant. Medcalc software was used for statistical calculations (Medcalc, Mariakerke, Belgium). Numerical correlations were established by Pearson's correlation. GPower 3.1.9 Software (Heinrich-Heine Universität, Düsseldorf, Germany) was applied for power calculation: in the presence of effect size: 0.7, alpha: 0.05, power: 0.7 the minimum group size is  $n=14$ .

## **Results**

### *Results of the cardiovascular reflex tests*

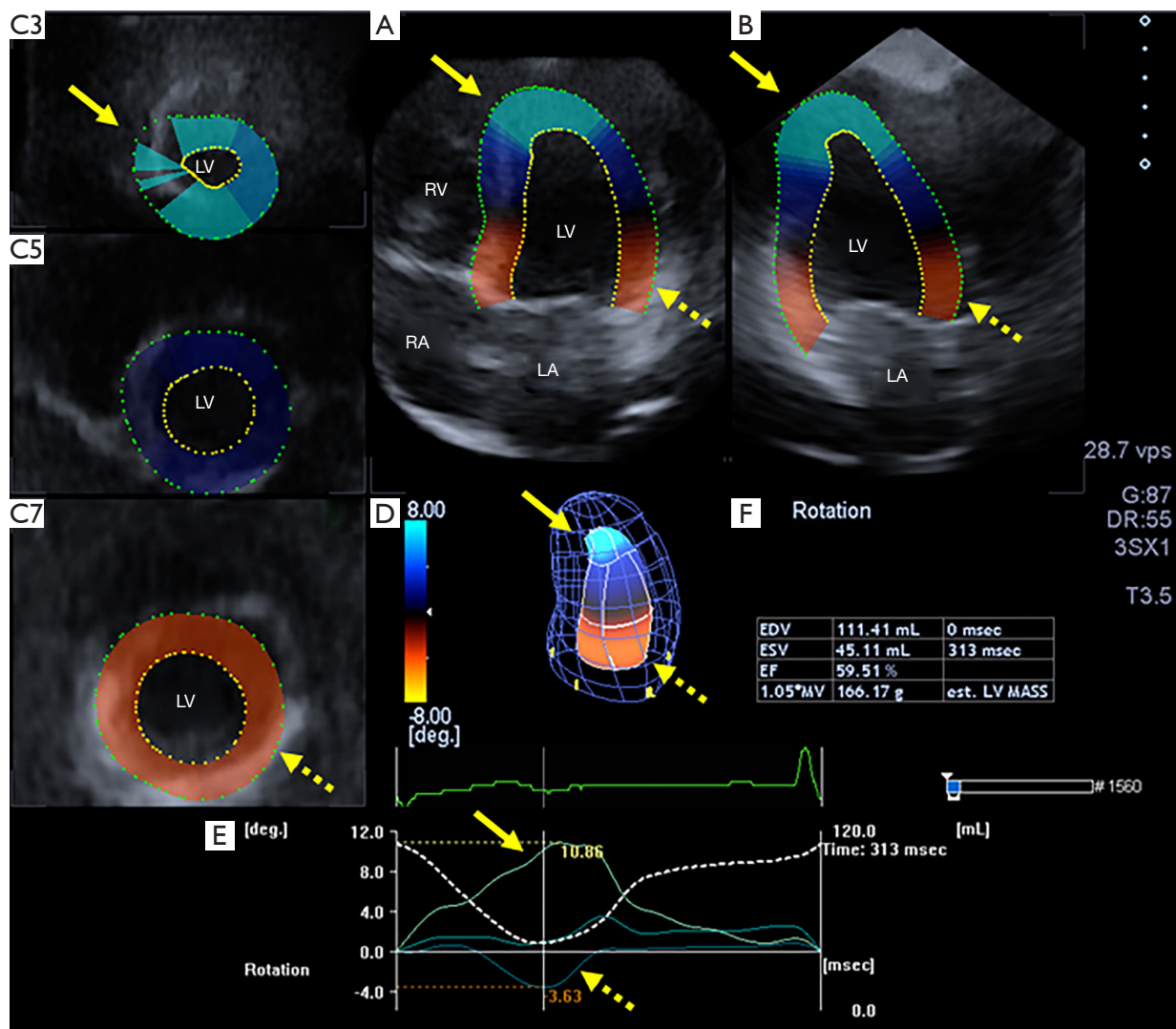
Data are presented in *Table 1*.

### *Two-dimensional and three-dimensional speckle-tracking echocardiographic data*

Routine two-dimensional echocardiographic data are presented in *Table 2*. None of the subjects have grade  $\geq 1$  valvular regurgitation or stenosis. During 3DSTE, basal LV rotation proved to be  $-3.24 \pm 2.02$  degree, while apical LV rotation was  $9.08 \pm 3.04$  degree, therefore LV twist was  $11.70 \pm 6.80$  degree.

### *Correlations between cardiovascular reflex tests and LV rotational parameters*

Valsalva test showed significant correlations with LV basal ( $r=0.529$ ,  $P=0.019$ ) and apical LV rotations ( $r=-0.534$ ,



**Figure 1** The apical four-chamber (A) and two-chamber (B) views and 3 short-axis views (C3, C5, C7) at different left ventricular levels are presented in a healthy woman. Three-dimensional cast of the LV (D) and apical, midventricular and basal regional LV rotational curves (E) are demonstrated together with LV volumetric data (F). The adequate rotational directions are counterclockwise motion of the left ventricular apex expressed with positive value (yellow arrow) and clockwise rotation of the left ventricular base expressed with negative value (dashed yellow arrow). EDV, end-diastolic volume; EF, ejection fraction, ESV, end-systolic volume; LA, left atrium; LV, left ventricle; LV MASS, LV mass; RA, right atrium; RV, right ventricle.

$P=0.022$ ), and LV twist ( $r=-0.467$ ,  $P=0.044$ ). Heart rate response to deep breathing significantly correlated with LV twist, as well ( $r=-0.452$ ,  $P=0.052$ ). The other tests did not have any relationship with LV rotational characteristics (Table 3).

## Discussion

To the best of the authors' knowledge, this is the first study

in which relationship between Ewing's cardiovascular reflex tests characterizing autonomic function and 3DSTE-derived LV rotational parameters were examined in healthy adults. Significant correlations could be demonstrated between cardiovascular reflex tests mainly characterizing parasympathetic autonomic function and LV rotational parameters in healthy volunteers.

Movement of two orthogonally oriented muscular bands

**Table 1** Blood pressure values and results of the standard cardiovascular reflex test of the healthy subjects

	Data
Systolic blood pressure (mmHg)	126.7±19.6
Diastolic blood pressure (mmHg)	74.2±11.0
Parasympathetic function	
Heart rate response to deep breathing (bpm)	22.1±8.7
Valsalva ratio	1.93±0.27
30/15 ratio	1.42±0.21
Sympathetic function	
Sustained handgrip test (mmHg)	3.68±5.93
Systolic blood pressure response to standing (mmHg)	21.9±10.2
Autonomic Neuropathy Score	0.68±1.38

**Table 2** Echocardiographic data of subjects

	Data
LA diameter (mm)	37.8±4.1
LV end-diastolic diameter (mm)	47.1±4.6
LV end-systolic diameter (mm)	29.5±4.4
LV end-diastolic volume (mL)	101.2±24.3
LV end-systolic volume (mL)	34.5±12.9
Interventricular septum (mm)	10.1±1.5
LV posterior wall (mm)	10.2±1.2
LV ejection fraction (%)	65.2±7.5
E/A	1.58±0.21

**Table 3** Pearson correlation coefficients between left ventricular rotational parameters and standard cardiovascular reflex tests in healthy volunteers

	Peak basal LV rotation	Peak apical LV rotation	Peak LV twist
Parasympathetic function			
Heart rate response to deep breathing	0.146 (P=0.550)	0.032 (P=0.901)	-0.452 (P=0.052)
Valsalva ratio	0.529 (P=0.019)	-0.534 (P=0.022)	-0.467 (P=0.044)
30/15 ratio	-0.164 (P=0.501)	0.346 (P=0.160)	-0.058 (P=0.815)
Sympathetic function			
Sustained handgrip test	0.242 (P=0.319)	-0.150 (P=0.554)	-0.303 (P=0.207)
Systolic blood pressure response to standing	0.202 (P=0.407)	0.012 (P=0.966)	0.173 (P=0.479)
Autonomic Neuropathy Score	-0.391 (P=0.098)	0.077 (P=0.763)	0.393 (P=0.096)

of a helical myocardial structure is responsible for the LV twist with consequent clockwise rotation of the LV base and counterclockwise rotation of the LV apex (4,8). LV rotational mechanics (twist) are governed by the following main factors as suggested by Nakatani (1):

- ❖ The degree of contraction and relaxation of the myocardium,
- ❖ The balance between contraction of the subendocardium and subepicardium and
- ❖ Orientation of the myocardial fibers.

Moreover, LV twist is greater with higher preload, increases with LV contractility, exercise and age, but LV twist is lower with higher afterload (2). Aortic stiffness could also have an effect on LV twisting mechanics even in healthy subjects (9). 3DSTE is a non-invasive, simple, easy-to-learn tool, which is based on tracking and measurement of tissue displacement in the 3D space respecting cardiac cycle and was found to be feasible for the assessment of LV rotational parameters (4).

Diabetic autonomic neuropathy is one of the best opportunities to examine the influence of the autonomic regulation on the LV. Sacre *et al.* highlighted the fact that global relationships of cardiac autonomic neuropathy and LV dysfunction remain independent of known factors in the pathogenesis of myocardial disease (10). Cardiac autonomic neuropathy seems to be related to altered LV filling patterns in the presence of preserved systolic function in patients with different types of diabetes mellitus (11,12). Recently, LV twist was examined in patients with diabetic cardiovascular autonomic neuropathy by two-dimensional speckle tracking imaging (13).

The main message of the present study is that relationship exists between the parasympathetic autonomic

function and the LV rotational mechanics even in healthy subjects. Result of the present study could suggest, that with increasing parasympathetic function a decrease in LV basal and apical rotations and LV twist could be detected. Moreover, no relationship was found between tests mainly characterizing sympathetic autonomic function and LV rotational parameters. However, further studies are warranted to confirm our results in a larger healthy population with other methods.

### Limitation section

- ❖ Current image quality obtained by 3DSTE is worse than for 2D echocardiography due to low temporal and spatial image resolutions (4).
- ❖ This was a single-centre experience and limited by a relatively small number of healthy volunteers. The study would have been statistically stronger, if larger number of subjects had been evaluated.
- ❖ Ewing tests can be used to examine the physiological responses to shifts in autonomic function. However, in the context of LV twist, most of these tests profoundly impact other regulators of LV mechanics and hemodynamics, including venous return and afterload.
- ❖ Moreover, the Valsalva maneuver, while being a tool to assess the baroreflex responses to the breathing, is not necessarily a test delineating sympathetic versus vagal input, and also poses the additional constraint on the heart of altered lung volumes and impedes quality echocardiographic imaging.

### Conclusions

Correlations exist between parasympathetic autonomic function and LV rotation and twist in healthy volunteers.

### Acknowledgments

*Funding:* None.

### Footnote

*Conflicts of Interest:* All authors have completed the ICMJE uniform disclosure form (available at <http://dx.doi.org/10.21037/qims-20-544>). AN serves as an unpaid editorial board member of *Quantitative Imaging in Medicine and Surgery*. The authors have no conflicts of interest to declare.

*Ethical Statement:* The study complied with the Declaration of Helsinki. Informed consent was obtained from each patient and the study was approved by the institutional review board at the University of Szeged, Hungary.

*Open Access Statement:* This is an Open Access article distributed in accordance with the Creative Commons Attribution-NonCommercial-NoDerivs 4.0 International License (CC BY-NC-ND 4.0), which permits the non-commercial replication and distribution of the article with the strict proviso that no changes or edits are made and the original work is properly cited (including links to both the formal publication through the relevant DOI and the license). See: <https://creativecommons.org/licenses/by-nc-nd/4.0/>.

### References

1. Nakatani S. Left ventricular rotation and twist: why should we learn? *J Cardiovasc Ultrasound* 2011;19:1-6.
2. Sengupta PP, Tajik AJ, Chandrasekaran K, Khadheria BK. Twist mechanics of the left ventricle: principles and application. *JACC Cardiovasc Imaging* 2008;1:366-76.
3. Ammar KA, Paterick TE, Khandheria BK, Jan MF, Kramer C, Umland MM, Tercius AJ, Baratta L, Tajik AJ. Myocardial mechanics: understanding and applying three-dimensional speckle tracking echocardiography in clinical practice. *Echocardiography* 2012;29:861-72.
4. Andrade J, Cortez LD, Campos O, Arruda AL, Pinheiro J, Vulcanis L, Shiratsuchi TS, Kalil-Filho R, Cerri GG. Left ventricular twist: comparison between two- and three-dimensional speckle-tracking echocardiography in healthy volunteers. *Eur J Echocardiogr* 2011;12:76-9.
5. Nemes A, Kalapos A, Domsik P, Forster T. Three-dimensional speckle-tracking echocardiography -- a further step in non-invasive three-dimensional cardiac imaging. *Orv Hetil* 2012;153:1570-7.
6. Lang RM, Badano LP, Mor-Avi V, Afilalo J, Armstrong A, Ernande L, Flachskampf FA, Foster E, Goldstein SA, Kuznetsova T, Lancellotti P, Muraru D, Picard MH, Rietzschel ER, Rudski L, Spencer KT, Tsang W, Voigt JU. Recommendations for cardiac chamber quantification by echocardiography in adults: an update from the American Society of Echocardiography and the European Association of Cardiovascular Imaging. *J Am Soc Echocardiogr* 2015;28:1-39.e14.
7. Ewing DJ, Martyn CN, Young RJ, Clarke BF. The value of cardiovascular autonomic function tests: 10 years experience in diabetes. *Diabetes Care* 1985;8:491-8.

8. Kocica MJ, Corno AF, Carreras-Costa F, Ballester-Rodes M, Moghbel MC, Cueva CNC, Lackovic V, Kanjuh VI, Torrent-Guasp F. The helical ventricular myocardial band: global, three-dimensional, functional architecture of the ventricular myocardium. *Eur J Cardiothorac Surg* 2006;29 Suppl 1:S21-40.
9. Nemes A, Kalapos A, Domsik P, Lengyel C, Orosz A, Forster T. Correlations between echocardiographic aortic elastic properties and left ventricular rotation and twist—insights from the three-dimensional speckle-tracking echocardiographic MAGYAR-Healthy Study. *Clin Physiol Funct Imaging* 2013;33:381-5.
10. Sacre JW, Franjic B, Jellis CL, Jenkins C, Coombes JS, Marwick TH. Association of cardiac autonomic neuropathy with subclinical myocardial dysfunction in type 2 diabetes. *JACC Cardiovasc Imaging* 2010;3:1207-15.
11. Kahn JK, Zola B, Juni JE, Vinik AI. Radionuclide assessment of left ventricular diastolic filling in diabetes mellitus with and without cardiac autonomic neuropathy. *J Am Coll Cardiol* 1986;7:1303-9.
12. Poirier P, Bogaty P, Philippon F, Garneau C, Fortin C, Dumesnil JG. Preclinical diabetic cardiomyopathy: relation of left ventricular diastolic dysfunction to cardiac autonomic neuropathy in men with uncomplicated well-controlled type 2 diabetes. *Metabolism* 2003;52:1056-61.
13. Liu XY, Dai M, Zheng J, Zhang CY, Li KL, Gao YL, Li XY, Tang YY, Qian DJ, Wang RX. Evaluation of left ventricular function and twist in patients with diabetic cardiovascular autonomic neuropathy by speckle tracking imaging. *Zhonghua Xin Xue Guan Bing Za Zhi* 2012;40:147-52.

**Cite this article as:** Nemes A, Kalapos A, Domsik P, Orosz A, Lengyel C. Correlations between left ventricular rotational mechanics and parasympathetic autonomic function—results from the three-dimensional speckle-tracking echocardiographic MAGYAR-Healthy Study. *Quant Imaging Med Surg* 2021;11(4):1613-1618. doi: 10.21037/qims-20-544