Hellenic Journal of Cardiology 59 (2018) 354–357

Contents lists available at ScienceDirect

Hellenic Journal of Cardiology

journal homepage: http://www.journals.elsevier.com/hellenic-journal-of-cardiology/

Letter to the Editor

"Around the world" – How to reach native coronary artery lesions through long and tortuous aortocoronary bypass grafts

Keywords:
Percutaneous coronary intervention
Techniques
Bypass grafts
Tortuosity

1. Introduction

Patients with prior coronary artery bypass graft surgery (CABG) often present with recurrent ischemic symptoms, which are more commonly due to the progression of atherosclerosis in the native coronary vessels and less commonly due to bypass graft failure, although the frequency of the latter is higher with increasing time post CABG.[1] CABG itself may accelerate the progression of coronary atherosclerosis and lead to development of chronic total occlusions in the native coronary arteries.

Percutaneous coronary intervention (PCI) of native coronary lesions in bypassed vessels may require treatment through the bypass grafts, which in turn can be hindered by long distance between the bypass graft origin and the target lesion, tortuosity (especially if the lesion is proximal to the graft anastomosis), and calcification. We present such a case that was successfully treated using a variety of techniques in a patient with cardiogenic shock.

2. Case report

A 69-year-old man was transferred to our institution with acute respiratory failure secondary to acute systolic heart failure in the context of septic arthritis. He had undergone CABG 18 years before with a left internal mammary artery graft (LIMA) to the left anterior descending artery (LAD) (Fig. 1, Panel A), and a Y-graft consisting of a saphenous vein graft (SVG) to the first obtuse marginal (OM1) branch and a radial graft anastomosed to the side of the SVG that supplied sequentially the right posterior descending artery (PDA) and the right posterolateral branch (Fig. 1, Panel B and C). He had undergone multiple prior PCIs to the native right coronary artery (RCA) owing to recurrent in-stent restenosis and also had inferior ST-segment elevation MI because of stent thrombosis. He subsequently developed cardiogenic shock leasing to intubation and emergent coronary angiography.

Diagnostic angiography performed using right femoral artery access revealed an occluded left main and a patent LIMA graft to the LAD that also filled the circumflex (Fig. 1, Panel A). The SVG to the OM1 was occluded at its ostium. RCA angiography showed focal in-stent restenosis of the mid-RCA (Fig. 1, arrowheads, Panel B). The radial graft filled through the right PDA, supplying the right PDA and a patent segment of the SVG-OM1 that had a severe lesion (Fig. 1, Panel B and C).

A decision was made to proceed with PCI of the SVG to the OM1 lesion through the radial graft. The RCA was engaged with a 90-cm long, 6 Fr. Judkins right (JR) 4-guide catheter. Owing to the long distance of the target lesion from the coronary ostium, a 300-cm long Fielder FC coronary guidewire (Asahi Intecc., Nagoya, Japan) was advanced to the target lesion with the support of a Micro14 microcatheter (155-cm long; Roxwood Medical, Redwood City, California, USA) (Fig. 1, Panel D). Attempts to deliver a 1.5 × 20 mm Emerge balloon (Boston Scientific, Natick, MA, USA) failed because of a poor guide catheter support. The in-stent restenotic lesion in the mid-RCA was dilated followed by the advancement of a 6 Fr. GuideLiner V3 guide catheter extension (Vascular Solutions, Minneapolis, MN, USA) to the distal RCA. A 1.5 × 20 mm Emerge balloon (Boston Scientific, Natick, MA, USA) with a shaft length of 144 cm was then successfully delivered to the target location and the lesion was predilated (Fig. 1, Panel E). A 2.5 × 28 mm Synergy drug-eluting stent (Boston Scientific, Natick, MA, USA) could not reach the target lesion because of the extreme 180° bend of the graft before the PDA anastomosis (Fig. 1, Panel F). Two shorter stents (2.5 × 12 mm Synergy stents, with a shaft length of 144 cm) were successfully delivered and deployed at the target lesion (Fig. 1, Panel G and H) and post-dilated with a 2.75 × 15 mm Emerge balloon (Boston Scientific, Natick, MA, USA) with an excellent final angiographic result (Fig. 1, Panel I). The patient was extubated the following day, and vasopressors were weaned without any further need for respiratory support or either mechanical/pharmacological hemodynamic support. After recovering from aspiration pneumonia, he was discharged home on the 14th day after the procedure.

3. Discussion

Our case illustrates challenges associated with the treatment of native coronary lesions through aortocoronary bypass grafts, such as distal location and tortuosity. Such lesions may not be easily reached with standard PCI equipment, requiring creative solutions such as short guide catheters, long coronary guidewires, long microcatheters, guide catheter extensions, long shaft and short-length balloons and stents.

Peer review under responsibility of Hellenic Society of Cardiology.

https://doi.org/10.1016/j.hjc.2017.12.002

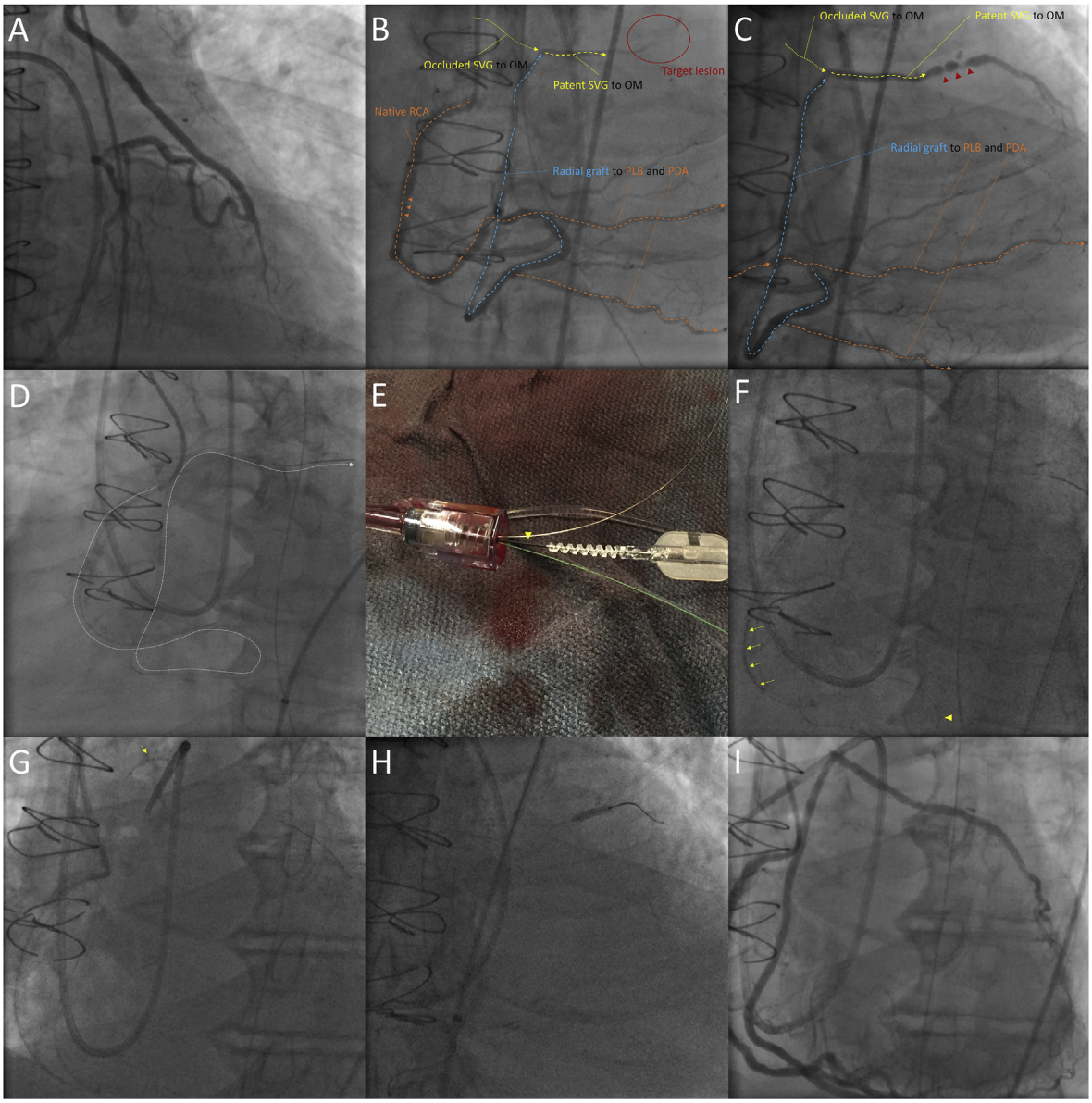

Fig. 1. Panel A: Diagnostic angiography showing patent left internal mammary artery graft to the left anterior descending artery with retrograde filling of the circumflex. **Panel B–C:** Right coronary artery angiography demonstrated patent radial graft (blue dashed arrow), occluded proximal segment of the saphenous vein graft (SVG) (yellow dotted arrow), and critical stenosis in the distal segment of the SVG (red arrows). **Panel D:** Successful lesion crossing with the Fielder FC wire through a Micro14 microcatheter. **Panel E:** The length of the balloon shaft was barely long enough to reach the lesion. **Panel F:** Failed attempts to deliver a 28-mm long stent (arrows) owing to the severe tortuosity (arrowhead). **Panel G:** Delivery of a 12-mm long stent with gentle forward maneuvers through the tortuous vessel segment (arrow). **Panel H:** Stent deployment after successful delivery to the target lesion. **Panel I:** Final angiography demonstrating TIMI 3 flow in all native and grafted segments, without any complications.

The SVG-OM1 target lesion could only be reached through a very long and tortuous pathway from the RCA ostium. Similarly, long distance to the target lesion is common for lesions distal to the internal mammary artery graft anastomosis.[2–4] A combination of techniques may be required to reach such lesions with balloons and stents. First, short guide catheters can decrease the length to the lesion: 90-cm guide catheters are commonly used for retrograde CTO PCI and are available in many laboratories. Alternatively, a standard 100-cm long guide catheter can be shortened by cutting out a segment of the catheter and connecting the remaining pieced with a sheath that is one French smaller diameter from the guide catheter (i.e., 5 Fr sheath for 6 Fr guide catheters) (https://www.youtube.com/watch?v=hrbU6w2S0Y4&feature=youtu.be). Second, the guide catheter may be deeply intubated into the target vessel, although this was not feasible in our case. Using smaller caliber (5 Fr or 6 Fr) guide catheters can facilitate intubation and reduce the risk for distal vessel injury or dissection from deep engagement of the vessel. Third, ≥300-cm long guidewires should be used because short guidewires may not be long enough. Fourth, long-shaft balloons and stents increase the likelihood of the equipment reaching the target lesion (the lengths of various stents and balloons are listed in Table 1).

Tortuosity is a frequent challenge when performing PCI through bypass grafts, hindering both wiring and equipment delivery.[5] Wiring through tortuous and angulated segments can be facilitated by using soft, polymer-jacketed guidewires (e.g., Fielder FC and Fielder XT-R, Asahi Intecc; Pilot 50, Abbott Vascular; and PT2, Boston Scientific). It can also be facilitated by advancement through a

microcatheter including angled microcatheters such as Supercross (45° to 120° tip bend) or Venture (Vascular Solutions) that has a deflectable distal tip that can be angled up to 90°. In our case, we used the Micro14 microcatheter (Roxwood Medical) that has the longest length (155 cm) of all available microcatheters.

Equipment delivery through tortuous coronary artery or bypass graft segments could be facilitated by using supportive guidewires, guide catheter extensions, meticulous lesion preparation, and use of short-length balloons and stents. One potential limitation of highly supportive guidewires is that they can cause pseudolesions, especially when advanced through highly tortuous grafts such as internal mammary artery grafts.[6] Guide catheter extensions can provide strong support, are commonly used in bypassed vessels[7-10] and were critical to achieving a successful outcome in our case. Occasionally, the length of the guide catheter extension (25 cm) may not be long enough to reach the target lesion, a challenge that can be overcome by using two guide catheter extensions, one 6 Fr inserted through an 8 Fr extension ("mother–daughter–granddaughter" technique[11]). Guide catheter extensions can, however, also cause complications such as dissection of the distal vessel and stent deformation or loss when attempting to advance them through the collar of the distal cylinder. The risk of complications with guide catheter extensions could be decreased by placing the push rod within a towel next to the Y-connector to avoid twisting of the guidewire around the rod.

Excellent lesion preparation is critical for successful equipment delivery though highly tortuous segments and can be achieved by lesion predilation with a 1:1 sized balloons or atherectomy, although the latter is usually avoided as it may carry increased risk when performed through highly tortuous vessels. Shorter balloons and stents are more deliverable than longer ones, as seen in our case, in which two shorter stents (12 mm each) could reach the target lesion, whereas delivery of a longer stent (28 mm) failed.

Table 1
Shaft length of the currently available balloons and stents in the United States.

Balloon shaft length (cm)		Stent shaft length (cm)	
Boston scientific		**Boston scientific**	
Emerge (MR/OTW)	144	Promus RX/OTW	143/143
Apex (MR/OTW)	142	Promus Premier	144
Maverick (OTW)	142	Synergy	144
Maverick 2 (MR)	142	Taxus Liberte MR/OTW	144/138
Maverick XL	152		
Quantum Maverick (MR/OTW)	140/135		
NC Emerge (MR/OTW)	143		
NC Quantum Apex (MR/OTW)	143/142		
Medtronic		**Medtronic**	
Euphora	142	Endeavor RX/OTW	135/135
NC Euphora	142	Integrity Resolute	140
Sprinter Legend RX/OTW	142/152		
NC Sprinter RX	142		
NC Stormer OTW	138		
Sprinter OTW	138		
Abott		**Abott**	
Mini Trek RX/OTW	145	XienceV RX/OTW	143/143
NC Trek RX/OTW	143	Xience Prime	143
Trek RX/OTW	143/145	Xience Alpine	145
		Xience Xpedition	145
		Absorb	145
Angioscore			
Angiosculpt (RX/OTW)	137-139		
Trireme medical inc.			
Glider	135		

MR, monorail; OTW, over-the-wire; RX, rapid exchange.

Reaching distal lesions with balloons or stents depends on their shaft length, which ranges between 135 and 145 cm for the currently available equipment in the United States (Table 1). The longest rapid exchange systems are the Emerge (Boston Scientific, 144 cm long) and the Mini Trek (Abbott Vascular, 145 cm long). There are over-the-wire balloons with a longer shaft length, such as the Sprinter Legend, Medtronic, 152 cm long, but they are only available in ≤2.0 mm diameters. Regarding stents, the Xience Xpedition (Abbott Vascular 145 cm) and the Synergy and Promus (Boston Scientific, 144 cm) have the longest shaft lengths.

Despite use of the aforementioned techniques, treating lesions distal to bypass graft anastomoses may occasionally fail or lead to complications such as dissection or stent loss. An alternative treatment strategy in such cases is recanalization of the occluded native coronary artery,[12] which, however, can also be technically challenging and often requires expertise with CTO PCI techniques and availability of dedicated equipment.

4. Conclusion

Treatment of native coronary artery lesions distal to bypass graft anastomoses may be hindered by long distance to the lesion and severe tortuosity, but such obstacles can often be overcome by using a variety of techniques and equipment to achieve successful revascularization.

References

1. Brilakis ES, Rao SV, Banerjee S, et al. Percutaneous coronary intervention in native arteries versus bypass grafts in prior coronary artery bypass grafting patients a report from the national cardiovascular data registry. *JACC Cardiovasc Interv*. 2011;4(8):844–850.
2. Meucci F, Stolcova M, Valoti P. Primary PCI in a patient with acute occlusion of native LAD beyond the LIMA graft anastomosis: first reported case, technical challenges and review of the literature. *Cardiovasc Interv Ther*. 2015;30(3):303–306.
3. Hari P, Kirtane AJ, Bangalore S. Retrograde approach to an ostial left anterior descending chronic total occlusion through a left internal mammary artery graft. *Catheter Cardiovasc Interv*. 2016;87(6):E224–E228.
4. Dato I, Porto I, Camaioni C, Crea F. Left anterior descending artery percutaneous coronary intervention from the right radial access via the left internal mammary artery: a case report. *Cardiovasc Revasc Med*. 2011;12(6):412–416.
5. Saeed B, Banerjee S, Brilakis ES. Percutaneous coronary intervention in tortuous coronary arteries: associated complications and strategies to improve success. *J Interv Cardiol*. 2008;21(6):504–511.
6. Zanchetta M, Pedon L, Rigatelli G, Olivari Z, Zennaro M, Maiolino P. Pseudo-Lesion of Internal Mammary Artery Graft and Left Anterior Descending Artery During Percutaneous Transluminal Angioplasty: A Case Report. *Angiology*. 2004;55(4):459–462.
7. Repanas TI, Christopoulos G, Brilakis ES. "Candy cane" guide catheter extension for stent delivery. *J Invasive Cardiol*. 2015;27(8):E169–E170.
8. Hanna EB, Dasari TW, Hennebry TA. Use of the GuideLiner catheter for the treatment of a bifurcational total occlusion of the native left anterior descending artery through a tortuous composite venous graft. *J Invasive Cardiol*. 2011;23(3):E40–E42.
9. Park CI, Noble S, Bonvini RF. GuideLiner microcatheter to improve back-up support during a complex coronary stenting procedure through a tortuous left internal mammary graft. *J Invasive Cardiol*. 2012;24(4):E77–E79.
10. Luna M, Papayannis A, Holper EM, Banerjee S, Brilakis ES. Transfemoral use of the GuideLiner catheter in complex coronary and bypass graft interventions. *Catheter Cardiovasc Interv*. 2012;80(3):437–446.
11. Finn MT, Green P, Nicholson W, et al. Mother-daughter-granddaughter double GuideLiner technique for delivering stents past multiple extreme angulations. *Circ Cardiovasc Interv*. 2016;9(8).
12. Brilakis ES, Banerjee S, Lombardi WL. Retrograde recanalization of native coronary artery chronic occlusions via acutely occluded vein grafts. *Catheter Cardiovasc Interv*. 2010;75(1):109–113.

Peter Tajti
Minneapolis Heart Institute, Abbott Northwestern Hospital, Minneapolis, MN, USA

Division of Invasive Cardiology, Second Department of Internal Medicine and Cardiology Center, University of Szeged, Hungary

Yader Sandoval
Minneapolis Heart Institute, Abbott Northwestern Hospital, Minneapolis, MN, USA

Division of Cardiology, Department of Medicine, Hennepin County Medical Center, Minneapolis, MN, USA

Emmanouil S. Brilakis*
Minneapolis Heart Institute, Abbott Northwestern Hospital, Minneapolis, MN, USA

* Corresponding author. Emmanouil S. Brilakis, Minneapolis Heart Institute, 920 E 28th Street #300, Minneapolis, MN 55407, USA. Tel.: +1 612 863 3900.
E-mail address: esbrilakis@gmail.com (E.S. Brilakis).

28 November 2017
Available online 3 January 2018