

The First Reported Case of Trichothiodystrophy in Hungary: A Young Male Patient with Mutations in the *ERCC2* Gene

Klara Veres¹, Nikolett Nagy², Béla Háromszéki¹, Ágnes Solymosi¹, Viktoria Vass³, Márta Széll², Zsuzsanna Zsófia Szalai¹

¹Department of Pediatric Dermatology of Heim Pál Children's Hospital, Budapest, Hungary; ²University of Szeged Department of Medical Genetics, Szeged, Hungary; ³Department of Pathology of Heim Pál Children's Hospital, Budapest, Hungary

Corresponding author:

Klara Veres, MD
Department of Pediatric Dermatology of
Heim Pál Children's Hospital
Üllői u. 86
1089 Budapest
Hungary
klarii@yahoo.com

Received: November 14, 2016

Accepted: May 15, 2018

ABSTRACT Trichothiodystrophy, also called sulphur-deficient brittle hair syndrome, is a rare autosomal recessive genetic disorder of DNA repair and transcription. Trichothiodystrophy is characterised by dry, thin, easily broken hair, showing alternating light and dark pattern called 'tiger tail' banding under polarizing light microscopy. According to our knowledge, our report is the first one on this rare disorder from Hungary: a case of a 9-year-old boy showing clinical features typical of trichothiodystrophy. Sequence analysis of the *ERCC2* gene identified two recurrent trichothiodystrophy missense heterozygous mutations – c.934G/A p.Asp312Asn (CM015299) and c.2251A/C p.Lys751Gln (CM004814) – suggesting compound heterozygous state of the patient and confirming the clinically suspected diagnosis of trichothiodystrophy.

KEY WORDS: hair disorders, genetic diseases/mechanisms, photosensitivity

INTRODUCTION

Trichothiodystrophy (TTD), also called sulphur-deficient brittle hair syndrome, is a rare autosomal recessive genetic disorder of DNA repair and transcription. TTD develops as the consequence of mutations in the excision repair complementing defective in Chinese hamster 2 (*ERCC2*) gene. In the USA and in Western Europe, the prevalence of trichothiodystrophy is 1-1.2 per million (1,2).

The first cases were reported by Tay in 1971 (3), described as nonbullous ichthyosiform erythroderma, premature aging, growth and mental retardation. The hair of the patients was short, sparse, lustered, microscopically showing pili torti and trichorrhexis

nodosa (3). The term trichothiodystrophy for sulphur-deficient hair was introduced in 1980 by Pierce at al (4). The name trichothiodystrophy originates from the Greek language: *tricho* – hair, *thio* – sulfur, *dys* – faulty, and *trophe* – nourishment (1,5).

Trichothiodystrophy is characterised by brittle, dry, sparse hair due to the lack of sulphur of the hair (5,6). Under light and electron microscopy trichoschisis, trichorrhexis nodosa-like fractures, irregular hair surface and diameter, absence of cuticle can be seen (5,7). Under polarizing microscopy, alternating light and dark banding pattern, called 'tiger tail' banding, is characteristic of this syndrome (7,8). Although in

mild cases only the hair is involved, in more severe cases there is a wide variety of clinical features, including delayed development, significant intellectual disability, microcephaly, cranial dysplasia, abnormal facial structures, protruding ears, dental abnormalities, growth retardation with short stature, premature aging, infertility and recurrent respiratory infections (1,5,6,8,9). Already the intrauterine development can be complicated by preeclampsia or HELLP syndrome. Premature birth, low birth weight and slow growth are common findings (10). Patients suffering from the disease are highly social – they have an outgoing, engaging personality (10). Cutaneous manifestations can be ichthyosis, eczema, follicular keratosis, cheilitis, telangiectasia, hypohidrosis, photosensitivity, freckles or atopic dermatitis (9). Collodion baby manifestation is also possible (1). Nails are often dystrophic with koilonychia, ridging, lamellar splitting and spotted leukonychia. Ocular lesions like cataract, conjunctivitis, nystagmus, photophobia, retinal dystrophy and ectropion can be also present. Severely affected individuals, depending especially on the neurological manifestations and immune deficiency, have reduced life expectancy (1).

CASE REPORT

A 9-year-old boy was presented at the Department of Dermatology of the Heim Pál Children's Hospital, with sparse, brittle hair and extremely dry skin (Figure 1-2.). He was born at term as the first child of non-consanguineous parents with the birth weight

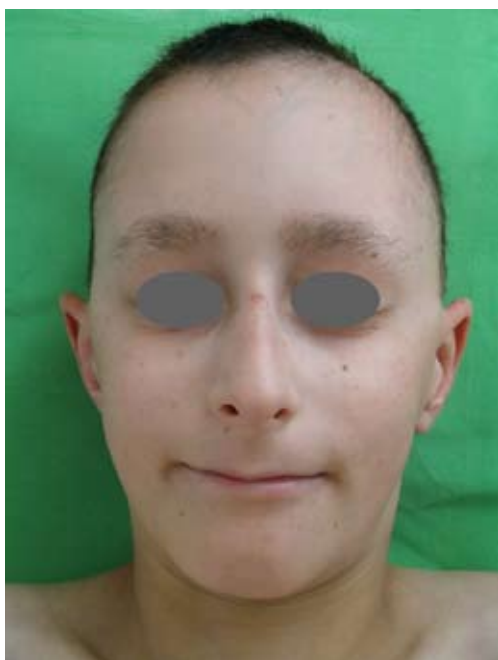

Figure 1. Long face, sparse, brittle, dry hair, sparse eyebrows, and dry skin.

of 2000 grams and with vacuum extraction because of poor maternal pushing. His APGAR scores were 3/5/7, his status was stabilized after manual ventilation, but he was put in incubator and oxygen cabin for a short time.

His motoric development was appropriate, but he had mild mental retardation and minimal microcephaly.

His medical history included varicella, inguinal hernia, penicillin and milk allergies. His family history was positive for diabetes, hypertonia, and rheumatoid arthritis. The appearance and consistency of his mother's and grandmother's hair were similar to his hair.

Repeated ultrasound examination of the head and neurological examination did not find any additional alterations. Cognitive delays were observed; his IQ level was between 78 and 82. The diagnosis of hyperkinetic conduct disorder was established by psychological examination. He was controlled by cardiologists because he had ASD II and mild pulmonary valve stenosis. He was under orthopaedic care because of scoliosis. X-ray examinations demonstrated normal bone age. No evidence of other bone alterations was observed. Ophthalmologic examination revealed severe hypermetropia, amblyopia. He complained of photosensitivity. His sweating was normal.

Physical examination revealed a prematurely aged appearance, with asthenic body type. His percentile for weight was between 3rd and 10th and under the 3rd percentile for height. He had a long face, frontal bossing, high arched palate and carious teeth. His skin was extremely dry and lichenification was present over the knees. The hair was sparse and brittle, with sparse eyebrows (Figure 1, Figure 2). Under polarizing light microscopy, the hair shaft exhibited dark and light banding in a 'tiger tail' pattern (Figure 3). The nails were not affected.

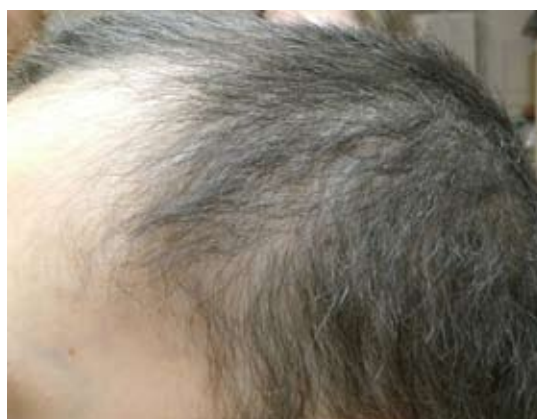

Figure 2. Easily broken, dry, sparse hair.




Figure 3. Polarizing microscopy showed alternating light and dark regions, called 'tiger tail' banding.

Full blood count, electrolytes, renal and liver function, TSH, rheumatoid factor and serum immunoglobulin were within the normal ranges.

The clinical features and hair microscopy findings were consistent with the diagnosis of TTD, therefore molecular genetic investigations were performed. Direct sequencing of the coding regions and the flanking introns of the *ERCC2* gene revealed two recurrent missense heterozygous mutations – c.934G/A p.Asp312Asn (CM015299) and c.2251A/C p.Lys751Gln (CM004814) – suggesting compound heterozygous state of the patient and confirming the clinically suspected diagnosis of trichothiodystrophy (Figure 4, Figure 5).

He is followed up closely by a multidisciplinary team including dermatologists, neurologists, psychologists, cardiologists, orthopaedists and ophthalmologist.

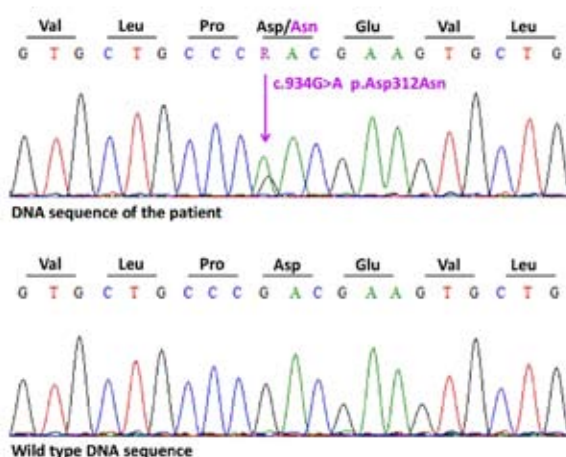


Figure 4. Sequence analysis of the *ERCC2* gene: novel missense heterozygous mutation (c.934G/A p.Asp312Asn (CM015299)) in the tenth exon (see arrow).

DISCUSSION

TTD is characterized by sparse, dry and easily broken, brittle hair due to lack of sulphur of the hair (1,5,11). Sulphur is an element that normally gives the strength of the hair (9). Light microscopy of hair shaft might reveal trichoschisis, trichorrhaxis nodosa or absence of cuticle. Under polarizing microscopy, the typical appearance of alternating light and dark bands called "tiger tail" pattern is seen, which is characteristic for the syndrome. Amino acid analysis is a useful diagnostic method of TTD due to quantifying sulfur (specifically cystein), which correlates inversely with the percentage of affected hairshafts (2).

According to the presence of variant clinical symptoms like photosensitivity, ichthyosis, brittle hair and nails, intellectual impairment, decreased fertility and short stature, PIBIDS, IBIDS, BIDS are distinguished from each other.

Depending on the presence or absence of clinical and cellular photosensitivity, TTD is divided into two major groups: photosensitive (TTD1-3) and nonphotosensitive (TTD4 or TTDN1) forms (5,9).

In the photosensitive form, in most cases the xeroderma pigmentosum complementation group D (*XPD*) gene, rarely the xeroderma pigmentosum complementation group B (*XPB*) and TTD complementation group A (*TTD-A*) genes are affected (2). The encoded proteins of *XPD*, *XPB* and *TTD-A* are parts of the TFIIH transcription factor, a multi-subunit protein complex, playing important role in transcription initiation, cell cycle regulation and DNA repair (1,5,6,8,9,12). In DNA repair, a part of the DNA nucleotide excision repair (NER), a multi-step pathway,

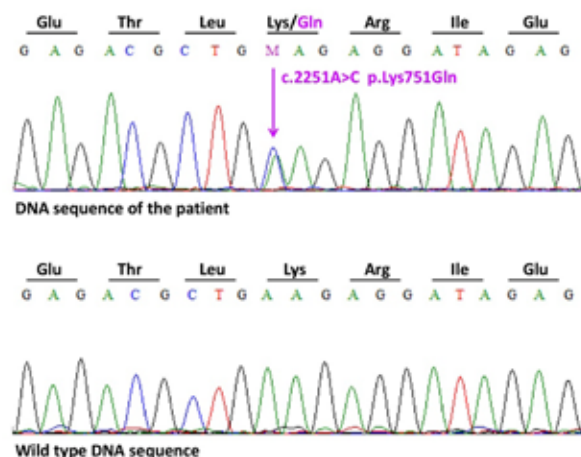


Figure 5. Sequence analysis of the *ERCC2* gene: novel missense heterozygous mutation (c.2251A/C p.Lys751Gln (CM004814)) in the twenty-third exon (see arrow).

TFIIH has at least two major functions: transcription-coupled DNA repair, which removes lesions only in the actively transcribed DNA, and the global genome repair, which removes lesions in any sequence of the genome (2,11,12). The TFIIH complex consists of two modules: core and CAK (CDK-activating kinase). The core consists of XPB, which has predominantly ATPase activity, TTD-A and 4 other subunits (2,11,12). The core and CAK sub-complexes are bridged by XPD, which has predominantly helicase activity (1,12).

The TFIIH subunit XPD is encoded by *ERCC2*, XPB is encoded by *ERCC3* and TTD-A is encoded by *GTF2H5* (general transcription factor IIH polypeptide 5). *ERCC2* variants cause TTD1, cerebrofacioskeletal syndrome, and xeroderma pigmentosum group D (6,9). *ERCC3* variants cause TTD2 and xeroderma pigmentosum group B (6,9). Mutations in the *GTF2H5* gene can result in TTD3 (9). Although the same genes are affected in Xeroderma pigmentosum (XP) and TTD, in TTD no predisposition to malignant lesions has been reported (6,10). In XP, mutations primarily affect DNA repair, whereas in TTD transcriptional alterations, in addition to impaired nucleotide excision repair (NER), is dominant (2,6).

The nonphotosensitive TTD form is said to be caused by mutations in the *MPLKIP (C7orf11)* gene, which is also called *TTDN1*. Products of these genes can play a role in cell cycle events like mitotic entry, centrosome maturation and separation, spindle pole integrity, kinetochore attachment, and cytokinesis, but the exact pathogenesis still remains unknown (6,9).

The diagnosis of TTD is established by typical clinical features, the 'tiger tail' pattern of the hair shaft under polarizing light microscopy and molecular investigation. The syndrome should be differentiated from ectodermal dysplasias, Sjögren Larsson, Menkes and Netherton syndromes, based on the sulphur content, 'tiger tail' pattern of the hair and trichoschisis.

In the presented case, molecular investigation identified two novel missense mutations in the tenth (c.934G/A p.Asp312Asn; CM015299) and twenty-third (c.2251A/C p.Lys751Gln; CM004814) exons of the *ERCC2* gene, which supported the clinical diagnosis of photosensitive TTD.

CONCLUSION

Until now there is no known curative treatment for the syndrome. Photo protection, prevention of pulmonary infections, skin rehydration, physiotherapy and other symptomatic treatment methods are important to improve the patient's lifetime and quality of life.

References:

1. Stefanini M, Botta E, Lanzafame M, Orioli D. Trichothiodystrophy: from basic mechanisms to clinical implications. *DNA Repair (Amst)*. 2010;9:2-10.
2. Hashimoto S, Egly JM. Trichothiodystrophy view from the molecular basis of DNA repair/transcription factor TFIIH. *Hum Mol Genet*. 2009;18:224-30.
3. Tay CH. Ichthyosiform erythroderma, hair shaft abnormalities, and mental and growth retardation: a new recessive disorder. *Arch Derm*. 1971;104:4-13.
4. Price VH, Odom RB, Ward WH, Jones FT. Trichothiodystrophy: sulfur-deficient brittle hair as a marker for a neuroectodermal symptom complex. *Arch Derm*. 1980;116:1375-84.
5. Itin PH, Sarasin A, Pittelkow MR. Trichothiodystrophy: update on the sulfur-deficient brittle hair syndromes. *J Am Acad Dermatol*. 2001;44:891-920.
6. Moriwaki S, Saruwatari H, Kanzaki T. Trichothiodystrophy group A: a first Japanese patient with a novel homozygous nonsense mutation in the *GTF2H5* gene. *J Dermatol*. 2014;41:705-8.
7. Shao L, Newell B. Light Microscopic Hair Abnormalities in Children: Retrospective Review of 119 Cases in a 10-Year Period. *Ped and Develop Path*. 2014;17:36-43.
8. Oon HH, Sze Chan AW, Lee JS, Leow YH, Giam YC, Leow YH, *et al*. Trichothiodystrophy in a Child with Occult Learning Disorder. *Int J Trichol*. 2013;5:35-7.
9. Shah K, Ali RH, Ansar M. Mitral regurgitation as a phenotypic manifestation of nonphotosensitive trichothiodystrophy due to a splice variant in *MPLKIP*. *BMC Med Genet*. 2016;17:13.
10. Kuschal C, Botta E, Orioli D. *GTF2E2* Mutations Destabilize the General Transcription Factor Complex TFIIH in Individuals with DNA Repair-Proficient Trichothiodystrophy. *Am J Hum Genet*. 2016;98:627-42.
11. Egly JM, Coin F. A history of TFIIH: two decades of molecular biology on a pivotal transcription/repair factor. *DNA Repair (Amst)*. 2011;11:714-21.
12. Singh A, Compe E, Le May N, Egly JM. TFIIH subunit alterations causing xeroderma pigmentosum and trichothiodystrophy specifically disturb several steps during transcription. *Am J Hum Genet*. 2015;96:194.